



PATIENT PRESENTING CLINICAL SIGNS

Delilah Floerchinger Hx of chronic ear infection, severe & constant head tilt - possible abnormality of R tympanic membrane

COMPUTED TOMOGRAPHY OF THE SKULL

SPECIES A high resolution plain CT study of the skull is provided for review.

Canine **COMPUTED TOMOGRAPHIC FINDINGS**

A supernumerary triadan 102 is seen. Triadan 305, 311, 405 and 411 are absent.

BREED The nasal cavity presents the expected aerated spaces between thin & even conchae and turbinates with smooth mucosal lining.

French Bulldog Both temporomandibular joints present congruent joint spaces with even subchondral bone surfaces and are considered within normal limits.

SEX Both tympanic bullae are filled with soft tissue attenuating material. The wall of the right tympanic bulla is moderately thickened and mildly irregular. The osseous labyrinth of the right inner ear presents signs of osseous remodeling and moth eaten osteolysis. The medial segment of the horizontal part of the external ear canals is narrowed. The external ear canals are within normal limits.

Female

AGE The submandibular and medial retropharyngeal lymph nodes are small and elongated with a normal short-to-long-axis-ratio is < 0.5, the attenuation pattern is uniform.

2 Years

COMPUTED TOMOGRAPHIC DIAGNOSIS

INTERPRETED BY

Sebastian Schaub, DVM
Dr. med. vet. DipECVDI

- Bilateral chronic otitis media, R>L
- Right sided otitis interna
- Bilateral stenotic horizontal segment external ear canals
- Supernumerary triadan 102
- Absent triadan 305, 311, 405 and 411

HOSPITAL NAME

Scottsdale Veterinary
Clinic

INTERPRETATION OF THE FINDINGS & FURTHER RECOMMENDATIONS

The right sided chronic otitis media with secondary otitis interna is a plausible explanation for the described head tilt. Surgical management of the right sided otitis media by ventral bulla osteotomy might be considered – be aware of the marked thickened wall of the tympanic bulla.

REFERRING VET

Dr. Gans

INVOICE

57537

DATE

3-29-23



PATIENT

Delilah Floerchinger

SPECIES

Canine

BREED

French Bulldog

SEX

Female

AGE

2 Years

INTERPRETED BY

Sebastian Schaub, DVM
Dr. med. vet. DipECVDI

HOSPITAL NAME

Scottsdale Veterinary
Clinic

REFERRING VET

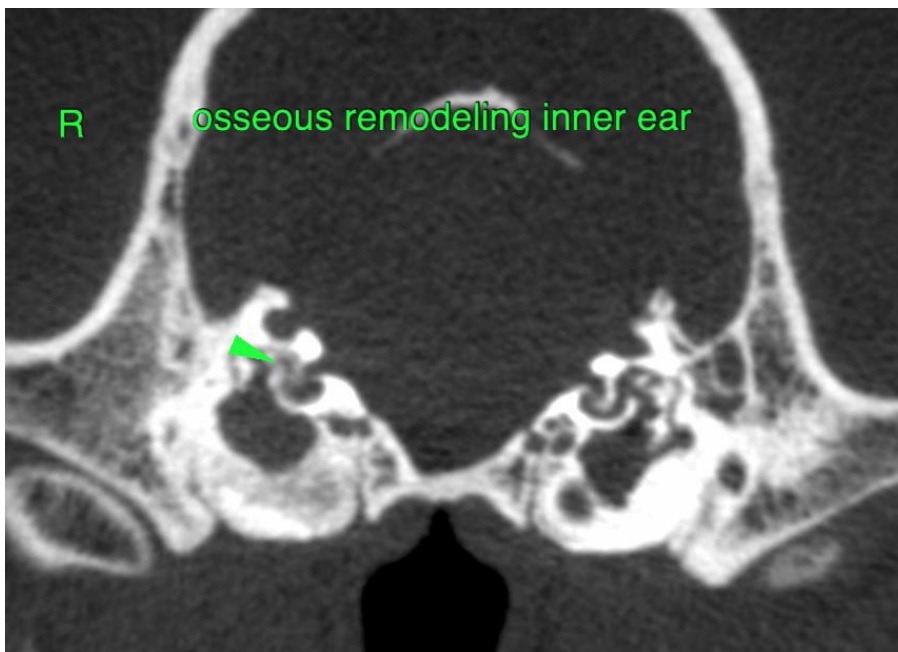
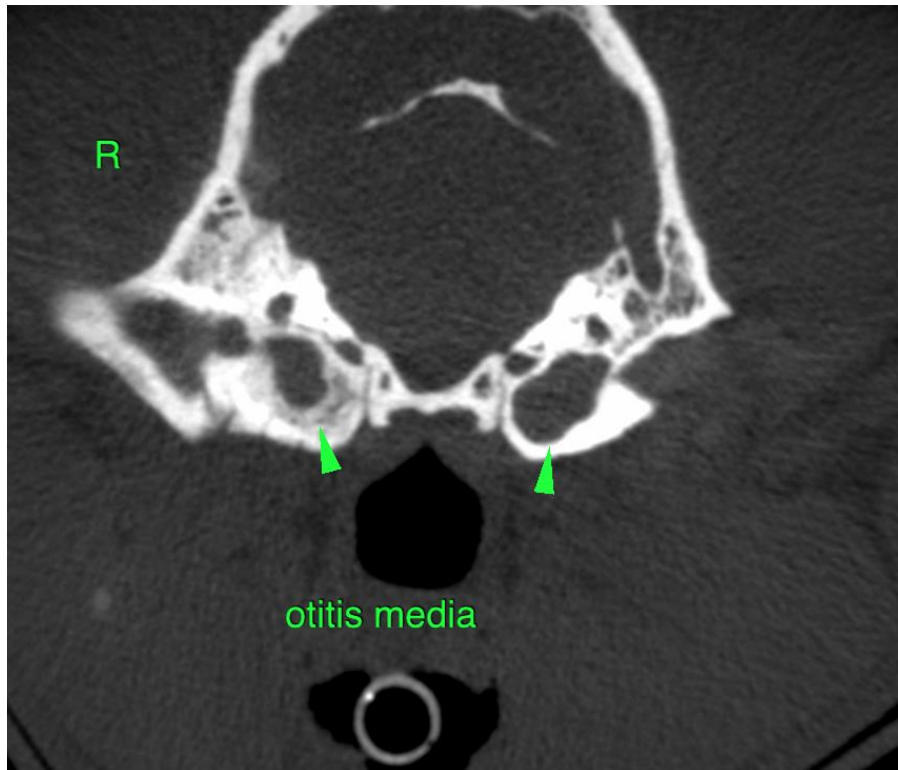
Dr. Gans

INVOICE

57537

DATE

3-29-23





PATIENT

Delilah Floerchinger

The information and recommendations provided are based on the images presented by the referring veterinarian/sonographer. No evaluation can be communicated regarding pathology that was not visible in the image/video clips provided.

SPECIES

Canine

Thank you for this referral. If the clinical or image interpretation does not parallel your findings or if I can be of any further assistance please contact me.

BREED

French Bulldog

Sebastian Schaub, Sebastian Schaub, DVM, Dr. med. vet. DipECVDI
sebast.schaub@gmail.com

SEX

Female

AGE

2 Years

INTERPRETED BY

Sebastian Schaub, DVM
Dr. med. vet. DipECVDI

HOSPITAL NAME

Scottsdale Veterinary
Clinic

REFERRING VET

Dr. Gans

INVOICE

57537

DATE

3-29-23