



PATIENT PRESENTING CLINICAL SIGNS

Daisy Cook vomiting for a couple of days, not passing any stool that o has seen. Vomiting up both food and water. Took away water yesterday and this am reintroduced water w/small amount of chicken and rice and p vomited both. Per o could have got into anything.

SPECIES Abnormal PE/Chem/CBC/UA Results: tpr - wnl, rectal - no stool in rectum

Canine **RADIOGRAPHIC STUDY OF THE ABDOMEN**

Radiographs of the abdomen in three imaging planes are provided for review.

BREED RADIOGRAPHIC FINDINGS

Golden Retriever The surrounding bony structures are within normal limits.

No abnormalities of the extraabdominal soft tissues are noted. The abdominal wall is smooth and thin.

SEX The serosal detail is maintained throughout the peritoneal and retroperitoneal space.

Spayed Female The liver is appropriate in position, size and presents uniform opacity.

The splenic head is in the anticipated position and within normal limits for size and opacity. The splenic body and tail are considered normal for position, size, shape and opacity.

AGE

4 Years Both kidneys are seen and present with normal size, shape, delineation and opacity. The urinary bladder is in its anticipated position. No radiopaque calculi are noted throughout the upper and lower urinary tract.

INTERPRETED BY

The stomach is in its anticipated position and contains a small amount of gas and fluid.

Sebastian Schaub, DVM
Dr. med. vet. DipECVDI

The small intestinal loops are of even diameter and non-dilated, a small amount of gas is seen within the small intestinal loops and considered within normal limits.

HOSPITAL NAME

The colon is seen in the expected position and empty, but a small amount of gas.

The Pet Hospital of
Stratford

RADIOGRAPHIC DIAGNOSIS

- Empty gastrointestinal tract

REFERRING VET

INTERPRETATION OF THE FINDINGS & FURTHER RECOMMENDATIONS

Dr. Claudia Giuliani

The radiographic study presents an overall empty gastrointestinal tract. There is no evidence of radiopaque foreign material, abnormal gas pattern or signs for gastrointestinal mechanical obstruction. If clinical signs are refractory to therapy, recommend follow up radiographs or a complete abdominal ultrasound examination; in some cases a high ileus may lack classical radiographic signs of mechanical obstruction.

INVOICE

57529

DATE

3-29-23



PATIENT

Daisy Cook

SPECIES

Canine

BREED

Golden Retriever

SEX

Spayed Female

AGE

4 Years

INTERPRETED BY

Sebastian Schaub, DVM
Dr. med. vet. DipECVDI

HOSPITAL NAME

The Pet Hospital of
Stratford

REFERRING VET

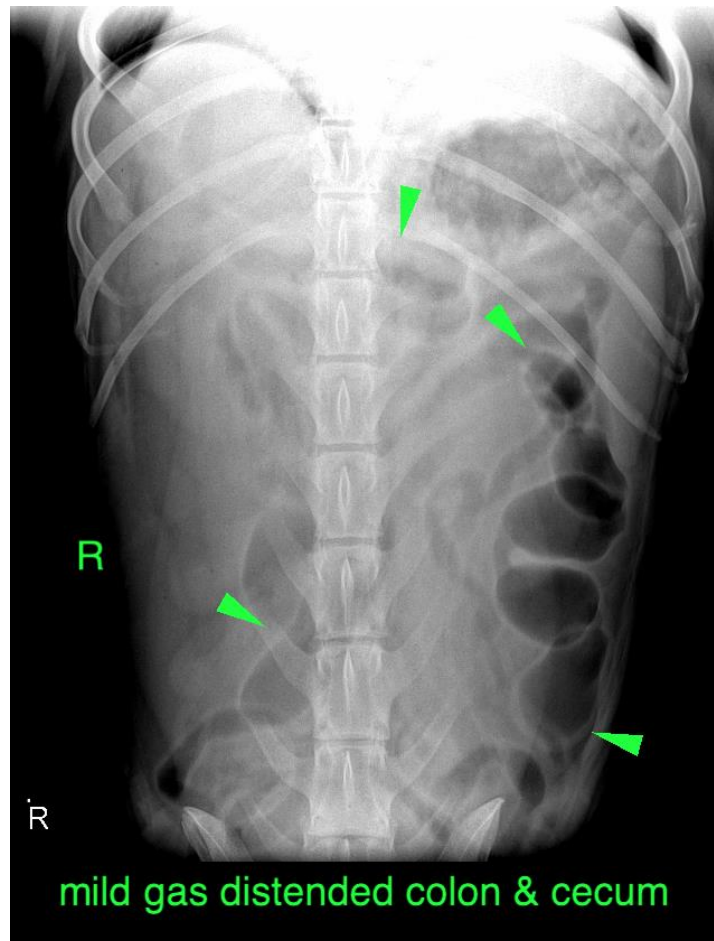
Dr. Claudia Giuliani

INVOICE

57529

DATE

3-29-23



The information and recommendations provided are based on the images presented by the referring veterinarian/sonographer. No evaluation can be communicated regarding pathology that was not visible in the image/video clips provided.

Thank you for this referral. If the clinical or image interpretation does not parallel your findings or if I can be of any further assistance please contact me.

Sebastian Schaub, Sebastian Schaub, DVM, Dr. med. vet. DipECVDI
sebast.schaub@gmail.com