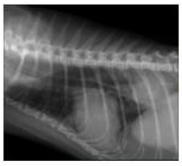
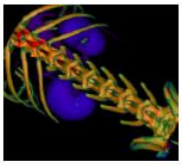
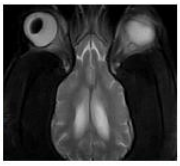

PATIENT

Jaz Bechtel

SPECIES

Canine

BREED

Cur

SEX

FS

AGE

13 Years

INTERPRETED BY

Sebastian Schaub, DVM
Dr. med. vet. DipECVDI

HOSPITAL NAME

Mobile Pet Imaging
CFL

REFERRING VET

Borecky

INVOICE

51225

DATE

3-29-22

PRESENTING CLINICAL SIGNS

Pet presented for Skull and Thoracic CT Scan. History of mass obstructing ear canal AS. Cytology consistent with epithelial population. Unable to determine if malignant.

COMPUTED TOMOGRAPHY OF THE SKULL & THORAX

A high resolution pre- and post-contrast CT study of the skull and a post-contrast CT study of the thorax are provided for review.

COMPUTED TOMOGRAPHIC FINDINGS

Skull

Multiple teeth are absent. Triadan 108 presents a moderate widening of the periodontal space.

The nasal cavity presents the expected aerated spaces between thin & even conchae and turbinates with smooth mucosal lining.

Both temporomandibular joints present congruent joint spaces with even subchondral bone surfaces and are considered within normal limits.

Both tympanic bullae are aerated, the mucosal lining is not seen, the bony wall is smooth and thin. The external ear canals are within normal limits. Level with the external opening of the left external ear canal, a roundish soft tissue attenuating mass – with central mild granular mineralization – is visible; measuring 2.2 cm in size. Post contrast administration the mass level with the external opening of the left external ear is heterogeneous contrast enhancing.

The brain presents no deviation from normal anatomy and symmetry. The brain parenchyma is homogeneous and within normal limits for attenuation and distribution of contrast enhancement. The ventricular system is non-dilated and symmetric.

The submandibular and medial retropharyngeal lymph nodes are small and elongated with a normal short-to-long-axis-ratio is < 0.5, the attenuation and contrast enhancement pattern is uniform.

Thorax

The bony and surrounding soft tissue structures are within normal limits.

The sternal, cranial mediastinal and tracheobronchial lymph nodes are small elongated with a normal short-to-long-axis-ratio is < 0.5, the attenuation and contrast enhancement pattern is uniform and considered within normal limits.

The cardiovascular structures including the pulmonary vasculature are within normal limits.

The bronchial tree presents with regular branching and tapers uniformly towards the periphery as expected, the bronchial walls are thin and smooth. The bronchus-to-artery ratio is within normal limits.

The lung parenchyma presents the expected architecture and attenuation behavior with interspersed punctuate mineralization

PATIENT

Jaz Bechtel

SPECIES

Canine

BREED

Cur

SEX

FS

AGE

13 Years

INTERPRETED BY

Sebastian Schaub, DVM
Dr. med. vet. DipECVDI

HOSPITAL NAME

Mobile Pet Imaging
CFL

REFERRING VET

Borecky

INVOICE

51225

DATE

3-29-22

Small incidental gas pockets are seen within the esophageal lumen, there is no evidence of abnormal dilation.

COMPUTED TOMOGRAPHIC DIAGNOSIS

- Polypoid mass level with the external opening of the left external acoustic meatus with central dystrophic mineralization
- Periodontal disease 108
- Multiple absent teeth
- Pulmonary osteomas
- No evidence of pulmonary metastatic disease.

INTERPRETATION OF THE FINDINGS & FURTHER RECOMMENDATIONS

The polypoid mass bulging into the external opening of the left external ear canal is fitting the history of epithelial neoplasia. There are no signs for overt local invasive growth. Excisional biopsy of the mass appears beneficial and second surgical session might be indicated based on dignity determined by histopathology.

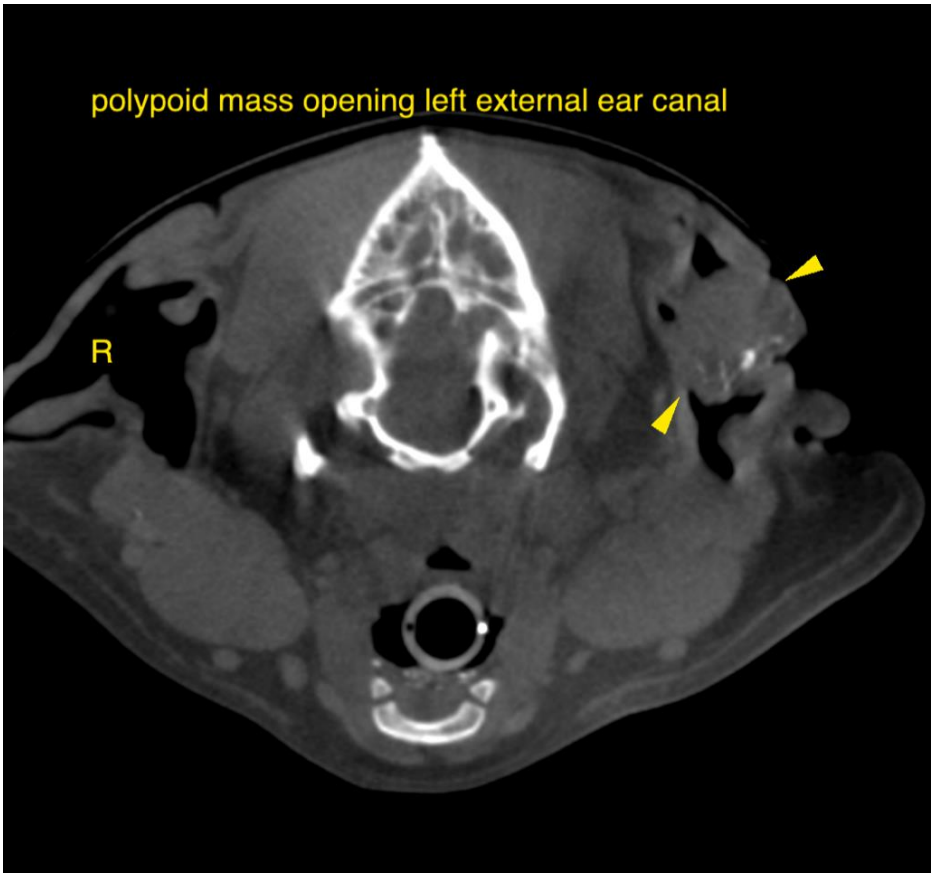

SonoPath Teleradiology

MOBILE PET IMAGING®
VETERINARY CT SCANS & FLUOROSCOPIES

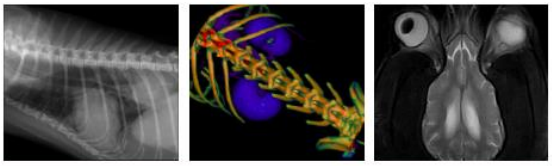

EDUCATIONAL TELECONSULTATION SERVICES™

SonoPath.com
1-800-838-4268 info@sonopath.com

PATIENT

Jaz Bechtel

SPECIES

Canine

BREED

Cur

SEX

FS

AGE

13 Years

INTERPRETED BY

Sebastian Schaub, DVM
Dr. med. vet. DipECVDI

HOSPITAL NAME

Mobile Pet Imaging
CFL

REFERRING VET

Borecky

INVOICE

51225

DATE

3-29-22

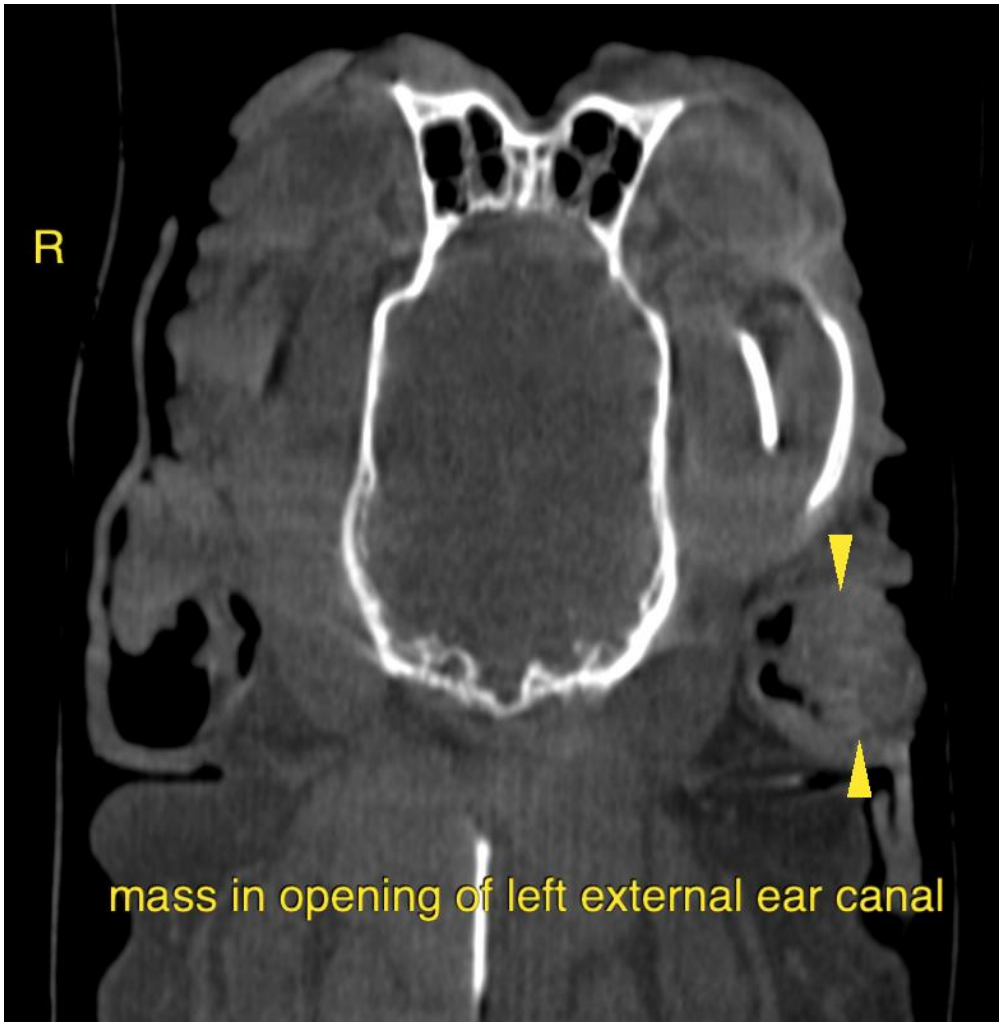

The information and recommendations provided are based on the images presented by the referring veterinarian/sonographer. No evaluation can be communicated regarding pathology that was not visible in the image/video clips provided.

Thank you for this referral. If the clinical or image interpretation does not parallel your findings or if I can be of any further assistance please contact me.

Sebastian Schaub, Sebastian Schaub, DVM, Dr. med. vet. DipECVDI
sebast.schaub@gmail.com