



PATIENT

Chia RDR

PRESENTING CLINICAL SIGNS

Rescued from streets of Jersey City, NJ. Estimated 8yr old. Presenting for mammary mass removal, spay, and dental. Grade 3-4 dental disease. Crackles auscultated in all lung fields (L ventral most prominent). No heart murmur auscultated. r/o metastatic neoplasia vs. pneumonia vs. cardiac vs. other.

SPECIES

Canine

RADIOGRAPHIC STUDY OF THE THORAX & ABDOMEN

A complete set of radiographs of the thorax and abdomen is provided for review.

BREED

Chihuahua

RADIOGRAPHIC FINDINGS

Thorax

SEX

F

The extrathoracic soft tissues present homogeneous without abnormalities.

The heart is of normal size and shape, there is no evidence of cardiac chamber or vascular enlargement. The pulmonary vasculature is within normal limits.

AGE

8

The cranial mediastinum presents the expected soft tissue opacity. The mediastinal width is less than twice the width of the vertebral column at the same level.

The trachea is normal in diameter and presents the anticipated course. The luminal outline of the trachea is smooth.

INTERPRETED BY

Sebastian Schaub, DVM
Dr. med. vet. DipECVDI

The bronchial tree presents with thin walls and tapers uniformly towards the periphery as expected.

HOSPITAL NAME

Bergen County
Veterinary Center

In the VD projection of the thorax, level with the 6th right intercostal space, a roundish soft tissue opaque nodule, measuring 5 mm in diameter is visible. The lung parenchyma presents the expected architecture and opacity; the intrapulmonary vascular branching is seen up to the third order lung vessels.

The diaphragm is well delineated with even surface and the expected mild cranial bulging of the diaphragmatic cupola.

REFERRING VET

Dr. Moore

Abdomen

The caudal parts of the abdomen are cropped by the collimation.

INVOICE

51220

The intervertebral disc space T12/T13 is collapsed.

In the subcutaneous tissue at the left cranioventral abdominal wall an irregular, centrally mineralized swelling is visible; measuring approximately 25 x 7 mm in size.

DATE

3-29-22

The serosal detail is maintained throughout the peritoneal and retroperitoneal space.

The liver is appropriate in position, size and presents uniform opacity.

The splenic head is in the anticipated position and within normal limits for size and opacity. The



PATIENT splenic body and tail are not appreciated.

Chia RDR The stomach is in its anticipated position and presents normal content.

The small intestinal loops are of even diameter and non-dilated, a small amount of gas is seen within the small intestinal loops and considered within normal limits.

SPECIES

Canine

RADIOGRAPHIC DIAGNOSIS

BREED

Chihuahua

- History of mammary mass left cranioventral abdominal wall – with central dystrophic mineralization
- Solitary pulmonary soft tissue nodule
- Chronic discopathy T12/T13

INTERPRETATION OF THE FINDINGS & FURTHER RECOMMENDATIONS

SEX

F

The findings are fitting the history of a mammary mass – suspect mammary carcinoma with dystrophic mineralization or metaplasia.

AGE

8

The solitary pulmonary nodule is concerning for pulmonary metastatic spread. Potentials include granuloma, round pneumonia/mucus impaction, pulmonary cyst, fibrosis.

INTERPRETED BY

Sebastian Schaub, DVM
Dr. med. vet. DipECVDI

HOSPITAL NAME

Bergen County
Veterinary Center

REFERRING VET

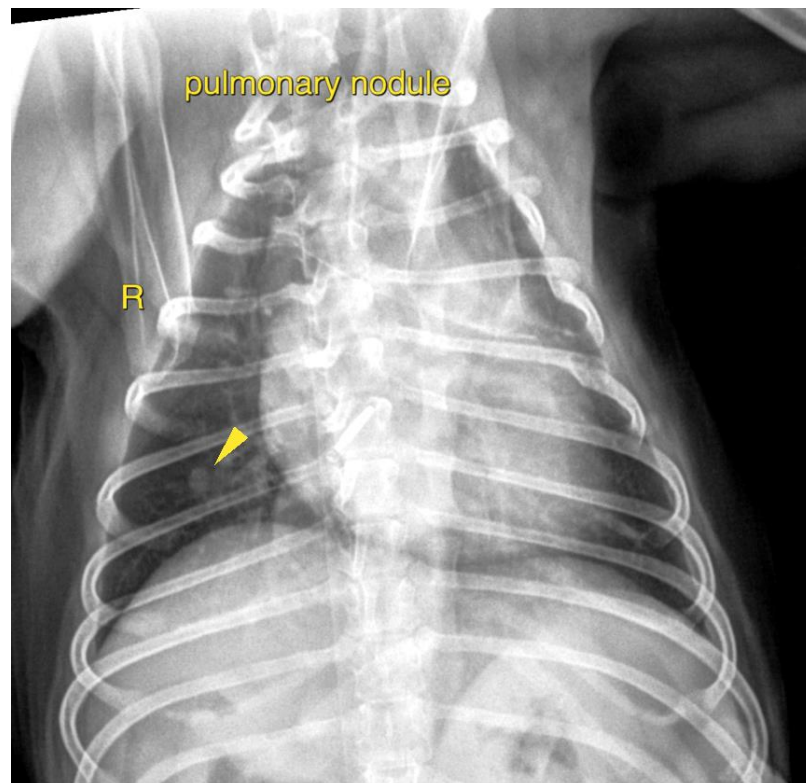
Dr. Moore

INVOICE

51220

DATE

3-29-22





PATIENT

Chia RDR

SPECIES

Canine

BREED

Chihuahua

SEX

F

AGE

8

INTERPRETED BY

Sebastian Schaub, DVM
Dr. med. vet. DipECVDI

HOSPITAL NAME

Bergen County
Veterinary Center

REFERRING VET

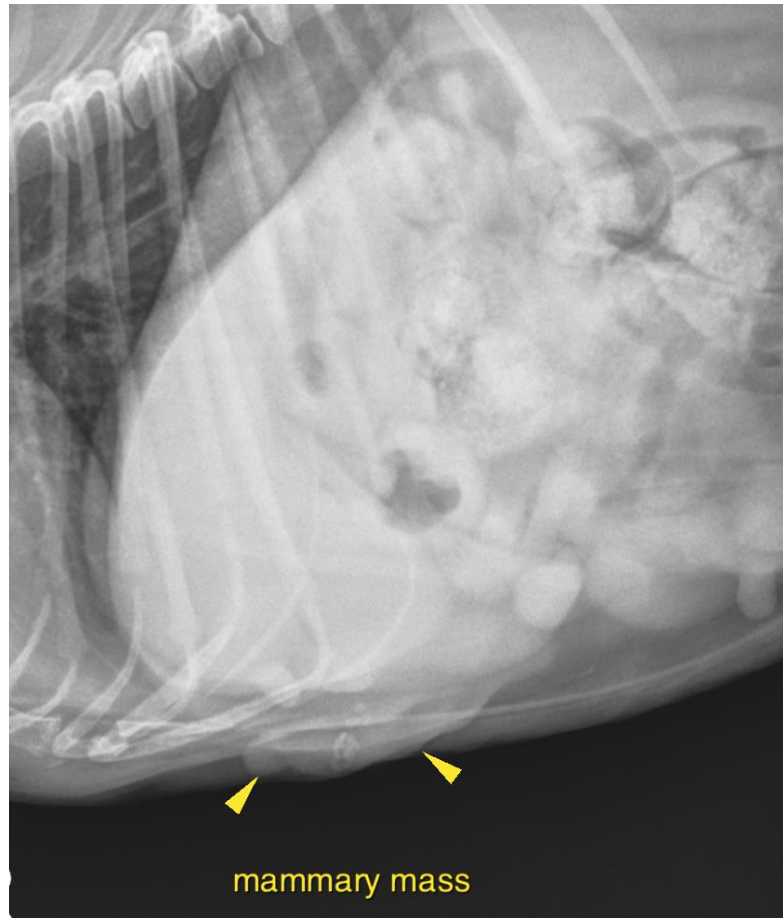Dr. Moore

INVOICE

51220

DATE

3-29-22



The information and recommendations provided are based on the images presented by the referring veterinarian/sonographer. No evaluation can be communicated regarding pathology that was not visible in the image/video clips provided.

Thank you for this referral. If the clinical or image interpretation does not parallel your findings or if I can be of any further assistance please contact me.

Sebastian Schaub, Sebastian Schaub, DVM, Dr. med. vet. DipECVDI
sebast.schaub@gmail.com