



**PATIENT PRESENTING CLINICAL SIGNS**

Rio Ginther Bilateral elbow dysplasia. CT to assist with surgical planning.  
Abnormal PE/Chem/CBC/UA Results: Increased WBC  $17.08 \times 10^9/L$

**SPECIES COMPUTED TOMOGRAPHY OF THE ELBOW JOINTS**

Canine A high resolution plain CT study of the elbow joints is provided for review.

**COMPUTED TOMOGRAPHIC FINDINGS**

**BREED** The periarticular bones of both elbow joints present moderate osteophyte new bone formation. The medial coronoid process of both elbow joints is misshapen, and an isolated osseous fragment is seen at the cranial aspect, measuring 4 x 3 x 3 mm (left)/5 x 3 x 4 mm (right). A second small isolated mineral attenuating fragment is seen in the left elbow joint, caudomedially to the large fragment measuring 1.3 x 1.3 x 2.5 mm. The sesamoid bone of the supinator muscle bilaterally is prominent – considered as normal anatomical variant.

Chow Chow

**SEX**

Male Intact

**COMPUTED TOMOGRAPHIC DIAGNOSIS**

- Fragmented medial coronoid process (FCP) elbow joints bilaterally
- Moderate degenerative osteoarthritis elbow joints bilaterally

**AGE**

1 Year, 8 Months

**INTERPRETATION OF THE FINDINGS & FURTHER RECOMMENDATIONS**

**INTERPRETED BY**

The findings are consistent with moderate chronic degenerative joint disease of both elbow joints due to a fragmented medial coronoid process.

Sebastian Schaub, DVM  
Dr. med. vet. DipECVDI

Arthroscopy/arthrotomy would be ideal to revise the elbow joints and remove the fragments of the medial coronoid process and prevent further damage.

**HOSPITAL NAME**

Bridgwater  
Veterinary Hospital  
and Wellness Centre

**REFERRING VET**

Dr. J. Enns

**INVOICE**

57486

**DATE**

3-28-23



**PATIENT**

Rio Ginther

**SPECIES**

Canine

**BREED**

Chow Chow

**SEX**

Male Intact

**AGE**

1 Year, 8 Months

**INTERPRETED BY**

Sebastian Schaub, DVM  
Dr. med. vet. DipECVDI

**HOSPITAL NAME**

Bridgwater  
Veterinary Hospital  
and Wellness Centre

**REFERRING VET**

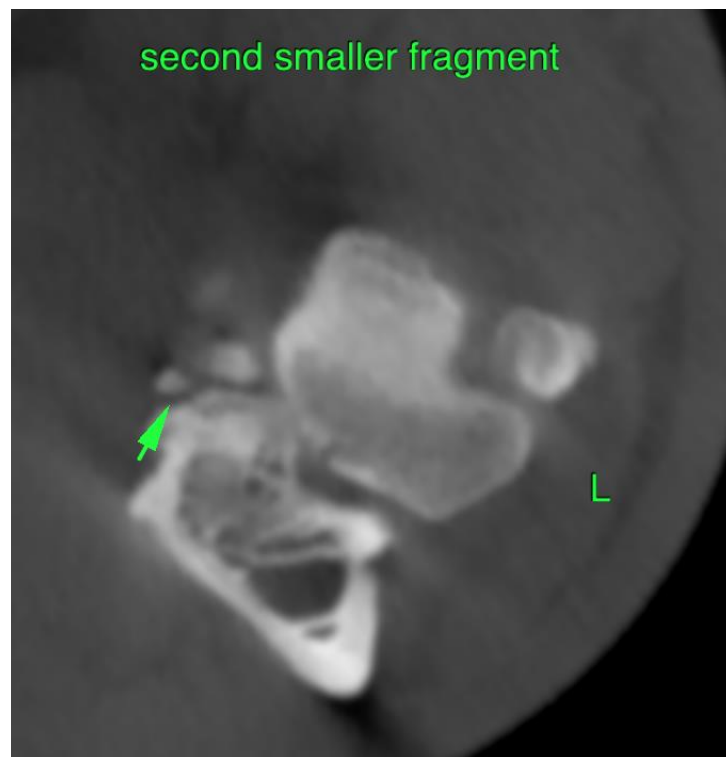
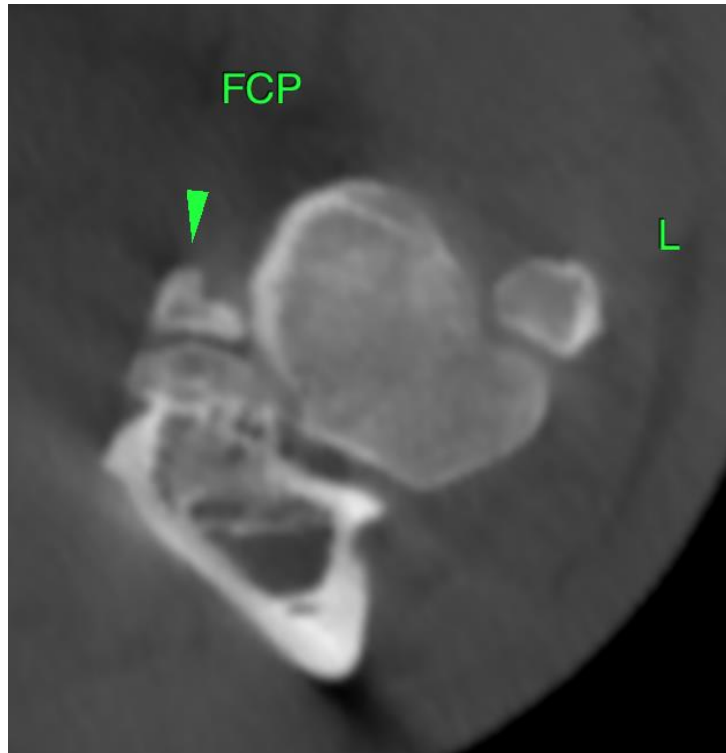
Dr. J. Enns

**INVOICE**

57486

**DATE**

3-28-23





**PATIENT**

Rio Ginther

**SPECIES**

Canine

**BREED**

Chow Chow

**SEX**

Male Intact

**AGE**

1 Year, 8 Months

**INTERPRETED BY**

Sebastian Schaub, DVM  
Dr. med. vet. DipECVDI

**HOSPITAL NAME**

Bridgwater  
Veterinary Hospital  
and Wellness Centre

**REFERRING VET**

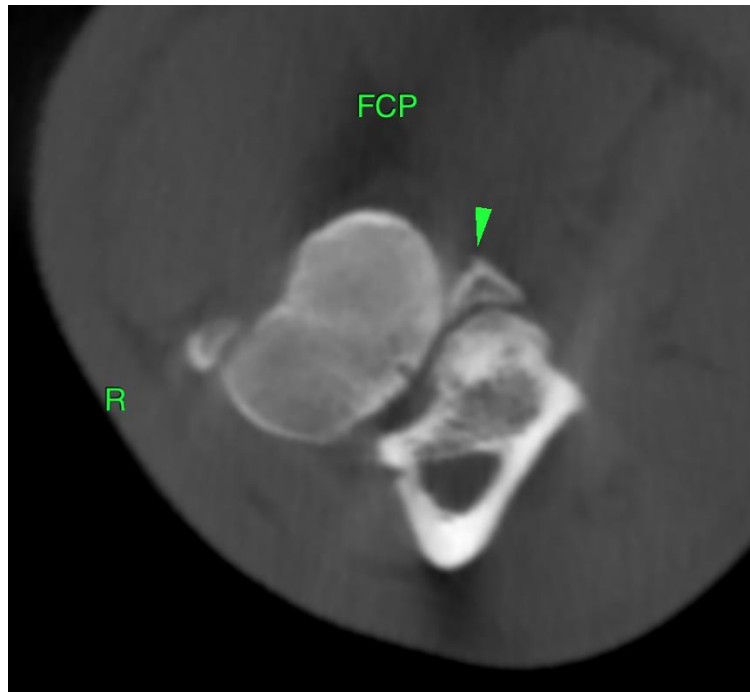
Dr. J. Enns

**INVOICE**

57486

**DATE**

3-28-23



The information and recommendations provided are based on the images presented by the referring veterinarian/sonographer. No evaluation can be communicated regarding pathology that was not visible in the image/video clips provided.

Thank you for this referral. If the clinical or image interpretation does not parallel your findings or if I can be of any further assistance please contact me.

**Sebastian Schaub**, Sebastian Schaub, DVM, Dr. med. vet. DipECVDI  
sebast.schaub@gmail.com