

**PATIENT PRESENTING CLINICAL SIGNS**

**BB Cahoon** Patient presented for CT Scan of Skull and Thorax. Clinical signs include epistaxis, sneezing blood and hacking cough that is getting worse.

**SPECIES COMPUTED TOMOGRAPHY OF THE SKULL, THORAX AND ABDOMEN**

**Canine** A high resolution pre- and post-contrast CT study of the skull and abdomen and a post-contrast CT study of the thorax are provided for review.

**BREED COMPUTED TOMOGRAPHIC FINDINGS**

**Lab Mix** Skull

Triadan 305&405 are absent.

**SEX** The right nasal cavity is occupied by soft tissue attenuating and mild heterogeneous contrast enhancing material. Advanced destruction of the associated nasal conchal & turbinate structures is seen. Level with the maxillary fourth premolar teeth, the right nasal soft tissue material is perforating the nasal septum in the dorsal aspect and bulging into the left nasal cavity. The right maxillary bone presents multifocal moth eaten osteolytic lesions and very mild immature periosteal new bone formation. The perpendicular plate of the right palatine bone is perforated. The right frontal sinus is filled with fluid attenuating material. The cribriform plate is intact.

**AGE** 10 Years

Both temporomandibular joints present congruent joint spaces with even subchondral bone surfaces and are considered within normal limits.

**INTERPRETED BY**

Sebastian Schaub, DVM  
Dr. med. vet. DipECVDI

Both tympanic bullae are aerated, the mucosal lining is not seen, the bony wall is smooth and thin. The external ear canals present moderate shell like mineralization of the wall.

**HOSPITAL NAME**

Mobile Pet Imaging  
CFL

The brain presents no deviation from normal anatomy and symmetry. The brain parenchyma is homogeneous and within normal limits for attenuation and distribution of contrast enhancement. The ventricular system is non-dilated and symmetric.

The submandibular and medial retropharyngeal lymph nodes are small and elongated with a normal short-to-long-axis-ratio is < 0.5, the attenuation and contrast enhancement pattern is uniform.

**REFERRING VET** Thorax

**Borecky** The bony and surrounding soft tissue structures are within normal limits. Generalized mild peripheral mineralization of the dural tube is present.

**INVOICE** The sternal, cranial mediastinal and tracheobronchial lymph nodes are small elongated with a normal short-to-long-axis-ratio is < 0.5, the attenuation and contrast enhancement pattern is uniform and considered within normal limits.

51203

The cardiovascular structures including the pulmonary vasculature are within normal limits.

**DATE**

3-28-22

The bronchial tree presents with regular branching and tapers uniformly towards the periphery as expected, the bronchial walls are thin and smooth. The bronchus-to-artery ratio is within normal limits.


**PATIENT**

BB Cahoon

The left lung lobes present a moderately decreased volume and multiple ground glass attenuating zones. The remainder of the lung parenchyma present the expected architecture and attenuation behavior.

**SPECIES**

Canine

Small incidental gas pockets are seen within the esophageal lumen, there is no evidence of abnormal dilation.

**BREED**

Lab Mix

**COMPUTED TOMOGRAPHIC DIAGNOSIS**

- Right sided biologically semiaggressive nasal mass with polyostotic aggressive osteolytic lesions of the surrounding osseous structures
- Absent triadan 305&405
- Dystrophic mineralization external ear canals
- Incidental dural mineralization along the thoracic spine
- No evidence of pulmonary metastatic disease

**SEX**

FS

**INTERPRETATION OF THE FINDINGS & FURTHER RECOMMENDATIONS**
**AGE**

10 Years

The findings are consistent with primary nasal neoplasia, originating from the right nasal cavity with secondary obstructive sinusitis of the right frontal sinus. Differentials include adenocarcinoma, squamous cell carcinoma, transitional cell carcinoma, lymphosarcoma, other. Rhinoscopy including FNA sampling can be used as advanced diagnostic tests. Based on the results of the advanced diagnostic tests, the chances of radiation therapy can be discussed with oncologist. The Adam tumor stage is T3.

**INTERPRETED BY**

 Sebastian Schaub, DVM  
 Dr. med. vet. DipECVDI

**HOSPITAL NAME**

 Mobile Pet Imaging  
 CFL

**REFERRING VET**

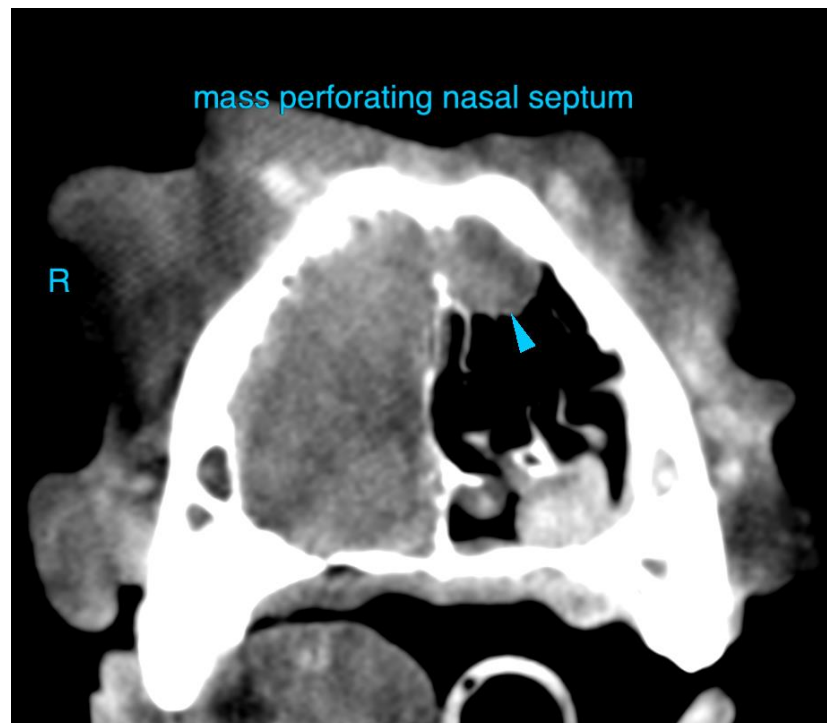
Borecky

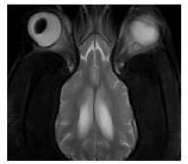
**INVOICE**

51203

**DATE**

3-28-22





**PATIENT**

BB Cahoon

**SPECIES**

Canine

**BREED**

Lab Mix

**SEX**

FS

**AGE**

10 Years

**INTERPRETED BY**

Sebastian Schaub, DVM  
Dr. med. vet. DipECVDI

**HOSPITAL NAME**

Mobile Pet Imaging  
CFL

**REFERRING VET**

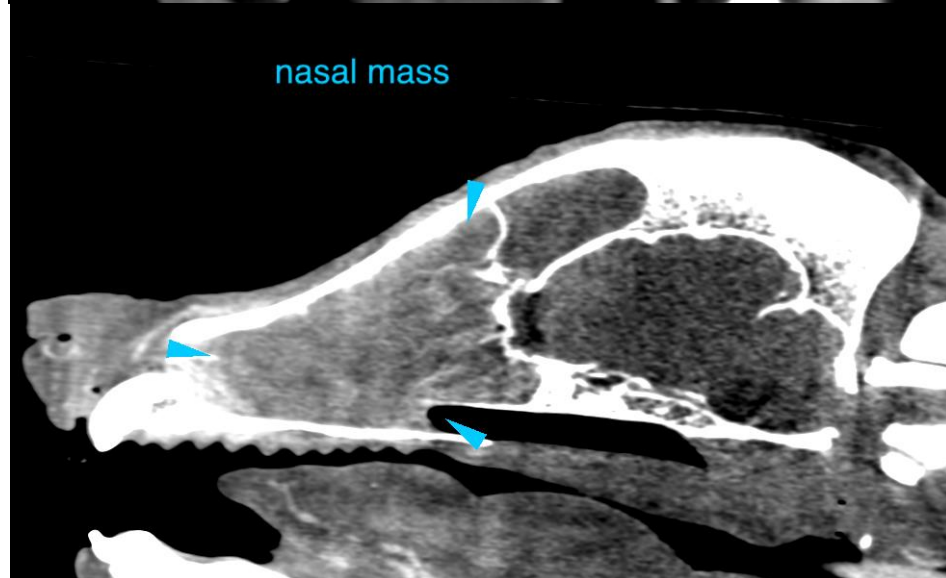
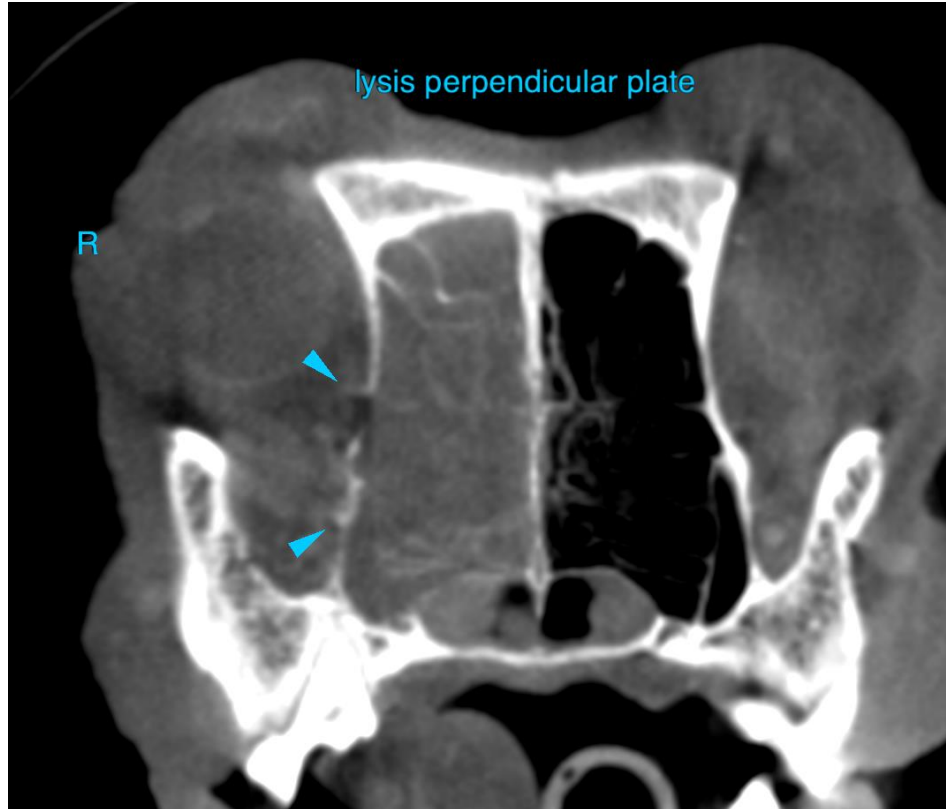
Borecky

**INVOICE**

51203

**DATE**

3-28-22





**PATIENT**

BB Cahoon

The information and recommendations provided are based on the images presented by the referring veterinarian/sonographer. No evaluation can be communicated regarding pathology that was not visible in the image/video clips provided.

**SPECIES**

Canine

Thank you for this referral. If the clinical or image interpretation does not parallel your findings or if I can be of any further assistance please contact me.

**Sebastian Schaub**, Sebastian Schaub, DVM, Dr. med. vet. DipECVDI  
sebast.schaub@gmail.com

**BREED**

Lab Mix

**SEX**

FS

**AGE**

10 Years

**INTERPRETED BY**

Sebastian Schaub, DVM  
Dr. med. vet. DipECVDI

**HOSPITAL NAME**

Mobile Pet Imaging  
CFL

**REFERRING VET**

Borecky

**INVOICE**

51203

**DATE**

3-28-22