



## PATIENT

Delphie Cue

## SPECIES

Canine

## BREED

Mixed

## SEX

Spayed Female

## AGE

8 Years

## WEIGHT

9 Pounds

## INTERPRETED BY

Sebastian Schaub, DVM  
Dr. med. vet. DipECVDI

## IMAGING PERFORMED BY

Alondra Aviles Lopez,  
VT

## HOSPITAL NAME

Veterinary Image  
Center

## REFERRING VET

Dr. Karina Miranda

## INVOICE

36430

## DATE

3/27/26

## PRESENTING CLINICAL SIGNS

- P presented for mammary tumor removal via surgery as recommended 3/11/26, radiographs performed to rule out metastasis pre-op and a primary lung tumor was found in dorsal caudal chest cavity.
- Abnormal PE/Chem/CBC/UA Results: CBC: WNL CHEM: GLOB 4.6 g/dL (2.5-4.5) ECG: Normal

## COMPUTED TOMOGRAPHIC STUDY OF THE THORAX AND ABDOMEN

A high resolution pre- and post-contrast CT study of the thorax and a post-contrast CT study of the abdomen is provided for review.

## COMPUTED TOMOGRAPHIC FINDINGS

### Thorax

The bony and surrounding soft tissue structures are within normal limits.

The sternal, cranial mediastinal and tracheobronchial lymph nodes are small elongated with a normal short-to-long-axis-ratio is  $< 0.5$ , the attenuation and contrast enhancement pattern is uniform and considered within normal limits.

The cardiovascular structures including the pulmonary vasculature are within normal limits.

The bronchial tree presents with regular branching and tapers uniformly towards the periphery as expected, the bronchial walls are thin and smooth. The bronchus-to-artery ratio is within normal limits.

The lung parenchyma presents the expected architecture and attenuation behavior.

Centered on the left lateral wall of the caudal intrathoracic segment of the esophagus/the cardia, a uniform soft tissue attenuating and mild irregular contrast enhancing ovoidal shaped mass is seen; measuring 3.8 x 2.9 x 4.3 cm. Thin, contrast enhancing septa are emanating from the esophageal wall and are extending into the mass. The cardia is positioned cranial to the esophageal hiatus of the diaphragm. The medial surface of the left caudal lung lobe level with the mass is depressed by the extrapleural mass effect.

### Abdomen

The serosal fat presents normal attenuation behavior. There is no evidence of peritoneal effusion or peritonitis.

Both kidneys present within normal limits for size, shape and organ architecture. After contrast administration a bilaterally symmetric and uniform nephro- and pyelogram is noted.

The adrenal glands are within normal limits for size, shape and organ architecture.

Both liver and spleen present with normal shape, even surface, uniformly attenuating parenchyma. The hepatic parenchyma has a uniform contrast enhancement pattern. The splenic parenchyma has a heterogeneous contrast enhancement pattern, presenting multiple hyperattenuating foci throughout the parenchyma.



## PATIENT

The pancreas is evenly contoured; the pancreatic parenchyma is homogeneous and presents uniform contrast enhancement.

Delphie Cue

## SPECIES

The position, delineation, wall and content of the gastrointestinal tract are considered within normal limits throughout.

Canine

The parenchyma of the left mammary complex #4 presents an irregular nodular, uniform soft tissue attenuating and mild heterogeneous contrast enhancing mass, measuring 10 x 7 x 18 mm.

## BREED

The left inguinal lymph node is moderately prominent and rounded.

Mixed

## COMPUTED TOMOGRAPHIC DIAGNOSIS

### SEX

- Intramural esophageal soft tissue mass/intramural mass of the cardia of the stomach cranial to the diaphragm
- History of mammary tumor left mammary complex #4
- Lymphadenopathy left inguinal lymph node
- Heterogeneous contrast enhancement pattern of the spleen
- No evidence of pulmonary metastatic disease
- No evidence of pulmonary metastatic disease
- Normal abdomen

Spayed Female

### AGE

8 Years

### WEIGHT

9 Pounds

## INTERPRETATION OF THE FINDINGS & FURTHER RECOMMENDATIONS

## INTERPRETED BY

The appreciated mass is originating either from the most caudal intrathoracic segment of the esophageal wall or the cardia of the stomach that appears to be displaced cranial to the esophageal hiatus of the diaphragm. Differentials include leiomyoma/leiomyosarcoma, rhabdomyosarcoma, adenocarcinoma, other. Due to the position of the mass, surgical management may not be feasible.

Sebastian Schaub, DVM  
Dr. med. vet. DipECVCI

The odds for metastatic spread of the mammary mass to the left inguinal lymph node are high.

## IMAGING PERFORMED BY

The heterogeneous contrast enhancement pattern of the splenic parenchyma is likely a sequela to nodular hyperplasia, extramedullary hematopoiesis or splenitis. FNA sampling can be performed to rule out malignant infiltration entirely.

Alondra Aviles Lopez,  
VT

## HOSPITAL NAME

Veterinary Image  
Center

## REFERRING VET

Dr. Karina Miranda

## INVOICE

36430

## DATE

3/27/26



## PATIENT

Delphie Cue

## SPECIES

Canine

## BREED

Mixed

## SEX

Spayed Female

## AGE

8 Years

## WEIGHT

9 Pounds

## INTERPRETED BY

Sebastian Schaub, DVM  
Dr. med. vet. DipECVDI

## IMAGING PERFORMED BY

Alondra Aviles Lopez,  
VT

## HOSPITAL NAME

Veterinary Image  
Center

## REFERRING VET

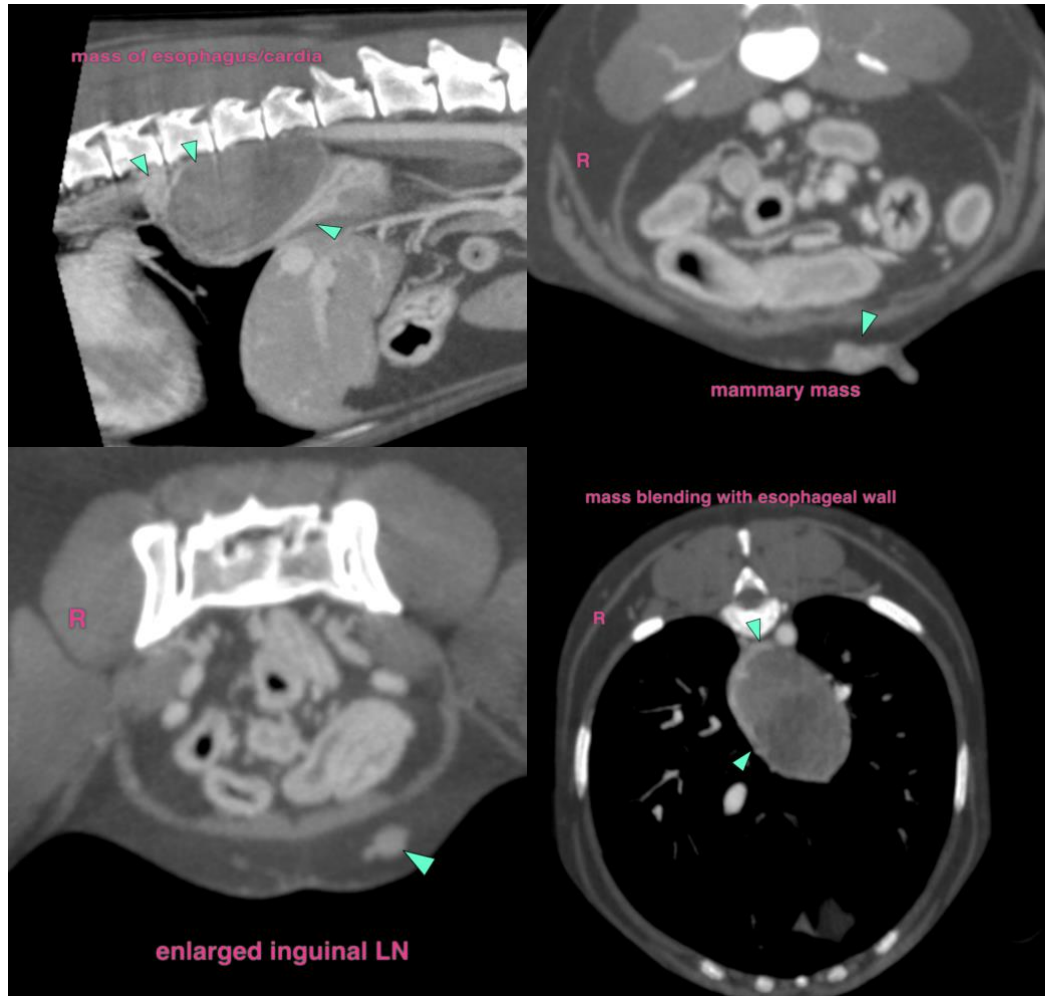
Dr. Karina Miranda

## INVOICE

36430

## DATE

3/27/26



The information and recommendations provided are based on the images presented by the referring veterinarian/sonographer. No evaluation can be communicated regarding pathology that was not visible in the image/video clips provided.

Thank you for this referral. If the clinical or image interpretation does not parallel your findings or if I can be of any further assistance please contact me.

Sebastian Schaub, DVM, Dr. med. vet. DipECVDI  
[info@sonopath.com](mailto:info@sonopath.com)