

PATIENT

Briar Calderon

SPECIES

Feline

BREED

DSH

SEX

Spayed Female

AGE

2 Years

WEIGHT

9.8 Pounds

INTERPRETED BY

Sebastian Schaub, DVM
Dr. med. vet. DipECVDI

IMAGING PERFORMED BY

Dr. Salas

HOSPITAL NAME

Tenaflly VC

REFERRING VET

Dr. Salas

INVOICE

36429

DATE

3/27/26

PRESENTING CLINICAL SIGNS

2 yr old FS DSHA, had CT on 1/23/2026 and diagnosed: COMPUTED TOMOGRAPHIC DIAGNOSIS Chronic bilateral otitis media- left more advanced than right. Bilateral otitis externa. No polyps or intracranial extension seen. Pet was treated with 4 weeks of Enrofloxacin and 8 week steroid taper. doing well clinically. Repeat CT taken today.

COMPUTED TOMOGRAPHIC STUDY OF THE SKULL

A high-resolution plain CT study of the neurocranium is provided for review.

COMPUTED TOMOGRAPHIC FINDINGS

Both temporomandibular joints present congruent joint spaces with even subchondral bone surfaces and are considered within normal limits.

The left tympanic bulla is filled with soft tissue attenuating material. The osseous wall of the left tympanic bulla is irregularly thickened. The right tympanic bulla is aerated and presents a smooth and thin osseous wall. The external ear canals are within normal limits.

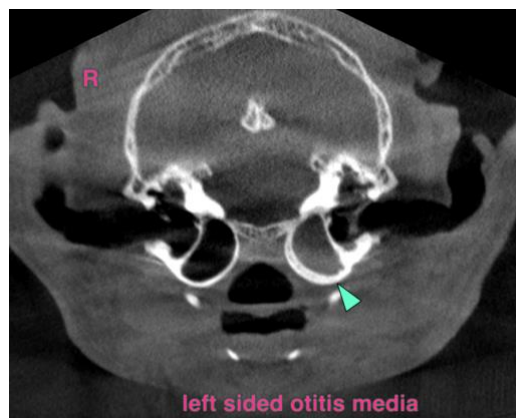
The submandibular lymph nodes are small and elongated with a normal short-to-long-axis-ratio is < 0.5, the attenuation and contrast enhancement pattern is uniform.

COMPUTED TOMOGRAPHIC DIAGNOSIS

- Left sided chronic otitis media
- No evidence of inflammatory polyp formation
- Remission of the described right sided otitis media

INTERPRETATION OF THE FINDINGS & FURTHER RECOMMENDATIONS

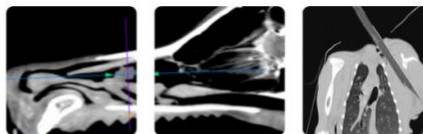
CT shows persistent left otitis media and resolved right otitis media.



The information and recommendations provided are based on the images presented by the referring veterinarian/sonographer. No evaluation can be communicated regarding pathology that was not visible in the image/video clips provided.

Thank you for this referral. If the clinical or image interpretation does not parallel your findings or if I can be of any further assistance please contact me.

Sebastian Schaub, DVM, Dr. med. vet. DipECVDI



PATIENT

info@sonopath.com

Briar Calderon

SPECIES

Feline

BREED

DSH

SEX

Spayed Female

AGE

2 Years

WEIGHT

9.8 Pounds

INTERPRETED BY

Sebastian Schaub, DVM
Dr. med. vet. DipECVDI

IMAGING PERFORMED BY

Dr. Salas

HOSPITAL NAME

Tenafly VC

REFERRING VET

Dr. Salas

INVOICE

36429

DATE

3/27/26