SonoPath Teleradiology

EDUCATIONAL TELECONSULTATION SERVICES™

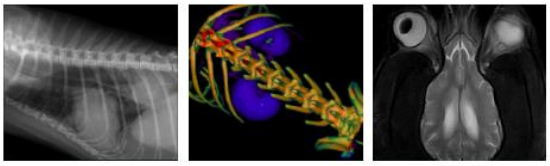

SonoPath.com
1-800-838-4268 info@sonopath.com

PATIENT

Watson Holmes

SPECIES

Canine

BREED

Mix

SEX

MN

AGE

12

INTERPRETED BY

Sebastian Schaub, DVM
Dr. med. vet. DipECVDI

HOSPITAL NAME

Animal Hospital of Stoney Creek

REFERRING VET

Dr. Martin

INVOICE

57440

DATE

3-27-23

PRESENTING CLINICAL SIGNS

Off food last 2 weeks. General exam, abdominal breathing. Lungs/Chest NAF on auscultation
Abnormal PE/Chem/CBC/UA Results: WNL - completed 3 weeks ago while COHAT

RADIOGRAPHIC STUDY OF THE THORAX

Radiographs of the thorax in three imaging planes are provided for review.

RADIOGRAPHIC FINDINGS

The surrounding bony structures are within normal limits.

In the subcutaneous tissue at the left caudolateral thoracic wall, level with the 10th to 12th left rib, a well-defined, ovoid shaped fat opaque mass is seen.

The heart is of normal size and shape, there is no evidence of cardiac chamber or vascular enlargement. The pulmonary vasculature is within normal limits.

The cranial mediastinum presents the expected soft tissue opacity. The mediastinal width is less than twice the width of the vertebral column at the same level.

The trachea is normal in diameter and presents the anticipated course. The luminal outline of the trachea is smooth.

The bronchial tree presents with thin walls and tapers uniformly towards the periphery as expected.

In the lateral projections the lung field is extending up to the level of the caudal vertebral endplate T9 – expiration. The lung parenchyma presents the expected architecture and generalized increased opacity; the intrapulmonary vascular branching is seen in the VD view but is effaced in the lateral projections.

The diaphragm is well delineated with even surface and the expected mild cranial bulging of the diaphragmatic cupola.

RADIOGRAPHIC DIAGNOSIS

- Normal thorax but subcutaneous lipoma left caudolateral thoracic wall

INTERPRETATION OF THE FINDINGS & FURTHER RECOMMENDATIONS

The generalized increased radiopacity of the lung parenchyma is considered as a sequela to hypoinflation of the lung parenchyma and the radiographic study of the thorax is considered otherwise normal.

SonoPath Teleradiology

EDUCATIONAL TELECONSULTATION SERVICES™

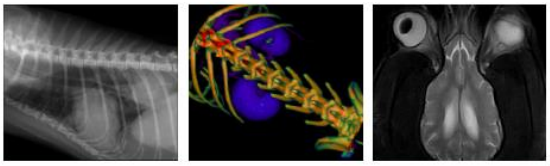

SonoPath.com
1-800-838-4268 info@sonopath.com

PATIENT

Watson Holmes

SPECIES

Canine

BREED

Mix

SEX

MN

AGE

12

INTERPRETED BY

Sebastian Schaub, DVM
Dr. med. vet. DipECVDI

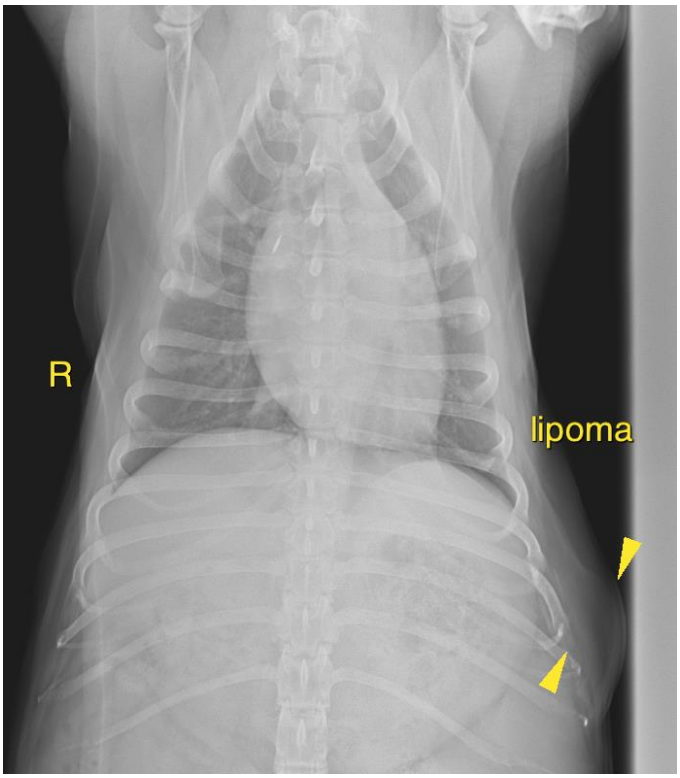

HOSPITAL NAME

Animal Hospital of Stoney Creek

REFERRING VET

Dr. Martin

INVOICE

57440

DATE

3-27-23

The information and recommendations provided are based on the images presented by the referring veterinarian/sonographer. No evaluation can be communicated regarding pathology that was not visible in the image/video clips provided.

Thank you for this referral. If the clinical or image interpretation does not parallel your findings or if I can be of any further assistance please contact me.

Sebastian Schaub, Sebastian Schaub, DVM, Dr. med. vet. DipECVDI
sebast.schaub@gmail.com