



PATIENT PRESENTING CLINICAL SIGNS

Hank Schmidt lytic mass effect digit 5 LFL: R/O neoplasia verse osteomyelitis.

RADIOGRAPHIC STUDY OF THE THORAX

SPECIES Radiographs of the thorax in three imaging planes are provided for review.

Canine **RADIOGRAPHIC FINDINGS**

The surrounding bony structures are within normal limits.

BREED The extrathoracic soft tissues present homogeneous without abnormalities.

Bernese Mountain Dog The heart is of normal size and shape, there is no evidence of cardiac chamber or vascular enlargement. The pulmonary vasculature is within normal limits.

SEX The cranial mediastinum presents the expected soft tissue opacity. The mediastinal width is less than twice the width of the vertebral column at the same level.

Male Neutered An endotracheal tube is seen in the cervical tracheal segment. The trachea is normal in diameter and presents the anticipated course. The luminal outline of the trachea is smooth.

AGE The bronchial tree presents with thin walls and tapers uniformly towards the periphery as expected.

9 The volume of the left cranial lung lobe is mild to moderately decreased and has a ground glass opacity – accentuated the caudal part – and a midline shift of the heart to the left is seen. The remainder of the lung parenchyma present the expected architecture and opacity; the intrapulmonary vascular branching is seen up to the third order lung vessels.

INTERPRETED BY

Sebastian Schaub, DVM
Dr. med. vet. DipECVCI

The diaphragm is well delineated with even surface and the expected mild cranial bulging of the diaphragmatic cupola.

RADIOGRAPHIC DIAGNOSIS

HOSPITAL NAME

- Normal thorax but dystelectasis left cranial lung lobe

Animal Surgical
Center

INTERPRETATION OF THE FINDINGS & FURTHER RECOMMENDATIONS

REFERRING VET

The radiographic study of the thorax presents without clinically relevant pathology. There is no evidence of primary nor secondary pulmonary neoplastic disease.

Centereach Animal
Hospital

INVOICE

57463

DATE

3-27-23



PATIENT

Hank Schmidt

SPECIES

Canine

BREED

Bernese Mountain
Dog

SEX

Male Neutered

AGE

9

INTERPRETED BY

Sebastian Schaub, DVM
Dr. med. vet. DipECVDI

HOSPITAL NAME

Animal Surgical
Center

REFERRING VET

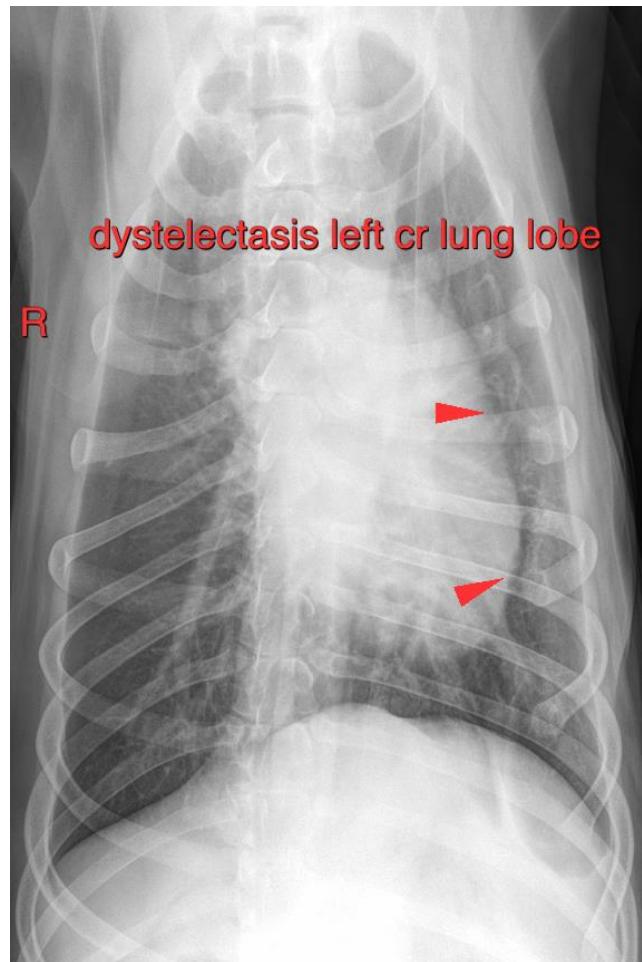
Centreach Animal
Hospital

INVOICE

57463

DATE

3-27-23



The information and recommendations provided are based on the images presented by the referring veterinarian/sonographer. No evaluation can be communicated regarding pathology that was not visible in the image/video clips provided.

Thank you for this referral. If the clinical or image interpretation does not parallel your findings or if I can be of any further assistance please contact me.

Sebastian Schaub, Sebastian Schaub, DVM, Dr. med. vet. DipECVDI
sebast.schaub@gmail.com