

**PATIENT**

Rey Gregory

PRESENTING CLINICAL SIGNS

Patient presents for evaluation for acute onset paraplegia. Paraplegia in both pelvic limbs, absent CP on both pelvic limbs as well. Superficial and deep pain perception present x 4. Radiographs display intervertebral disc disease at C2-3, C4-5, T 11-12, T 12-13, L5-6 and L6-7.

SPECIES

Canine

Abnormal PE/Chem/CBC/UA Results: WNL, NSF

COMPUTED TOMOGRAPHY OF THE THORACIC&LUMBAR SPINE

A post contrast and myelographic CT study of the thoracic & lumbar spine is provided for review.

BREEDAmerican Cocker
Spaniel**COMPUTED TOMOGRAPHIC FINDINGS**

THE LAST RIB BEARING VERTEBRA IS COUNTED AS T13.

SEX

FS

Level with the intervertebral disc space T12/T13, mild heterogeneous hyperattenuating material is visible in the left lateral aspect of the vertebral canal, occupying approximately up to 40% of the cross-sectional area of the vertebral canal at the same level. The mild hyperattenuating material is extending cranially up to the cranial third of the vertebral body of T11 and caudally up to the level of the caudal vertebral endplate of T13. After intrathecal contrast administration, the spinal cord at the same level is displaced to the right and distorted.

AGE

2 Years, 6 Months

COMPUTED TOMOGRAPHIC DIAGNOSIS

- Intervertebral disc extrusion T12/T13 with compressive myelopathy

INTERPRETED BYSebastian Schaub, DVM
Dr. med. vet. DipECVDI**INTERPRETATION OF THE FINDINGS & FURTHER RECOMMENDATIONS**

The intervertebral disc extrusion T12/T13 from the left is a plausible explanation for the presenting clinical signs. Extruded disc material/hemorrhage can be appreciated up to the cranial endplate of T11 and caudal endplate of T13. Surgical decompression is the therapy of choice.

HOSPITAL NAMESouth Bay Animal
Hospital**REFERRING VET**Ravinder Atwal, DVM,
CCRP**INVOICE**

51178

DATE

3-27-22



PATIENT

Rey Gregory

SPECIES

Canine

BREED

American Cocker
Spaniel

SEX

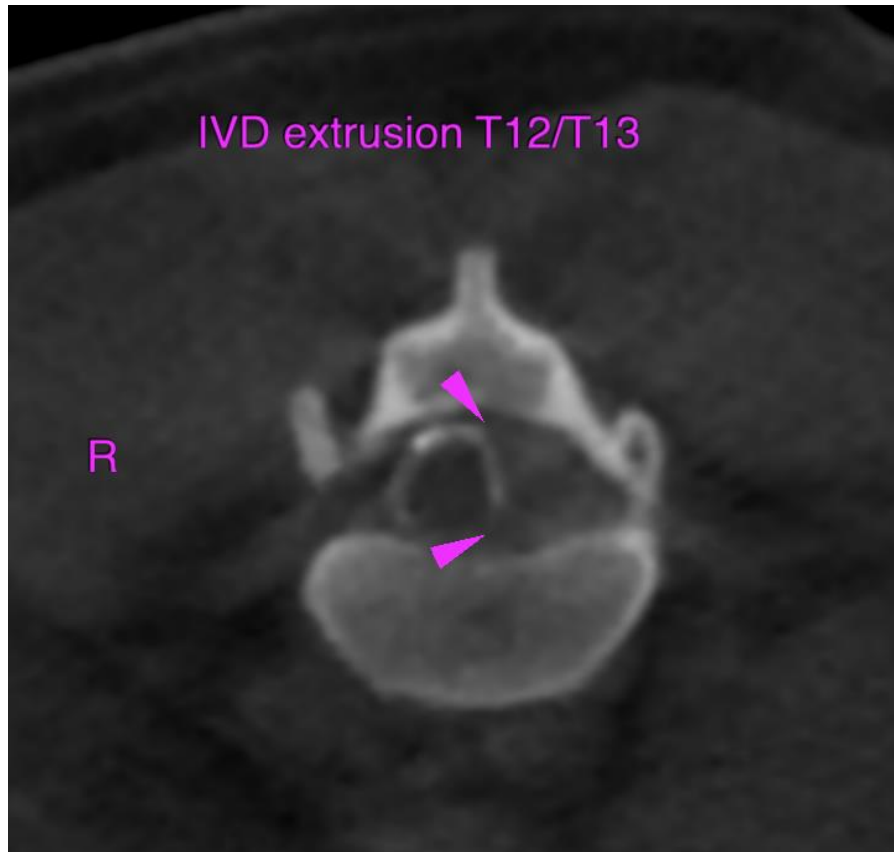
FS

AGE

2 Years, 6 Months

INTERPRETED BY

Sebastian Schaub, DVM
Dr. med. vet. DipECVDI



HOSPITAL NAME

South Bay Animal
Hospital

REFERRING VET

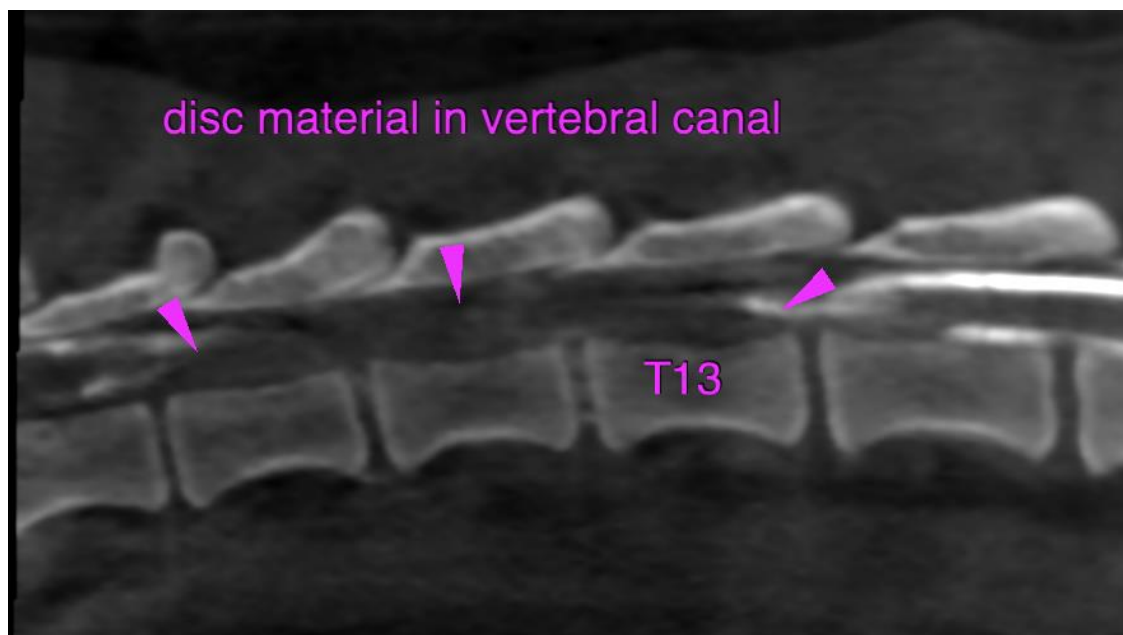
Ravinder Atwal, DVM,
CCRP

INVOICE

51178

DATE

3-27-22





PATIENT

Rey Greogory

SPECIES

Canine

The information and recommendations provided are based on the images presented by the referring veterinarian/sonographer. No evaluation can be communicated regarding pathology that was not visible in the image/video clips provided.

BREED

American Cocker
Spaniel

Thank you for this referral. If the clinical or image interpretation does not parallel your findings or if I can be of any further assistance please contact me.

Sebastian Schaub, Sebastian Schaub, DVM, Dr. med. vet. DipECVDI
sebast.schaub@gmail.com

SEX

FS

AGE

2 Years, 6 Months

INTERPRETED BY

Sebastian Schaub, DVM
Dr. med. vet. DipECVDI

HOSPITAL NAME

South Bay Animal
Hospital

REFERRING VET

Ravinder Atwal, DVM,
CCRP

INVOICE

51178

DATE

3-27-22