



PATIENT PRESENTING CLINICAL SIGNS

PATIENT
Piper Wilcox

SPECIES
Canine

BREED
Greyhound

SEX
FS

AGE
8 Years, 3 Months

INTERPRETED BY
Sebastian Schaub, DVM
Dr. med. vet. DipECVDI

HOSPITAL NAME
South Bay Animal Hospital

REFERRING VET
Ravinder Atwal, DVM, CCRP

INVOICE
51179

DATE
3-27-22

Patient presented for acute onset limping on the left pelvic limb. On PE, normal, no pain response elicited for palpation, flexion, and extension of the neck as well. Weight bearing lameness of the LPL seen. Sensitive in the left shoulder area. Radiographs of thorax reveal no gross abnormalities or evidence of metastasis. Radiographic Findings: There does appear to be poorly defined periosteum response with bone loss involving the distal aspect of the left radius. The carpus and elbow joint bilaterally are within normal limits. The cervical spine is within normal limits. The lateral view of the shoulder joint reveals osseous density associate with the greater tubercle without evidence of articular abnormalities. Conclusion: The appearance of the distal radius on the left is highly concerning for a primary bone neoplasia. Chronic appearing supraspinatus avulsion is also identified involving the shoulder. The remainder of the pattern is within normal limits A CT of both forelimbs and the thorax is submitted for review. Biopsy of the lesion pending to the reference lab for histopathology.

Abnormal PE/Chem/CBC/UA Results: Marginal AST & CPK elevations, rest NSF

COMPUTED TOMOGRAPHY OF THE THORAX AND FRONT LIMBS

A high resolution pre- and post-contrast CT study of the skull and abdomen and a post-contrast CT study of the thorax are provided for review.

COMPUTED TOMOGRAPHIC FINDINGS

The vertebral endplates T9/T10 present mild spondylosis formation.

The distal epiphysis of the left radius presents with an ill-defined zone with permeative osteolysis, perforating the cortex caudally and mild local endosteal scalloping. The osteolytic lesions and accompanying mild heterogeneous sclerosis of the medullary cavity can be appreciated up into the distal diaphysis of the left radius. Post contrast administration focal moderate heterogeneous contrast enhancement of the osteolytic region is seen.

The sternal, cranial mediastinal and tracheobronchial lymph nodes are small elongated with a normal short-to-long-axis-ratio is < 0.5, the attenuation and contrast enhancement pattern is uniform and considered within normal limits.

The cardiovascular structures including the pulmonary vasculature are within normal limits.

The bronchial tree presents with regular branching and tapers uniformly towards the periphery as expected, the bronchial walls are thin and smooth. The bronchus-to-artery ratio is within normal limits.

The lung parenchyma presents the expected architecture and attenuation behavior.

Small incidental gas pockets are seen within the esophageal lumen, there is no evidence of abnormal dilation.

COMPUTED TOMOGRAPHIC DIAGNOSIS

- Monostotic aggressive osteolytic lesion left distal radius
- Spondylosis deformans T9/T10



PATIENT

Piper Wilcox

- No evidence of pulmonary metastatic disease

INTERPRETATION OF THE FINDINGS & FURTHER RECOMMENDATIONS

The lesion of the left distal radius is supporting the diagnosis of primary osseous neoplasia – such as osteosarcoma, chondrosarcoma, round cell tumor, other. FNA sampling/bone biopsy has already been performed for further definition.

SPECIES

Canine

BREED

Greyhound

SEX

FS

AGE

8 Years, 3 Months

INTERPRETED BY

Sebastian Schaub, DVM
Dr. med. vet. DipECVDI

HOSPITAL NAME

South Bay Animal
Hospital

REFERRING VET

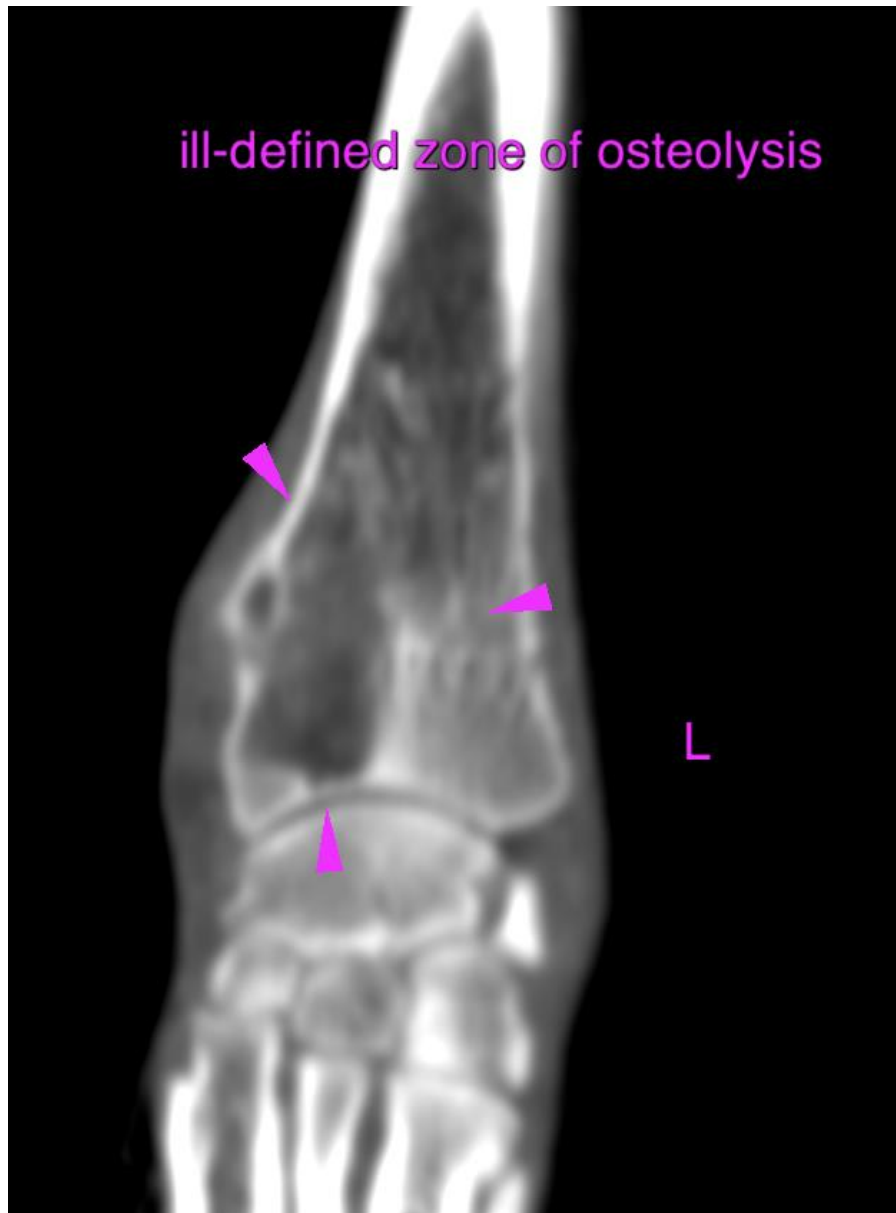Ravinder Atwal, DVM,
CCRP

INVOICE

51179

DATE

3-27-22





PATIENT

Piper Wilcox

SPECIES

Canine

BREED

Greyhound

SEX

FS

AGE

8 Years, 3 Months

INTERPRETED BY

Sebastian Schaub, DVM
Dr. med. vet. DipECVDI

HOSPITAL NAME

South Bay Animal
Hospital

REFERRING VET

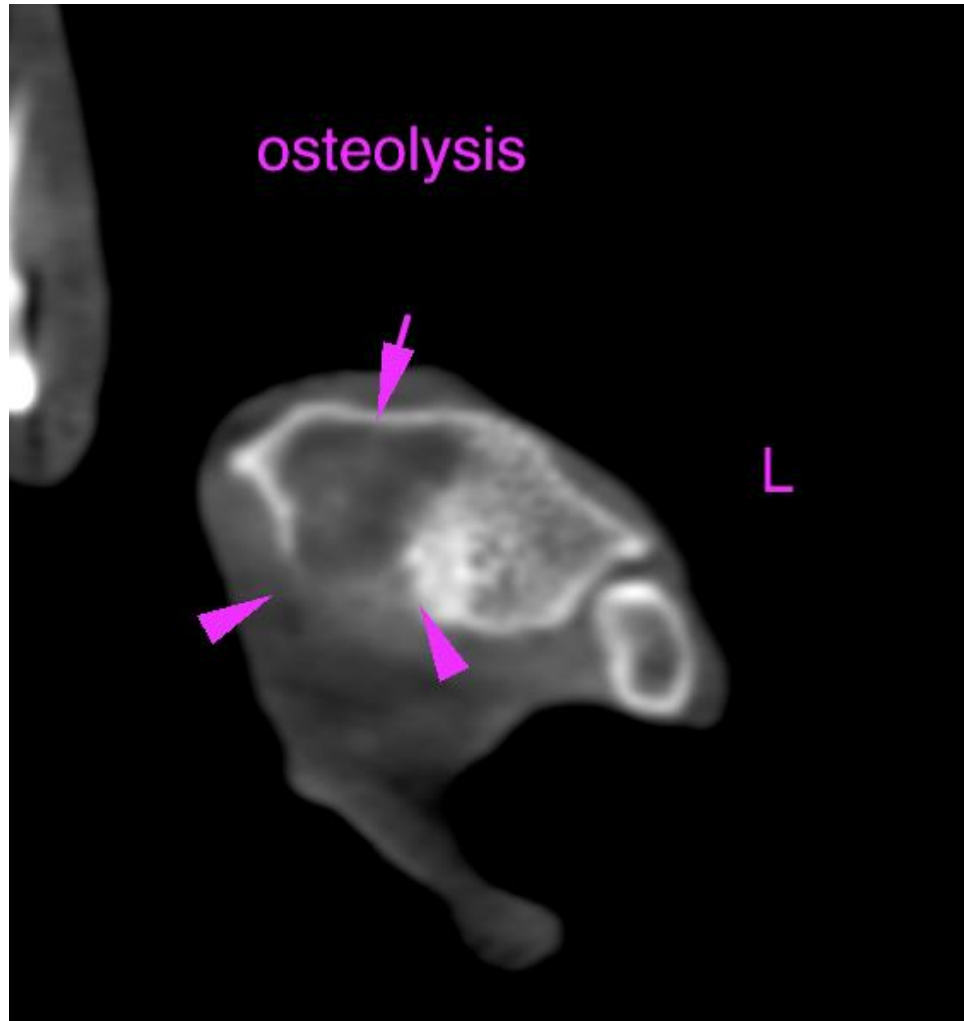
Ravinder Atwal, DVM,
CCRP

INVOICE

51179

DATE

3-27-22



The information and recommendations provided are based on the images presented by the referring veterinarian/sonographer. No evaluation can be communicated regarding pathology that was not visible in the image/video clips provided.

Thank you for this referral. If the clinical or image interpretation does not parallel your findings or if I can be of any further assistance please contact me.

Sebastian Schaub, Sebastian Schaub, DVM, Dr. med. vet. DipECVDI
sebast.schaub@gmail.com