



PATIENT

Luna Cobra

SPECIES

Canine

BREED

Retriever/Labrador

SEX

SF

AGE

8Y

WEIGHT

31.2kg

INTERPRETED BY

Sebastian Schaub, DVM
Dr. med. vet.
DipECVDI

IMAGING PERFORMED BY

Stephany R., & Maddy J.

HOSPITAL NAME

Neel Veterinary Hospital

REFERRING VET

Dr. Ellen Domnick

INVOICE

74380

DATE

3-26-26

PRESENTING CLINICAL SIGNS

- follow up from last Friday, 3.20.26.
- Pts bleeding started again 48h ago.
- plan: re-CT head & re- suture

Abnormal PE/Chem/CBC/UA Results: BW re-ran on 3.25.26 No CT Contrast was done today.

COMPUTED TOMOGRAPHY OF THE SKULL

A high resolution plain CT study of the skull is provided for review.

COMPUTED TOMOGRAPHIC FINDINGS

The pictured parts of the dentition are complete and unremarkable in all jaw quadrants.

The ramus of the left mandible – in the region of the base of the condylar process of the left mandible – brush-border like periosteal new bone formation is seen. The soft tissues medial to the ramus of the left mandible are mildly heterogeneous with a fusiform structure.

The left submandibular and left medial retropharyngeal lymph node are prominent, and the surrounding fat presents mild soft tissue striation – accentuated in the left submandibular region.

COMPUTED TOMOGRAPHIC DIAGNOSIS

- Suspect preceding surgical management of an abscess medial to the ramus of the left mandible – secondary periostitis ramus left mandible
- Lymphadenopathy left mandibular lymph nodes and left medial retropharyngeal lymph node with surrounding cellulitis

INTERPRETATION OF THE FINDINGS & FURTHER RECOMMENDATIONS

The hyperattenuating material medial to the ramus of the left mandible can present may present foreign body (possible stick) that has not been appreciated in the preceding CT or a surgical device such as a Penrose drain (but there are no gas inclusion). Depending on the performed surgery, ultrasound can be tried for specification. Check also for history of possible stick injury.



PATIENT

Luna Cobra

SPECIES

Canine

BREED

Retriever/Labrador

SEX

SF

AGE

8Y

WEIGHT

31.2kg

INTERPRETED BY

Sebastian Schaub, DVM
Dr. med. vet.
DipECVDI

IMAGING PERFORMED BY

Stephany R., & Maddy
J.

HOSPITAL NAME

Neel Veterinary
Hospital

REFERRING VET

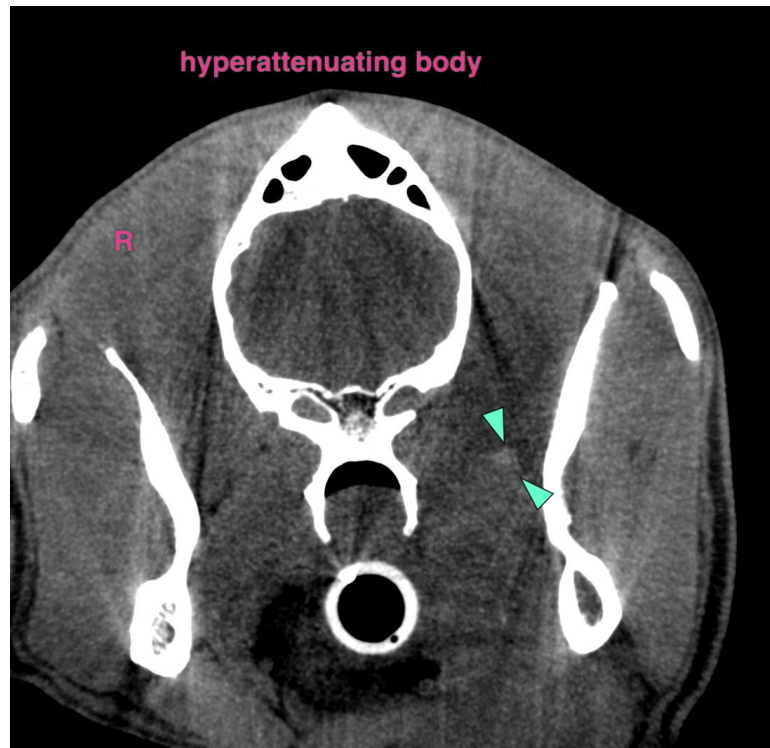
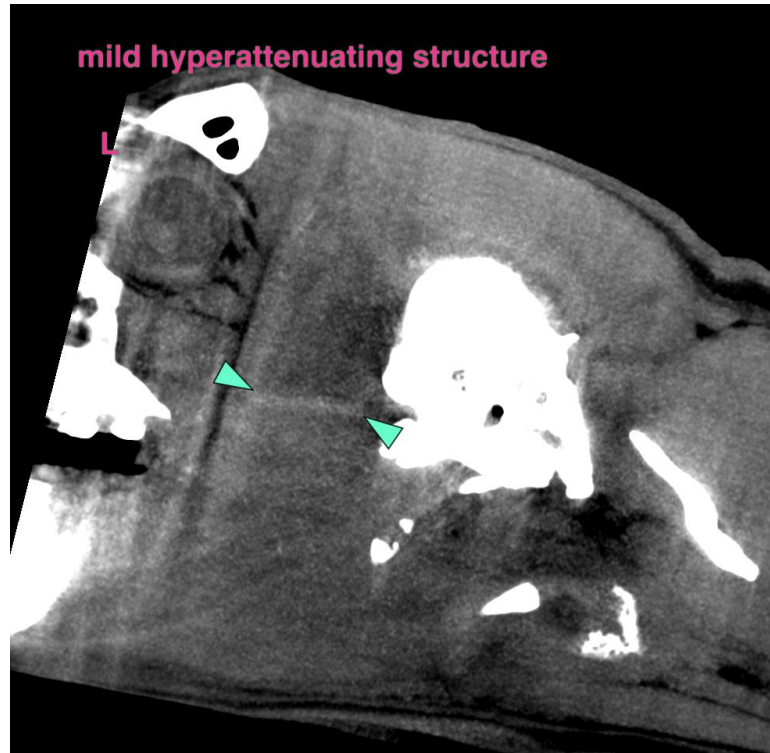
Dr. Ellen Domnick

INVOICE

74380

DATE

3-26-26





PATIENT

Luna Cobra

SPECIES

Canine

BREED

Retriever/Labrador

SEX

SF

AGE

8Y

WEIGHT

31.2kg

INTERPRETED BY

Sebastian Schaub, DVM
Dr. med. vet.
DipECVDI

IMAGING PERFORMED BY

Stephany R., & Maddy
J.

HOSPITAL NAME

Neel Veterinary
Hospital

REFERRING VET

Dr. Ellen Domnick

INVOICE

74380

DATE

3-26-26

The information and recommendations provided are based on the images presented by the referring veterinarian/sonographer. No evaluation can be communicated regarding pathology that was not visible in the image/video clips provided.

Thank you for this referral. If the clinical or image interpretation does not parallel your findings or if I can be of any further assistance please contact me.

Sebastian Schaub, Sebastian Schaub, DVM, Dr. med. vet. DipECVDI
info@sonopath.com