



PATIENT PRESENTING CLINICAL SIGNS

Taco Chou Limping

SPECIES RADIOGRAPHIC STUDY OF THE PELVIS AND STIFLE JOINTS

Canine Radiographs of the pelvis and stifle joints in orthogonal imaging planes are provided for review.

BREED RADIOGRAPHIC FINDINGS

Chihuahua The osseous and surrounding soft tissue structures of the pelvis are within normal limits. The right femoral neck presents with mild to moderate osteophyte new bone formation. The left coxofemoral joint presents smooth osseous margins. The joint space of both coxofemoral joints is congruent.

SEX Protruding from the cutaneous surface of the craniodistal aspect of the left thigh, a well-defined roundish mass is visible, measuring approximately 1.7 cm in diameter.

Male The patella of the left stifle joint is superimposed on the medial femoral condyle/soft tissues medial to the left medial femoral condyle. The left stifle joint presents with a mild to moderate intracapsular soft tissue swelling.

AGE RADIOGRAPHIC DIAGNOSIS

13

INTERPRETED BY

- Left sided articular swelling left stifle joint
- Left sided medial patellar luxation
- Cutaneous soft tissue mass craniodistal aspect left thigh
- Mild degenerative osteoarthritis right coxofemoral joints.

Sebastian Schaub, DVM
Dr. med. vet. DipECVDI

INTERPRETATION OF THE FINDINGS & FURTHER RECOMMENDATIONS

HOSPITAL NAME

Animal Paradise
Hospital

Given the age of the patient, the clinical relevance of the medial patellar luxation for the acute clinical signs is questionable. Given the joint effusion of the left stifle joint rule out pathology of the cranial cruciate ligament – check for instability (e.g. positive drawer sign/tibial compression test).

REFERRING VET

Dr. Elshafie

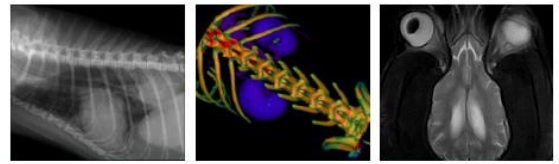
FNA sampling can be used for further definition of the cutaneous mass.

INVOICE

51171

DATE

3-26-22



PATIENT

Taco Chou

SPECIES

Canine

BREED

Chihuahua

SEX

Male

AGE

13

INTERPRETED BY

Sebastian Schaub, DVM
Dr. med. vet. DipECVDI

HOSPITAL NAME

Animal Paradise
Hospital

REFERRING VET

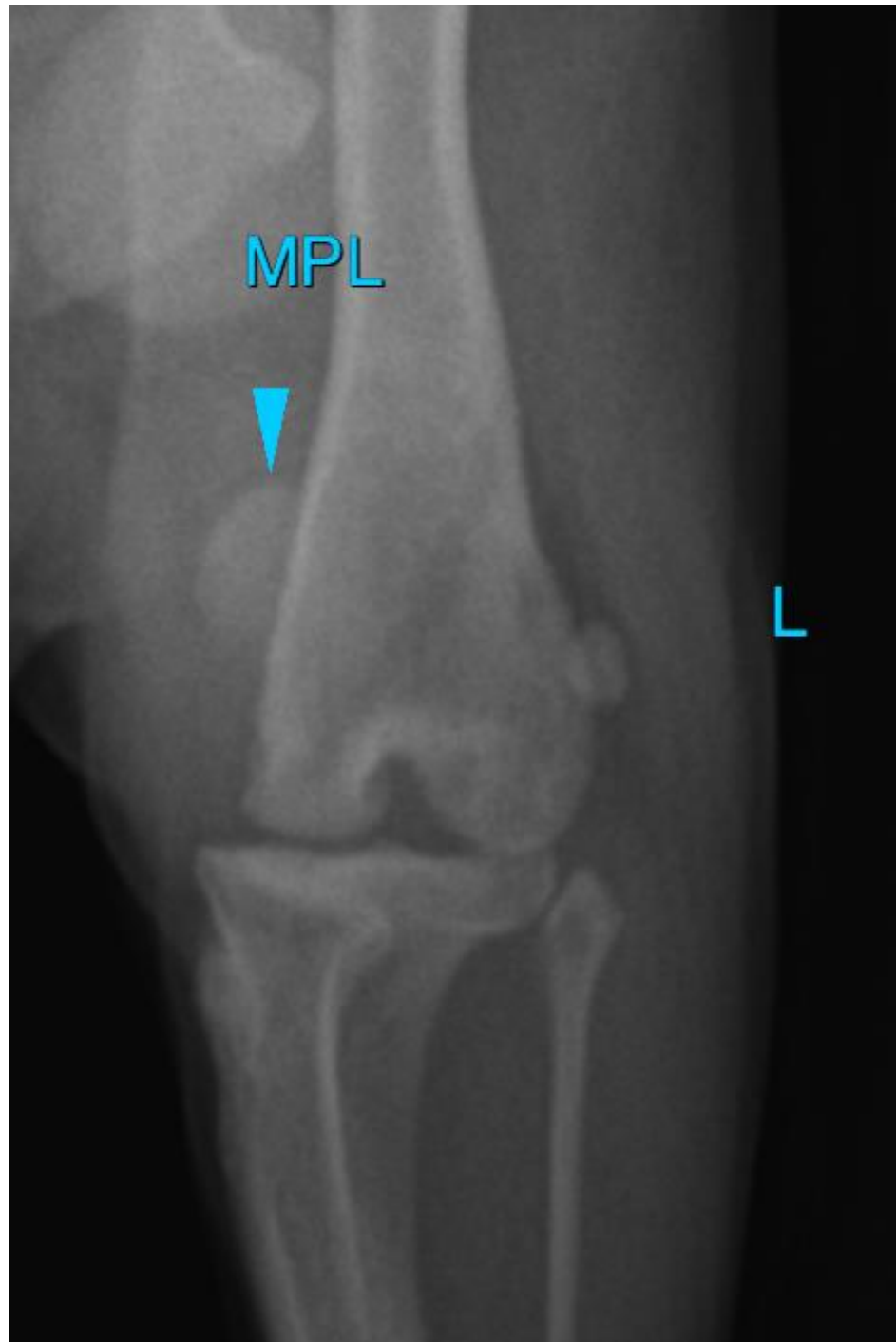
Dr. Elshafie

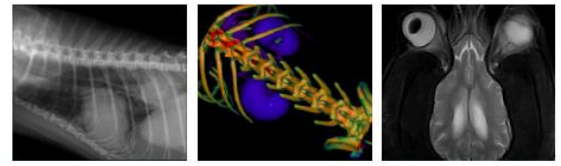
INVOICE

51171

DATE

3-26-22





PATIENT

Taco Chou

SPECIES

Canine

BREED

Chihuahua

SEX

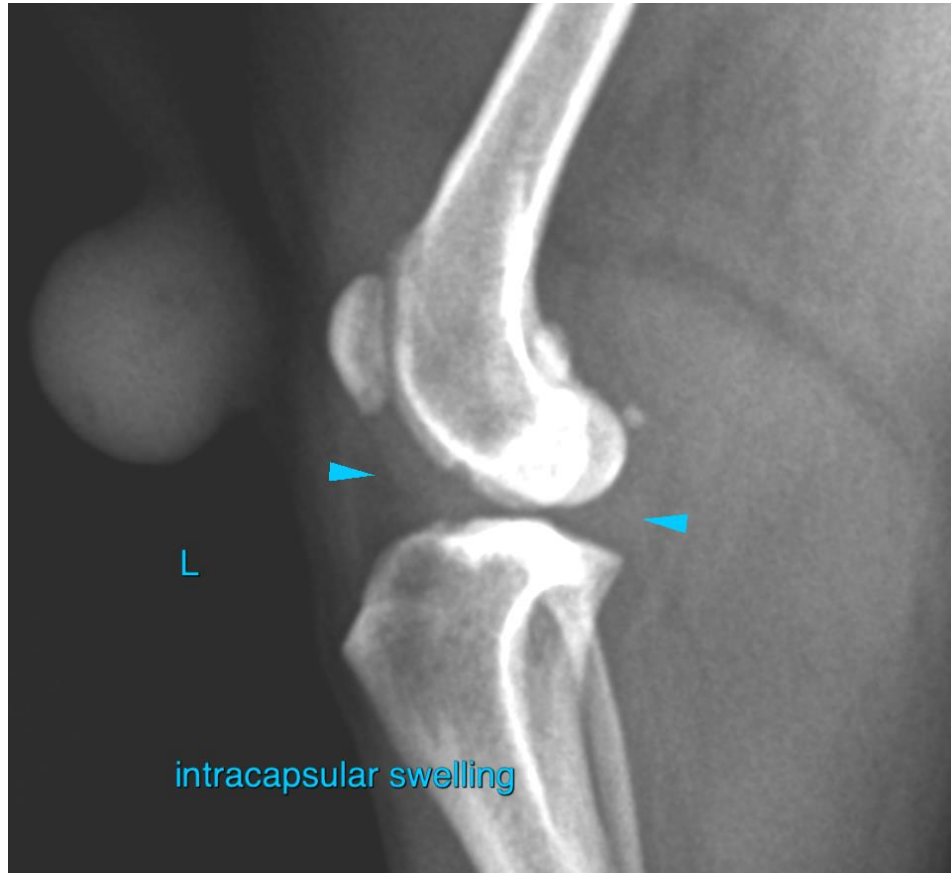
Male

AGE

13

INTERPRETED BY

Sebastian Schaub, DVM
Dr. med. vet. DipECVDI



HOSPITAL NAME

Animal Paradise
Hospital

REFERRING VET

Dr. Elshafie

INVOICE

51171

DATE

3-26-22

The information and recommendations provided are based on the images presented by the referring veterinarian/sonographer. No evaluation can be communicated regarding pathology that was not visible in the image/video clips provided.

Thank you for this referral. If the clinical or image interpretation does not parallel your findings or if I can be of any further assistance please contact me.

Sebastian Schaub, Sebastian Schaub, DVM, Dr. med. vet. DipECVDI
sebast.schaub@gmail.com