



PATIENT

Puppy "Blue Collar"
Zamora

PRESENTING CLINICAL SIGNS

Yesterday Blue's mom stepped on her leg and now she won't use it. It is the left rear.
Abnormal PE/Chem/CBC/UA Results: HOLDS LEFT HIND UP. SWELLING AND PAIN DISTAL MT AND FOOT. A BIT QUIET

SPECIES

Canine

RADIOGRAPHIC STUDY OF THE LEFT STIFLE JOINT/CRUS

Radiographs of the left crus in two orthogonal imaging planes are provided for review.

BREED

Golden Retriever Mix

RADIOGRAPHIC FINDINGS

Age related immaturity of the osseous structures is visible.

SEX

Female

A long oblique – mild spiral shaped – fracture of the proximal half of the left tibial diaphysis is present. The fracture lines are extending from a cranioproximal to caudodistal direction from the distal aspect of the tibial tuberosity up into the mid segment of the left tibial diaphysis. Very mild cranial displacement of the distal segment of the tibia is seen. The fibula is intact.

AGE

8 Weeks

RADIOGRAPHIC DIAGNOSIS

- Acute traumatic non-displaced long oblique diaphyseal fracture left tibia

INTERPRETATION OF THE FINDINGS & FURTHER RECOMMENDATIONS

The radiographic study is consistent with traumatic non-displaced long oblique fracture of the left tibia – likely stabilized by the fibula. Surgical stabilization is the preferred treatment option, however, the chances of conservative management can be discussed with orthopedic surgeon as well. In case of conservative management using external splinting, there is increased of quadriceps contracture.

INTERPRETED BY

Sebastian Schaub, DVM
Dr. med. vet. DipECVDI

HOSPITAL NAME

Elizabeth Animal
Hospital

REFERRING VET

Leon Anderson, DVM

INVOICE

51170

DATE

3-26-22



PATIENT

Puppy "Blue Collar"
Zamora

SPECIES

Canine

BREED

Golden Retriever Mix

SEX

Female

AGE

8 Weeks

INTERPRETED BY

Sebastian Schaub, DVM
Dr. med. vet. DipECVDI

HOSPITAL NAME

Elizabeth Animal
Hospital

REFERRING VET

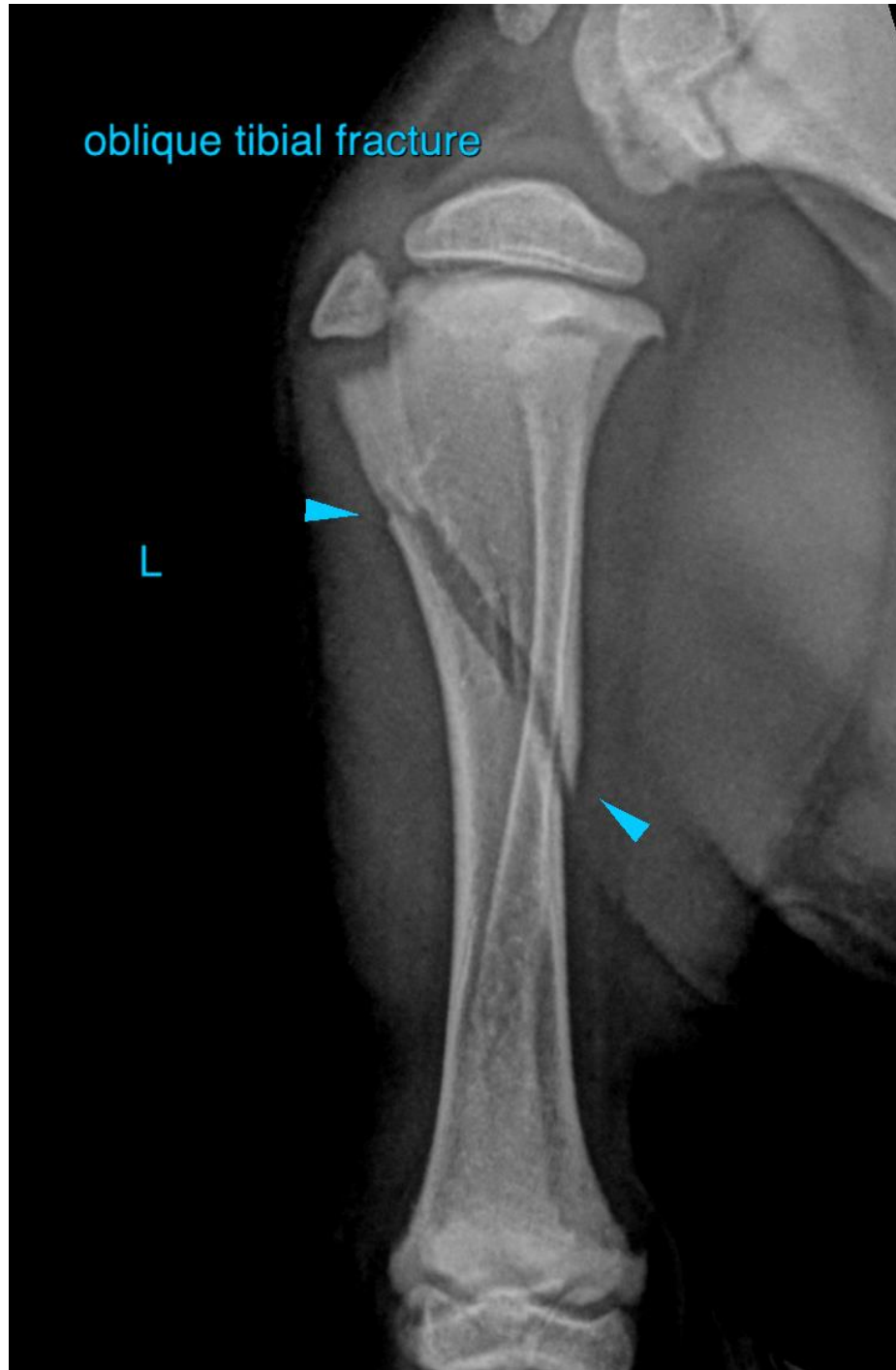
Leon Anderson, DVM

INVOICE

51170

DATE

3-26-22





PATIENT

Puppy "Blue Collar"
Zamora

The information and recommendations provided are based on the images presented by the referring veterinarian/sonographer. No evaluation can be communicated regarding pathology that was not visible in the image/video clips provided.

SPECIES

Canine

Thank you for this referral. If the clinical or image interpretation does not parallel your findings or if I can be of any further assistance please contact me.

BREED

Golden Retriever Mix

Sebastian Schaub, Sebastian Schaub, DVM, Dr. med. vet. DipECVDI
sebast.schaub@gmail.com

SEX

Female

AGE

8 Weeks

INTERPRETED BY

Sebastian Schaub, DVM
Dr. med. vet. DipECVDI

HOSPITAL NAME

Elizabeth Animal
Hospital

REFERRING VET

Leon Anderson, DVM

INVOICE

51170

DATE

3-26-22