



**PATIENT PRESENTING CLINICAL SIGNS**

Kiyomi Boggio  
Sudden onset of limping and swollen left hock Joint  
Abnormal PE/Chem/CBC/UA Results: mild dehydration

**SPECIES RADIOGRAPHIC STUDY OF THE TARSAL JOINTS**

Canine  
Radiographs of the left tarsal joint in two orthogonal imaging planes and the right tarsal joint in a dorsoplantar projection are provided for review.

**BREED RADIOGRAPHIC FINDINGS**

Labrador Retriever  
The left tarsal joint presents a moderate intracapsular soft tissue swelling. At the dorsal aspect of the tibiotarsal joint, multiple mild irregular but well-defined mineral opaque bodies, measuring up to 4 mm in size. Faint mineralization is seen in the plantaroproximal outpouching of the joint capsule of the left tibiotarsal joint. The periarticular bones of the left talocrural joint present moderate osteophyte new bone formation.

**SEX**

Female Spayed  
At the distal aspect of the right lateral malleolus, a well-defined elongated, mineralization is visible. The periarticular bones of the right tibiotarsal joint present mild osteophyte new bone formation.

**AGE**

6 Years

**RADIOGRAPHIC DIAGNOSIS**

**INTERPRETED BY**

- Advanced degenerative osteoarthritis left talocrural joint with periarticular mineralizations along the joint capsule (e.g. metaplasia, synovial osteochondromatosis)
- Moderate articular swelling left talocrural joint
- Mild degenerative osteoarthritis right talocrural joint
- Mineralized body distal aspect right malleolus

Sebastian Schaub, DVM  
Dr. med. vet. DipECVDI

**HOSPITAL NAME**

St. Catherine's Animal Hospital

**INTERPRETATION OF THE FINDINGS & FURTHER RECOMMENDATIONS**

The radiographic study is consistent with bilateral degenerative osteoarthritis of the tarsal joints, L>>R, with secondary joint effusion of the left tibiotarsal joint. Underlying causes include osteochondrosis dissecans (OCD), preceding trauma, chronic arthritis (e.g. primary inflammatory versus less likely infectious). As the changes are chronic, acute on chronic process is considered likely here. A synovial tap can be used to rule out primary inflammatory cause. A CT study of the tarsal joints can be used to rule in/out underlying OCD lesion

**REFERRING VET**

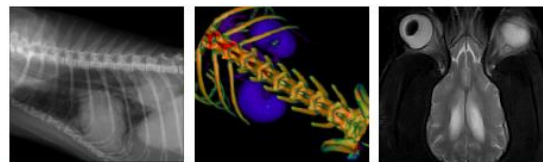
Dr. Masoud

**INVOICE**

51175

**DATE**

3-26-22



**PATIENT**

Kiyomi Boggio

**SPECIES**

Canine

**BREED**

Labrador Retriever

**SEX**

Female Spayed

**AGE**

6 Years

**INTERPRETED BY**

Sebastian Schaub, DVM  
Dr. med. vet. DipECVDI

**HOSPITAL NAME**

St. Catherine's Animal  
Hospital

**REFERRING VET**

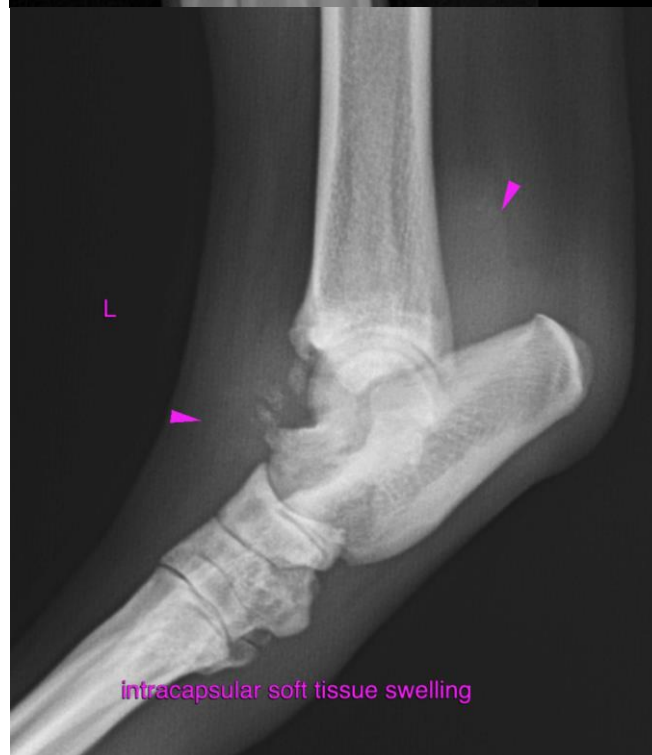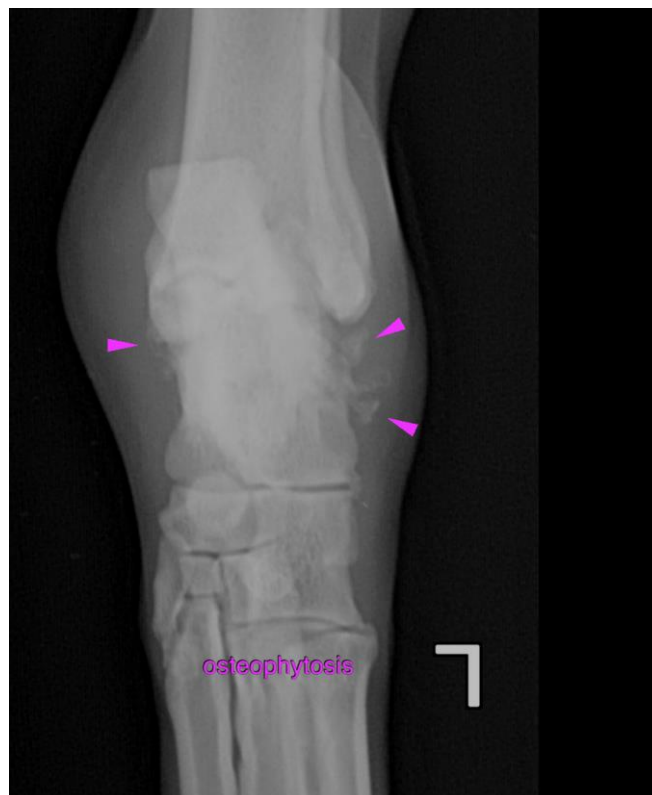Dr. Masoud

**INVOICE**

51175

**DATE**

3-26-22





**PATIENT**

Kiyomi Boggio

**SPECIES**

Canine

**BREED**

Labrador Retriever

**SEX**

Female Spayed

**AGE**

6 Years

**INTERPRETED BY**

Sebastian Schaub, DVM  
Dr. med. vet. DipECVDI

**HOSPITAL NAME**

St. Catherine's Animal  
Hospital

**REFERRING VET**

Dr. Masoud

**INVOICE**

51175

**DATE**

3-26-22

The information and recommendations provided are based on the images presented by the referring veterinarian/sonographer. No evaluation can be communicated regarding pathology that was not visible in the image/video clips provided.

Thank you for this referral. If the clinical or image interpretation does not parallel your findings or if I can be of any further assistance please contact me.

**Sebastian Schaub**, Sebastian Schaub, DVM, Dr. med. vet. DipECVDI  
sebast.schaub@gmail.com