



PATIENT

Gigi Bowers

PRESENTING CLINICAL SIGNS

LHL lameness issue first noted August 2021; radiographs submitted at that time (invoice #46827). Recent flare-up of issues, still with LHL. Significant cranial drawer motion with left stifle now present. Any concerns with hips as well? Other changes?

SPECIES

Canine

RADIOGRAPHIC STUDY OF THE STIFLE JOINTS

Radiographs of both stifle joints in two orthogonal imaging planes are provided for review.

BREED

Westie

RADIOGRAPHIC FINDINGS

The periarticular bones of both stifle joints present mild to moderate osteophyte new bone formation, L>R. Both stifle joints present a moderate intracapsular soft tissue swelling, effacing the infrapatellar fat pad cranially and distorting the fascial plane caudally. Bilaterally, moderate cranial subluxation of the tibial plateau is visible. The patella bilaterally is in situ.

SEX

Female

The medial fabella is in a relative distal position bilaterally.

RADIOGRAPHIC DIAGNOSIS

AGE

8

- Mild to moderate degenerative osteoarthritis stifle joints bilaterally
- Moderate articular swelling stifle joints bilaterally
- Bilateral cranial tibial subluxation
- Bilateral distal position of medial fabella – considered as normal anatomical variant

INTERPRETED BY

Sebastian Schaub, DVM
Dr. med. vet. DipECVDI

INTERPRETATION OF THE FINDINGS & FURTHER RECOMMENDATIONS

The radiographic study is consistent with bilateral mild chronic degenerative osteoarthritis with concomitant joint effusion of both stifle joints. The cranial tibial subluxation indicates bilateral failure of the cranial cruciate ligament ± meniscal pathology.

HOSPITAL NAME

Gentle Doctor Animal
Hospital

A positive drawer sign or tibial compression test under general anesthesia can be used to confirm the diagnosis and surgical intervention of the clinically more conspicuous left stifle joint is recommended. Surgical intervention of the right stifle joint may be considered as well after the post-operative rehabilitation phase.

REFERRING VET

Miranda Thomassen

INVOICE

51169

DATE

3-26-22



PATIENT

Gigi Bowers

SPECIES

Canine

BREED

Westie

SEX

Female

AGE

8

INTERPRETED BY

Sebastian Schaub, DVM
Dr. med. vet. DipECVDI

HOSPITAL NAME

Gentle Doctor Animal
Hospital

REFERRING VET

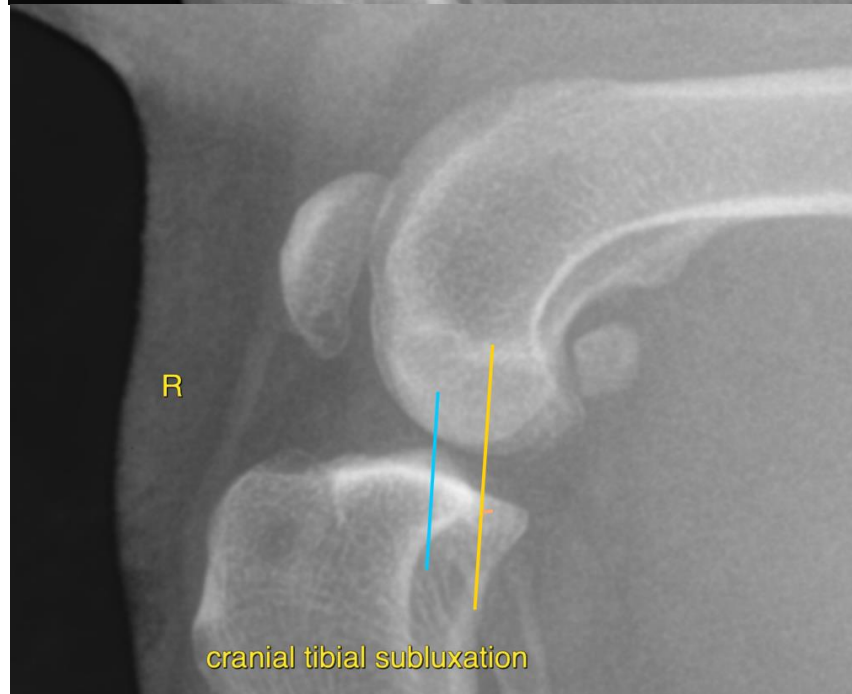
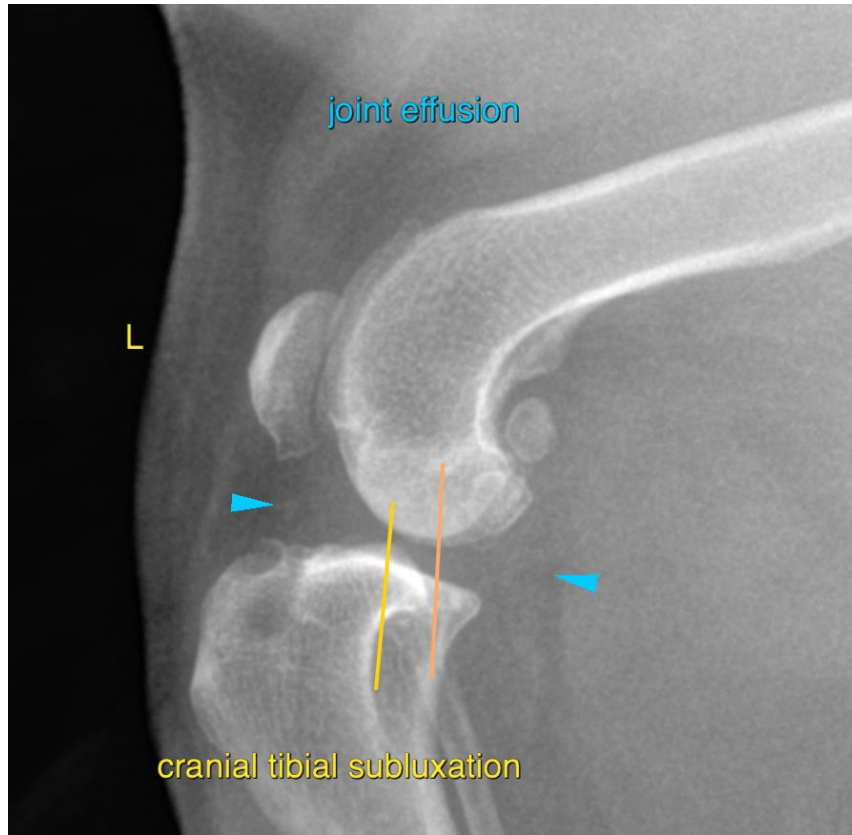
Miranda Thomassen

INVOICE

51169

DATE

3-26-22





PATIENT

Gigi Bowers

SPECIES

Canine

The information and recommendations provided are based on the images presented by the referring veterinarian/sonographer. No evaluation can be communicated regarding pathology that was not visible in the image/video clips provided.

BREED

Westie

Thank you for this referral. If the clinical or image interpretation does not parallel your findings or if I can be of any further assistance please contact me.

SEX

Female

Sebastian Schaub, Sebastian Schaub, DVM, Dr. med. vet. DipECVDI
sebast.schaub@gmail.com

AGE

8

INTERPRETED BY

Sebastian Schaub, DVM
Dr. med. vet. DipECVDI

HOSPITAL NAME

Gentle Doctor Animal
Hospital

REFERRING VET

Miranda Thomassen

INVOICE

51169

DATE

3-26-22