



PATIENT PRESENTING CLINICAL SIGNS

Duncan Bigham
 Cervical mucocele following trauma to the left mandibular salivary gland in early January 2022. Sialadenectomy of the mandibular and monostomatic sublingual salivary glands performed 2/24/22. Recurrent swelling noted several weeks later following initial improvement.
 Abnormal PE/Chem/CBC/UA Results: pronounced cervical and left mandibular swelling

SPECIES

Canine

COMPUTED TOMOGRAPHY OF THE SKULL

A high resolution pre- and post-contrast CT study of the skull is provided for review.

BREED

Mixed

COMPUTED TOMOGRAPHIC FINDINGS

Multiple teeth are absent.

SEX

The left tonsil is moderately enlarged and presents as a pedunculated mass, bulging into the oropharynx.

MN

The nasal cavity presents the expected aerated spaces between thin & even conchae and turbinates with smooth mucosal lining.

AGE

Both temporomandibular joints present congruent joint spaces with even subchondral bone surfaces and are considered within normal limits.

10 Years, 10 Months

INTERPRETED BY

Sebastian Schaub, DVM
 Dr. med. vet. DipECVDI

Both tympanic bullae are aerated, the mucosal lining is not seen, the bony wall is smooth and thin. The external ear canals are within normal limits.

The brain presents no deviation from normal anatomy and symmetry. The brain parenchyma is homogeneous and within normal limits for attenuation and distribution of contrast enhancement. The ventricular system is non-dilated and symmetric.

HOSPITAL NAME

Healing Spirit Animal
 Wellness

In the region of the left medial retropharyngeal lymph node, an ill-defined, uniform soft tissue attenuating and heterogeneous contrast enhancing mass is visible, measuring approximately 9.2 x 6.0 x 7.5 cm in size. The larynx and left common carotid artery are displaced to the right by the mass effect. In the dorsal aspect the mass is extending up to the left mastoid process/ventral aspect of the left tympanic bulla.

REFERRING VET

Sarah Green

The left mandibular lymph nodes are prominent, the short-to-long-axis ratio is maintained normal, <0.5.

The left mandibular salivary gland is absent.

INVOICE

51173

COMPUTED TOMOGRAPHIC DIAGNOSIS

DATE

3-26-22

- Enlarged left tonsil
- Left retropharyngeal soft tissue mass
- Lymphadenopathy left mandibular lymph nodes
- History of surgical excision of the left mandibular & sublingual monostomatic salivary gland



PATIENT

Duncan Bigham

SPECIES

Canine

BREED

Mixed

SEX

MN

AGE

10 Years, 10 Months

INTERPRETED BY

Sebastian Schaub, DVM
Dr. med. vet. DipECVDI

HOSPITAL NAME

Healing Spirit Animal
Wellness

REFERRING VET

Sarah Green

INVOICE

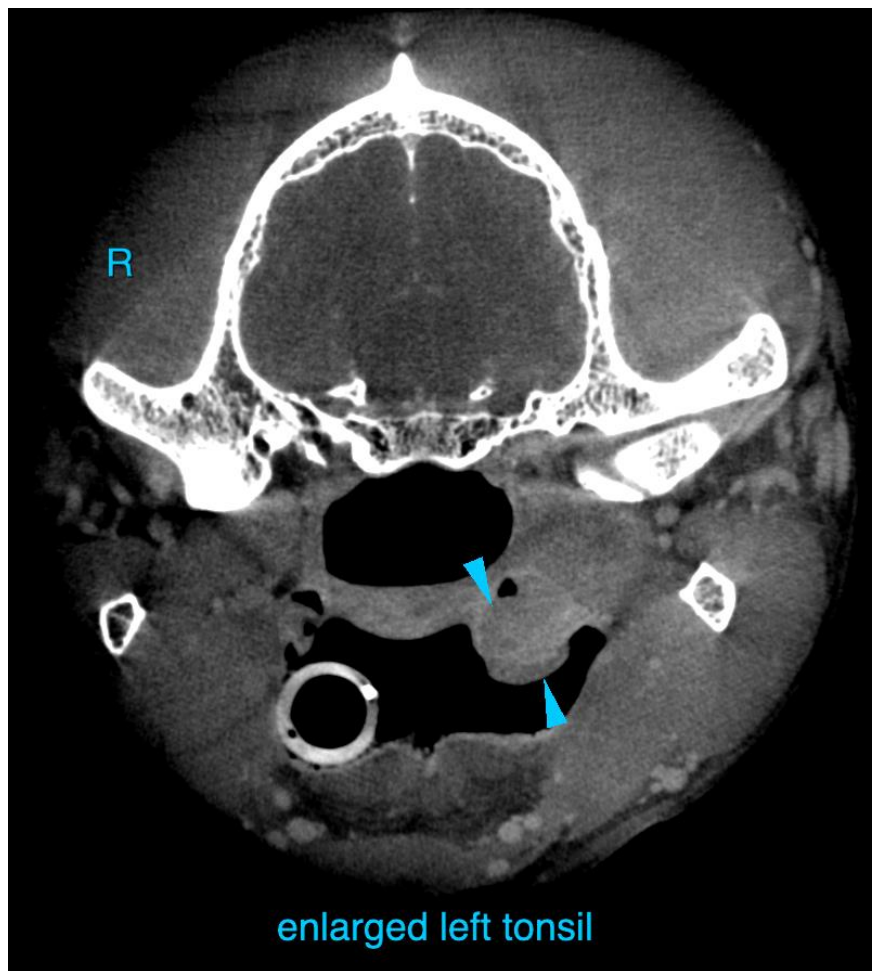
51173

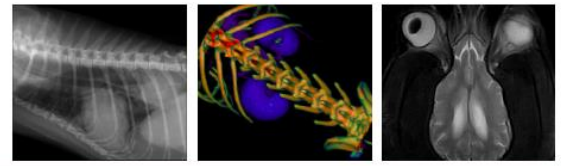
DATE

3-26-22

INTERPRETATION OF THE FINDINGS & FURTHER RECOMMENDATIONS

In combination with the mass originating from the left tonsil, the findings are concerning for neoplastic transformation of the left tonsil and possibly the left medial retropharyngeal lymph node. Squamous cell carcinoma, lymphosarcoma or melanoma are the top differentials. If not done so yet, excision biopsy of the left tonsil and FNA sampling of the large left retropharyngeal mass are recommended for further definition. Complete surgical excision of the retropharyngeal mass appears not feasible due potential local invasive growth.





PATIENT

Duncan Bigham

SPECIES

Canine

BREED

Mixed

SEX

MN

AGE

10 Years, 10 Months

INTERPRETED BY

Sebastian Schaub, DVM
Dr. med. vet. DipECVDI

HOSPITAL NAME

Healing Spirit Animal
Wellness

REFERRING VET

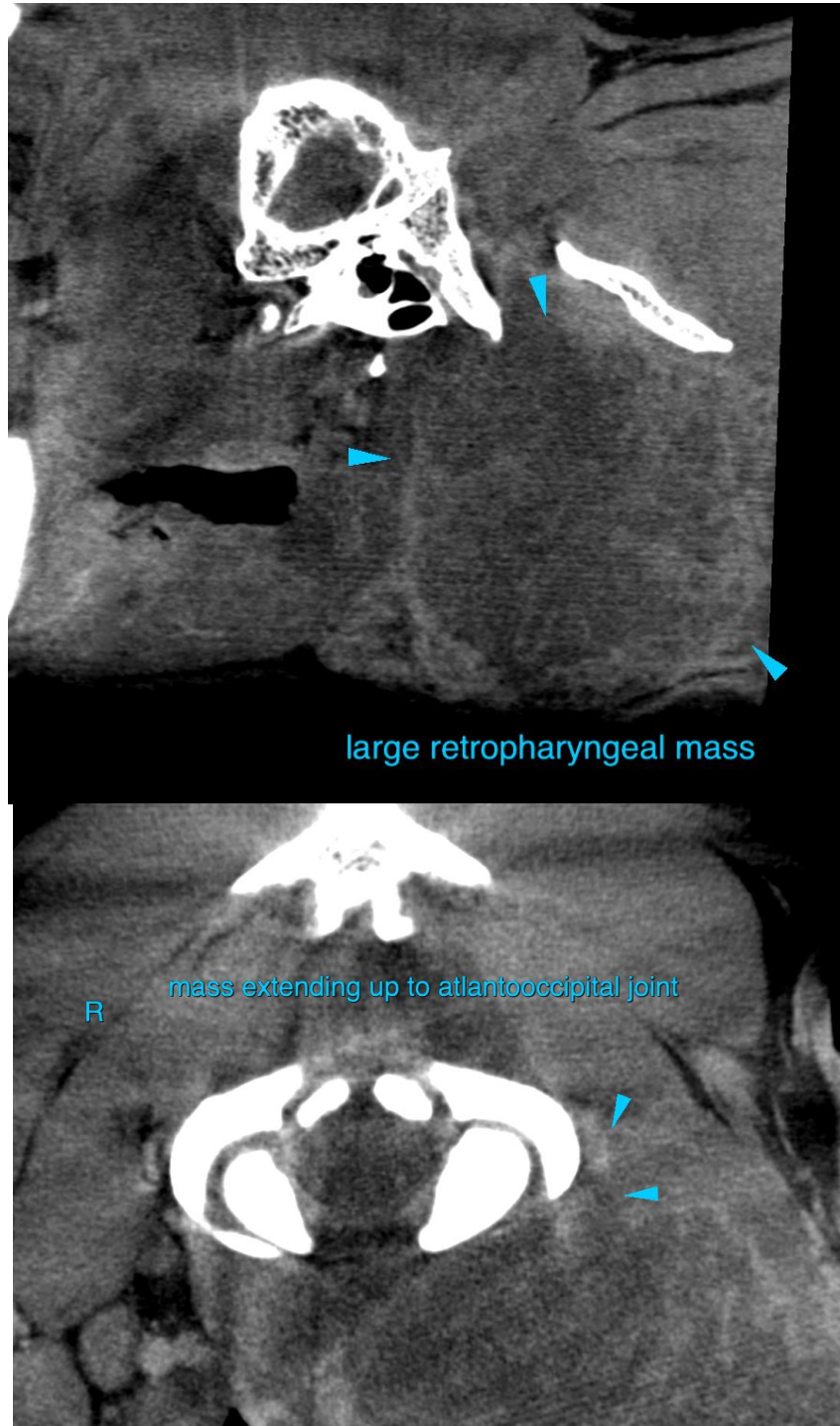
Sarah Green

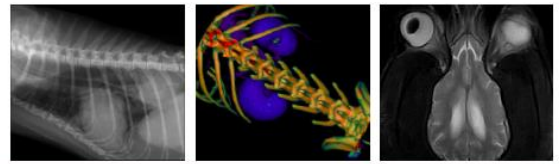
INVOICE

51173

DATE

3-26-22





PATIENT

Duncan Bigham

The information and recommendations provided are based on the images presented by the referring veterinarian/sonographer. No evaluation can be communicated regarding pathology that was not visible in the image/video clips provided.

SPECIES

Canine

Thank you for this referral. If the clinical or image interpretation does not parallel your findings or if I can be of any further assistance please contact me.

BREED

Mixed

Sebastian Schaub, Sebastian Schaub, DVM, Dr. med. vet. DipECVDI
sebast.schaub@gmail.com

SEX

MN

AGE

10 Years, 10 Months

INTERPRETED BY

Sebastian Schaub, DVM
Dr. med. vet. DipECVDI

HOSPITAL NAME

Healing Spirit Animal
Wellness

REFERRING VET

Sarah Green

INVOICE

51173

DATE

3-26-22