



PATIENT

Bella Marin

PRESENTING CLINICAL SIGNS

P is here to check on weird behavior, when P gets excited it will start shaking and losing balance on the front paws. r/o IVDD r/o collapsing trachea r/o other
Abnormal PE/Chem/CBC/UA Results: CBC- WNL Diag- Glob 2.2 T4- 2.5

SPECIES

Canine

RADIOGRAPHIC STUDY OF THE THORAX & ABDOMEN

A complete set of radiographs of the thorax and abdomen is provided for review.

BREED

Mixed Yorkshire Terrier

RADIOGRAPHIC FINDINGS

Thorax

Multifocal mild spondylosis formation is seen along the thoracic spine. Both shoulder joints present pointed caudal margins.

SEX

Female

The extrathoracic soft tissues present homogeneous without abnormalities.

The heart is of normal size and shape, there is no evidence of cardiac chamber or vascular enlargement. The pulmonary vasculature is within normal limits.

AGE

11 Years

The cranial mediastinum presents the expected soft tissue opacity. The mediastinal width is less than twice the width of the vertebral column at the same level.

INTERPRETED BY

Sebastian Schaub, DVM
Dr. med. vet. DipECVDI

A soft tissue membrane is mildly protruding into the lumen of the cervical tracheal segment. The trachea is normal in diameter and presents the anticipated course. The luminal outline of the trachea is smooth.

The bronchial tree presents with thin walls and tapers uniformly towards the periphery as expected.

HOSPITAL NAME

Animal Paradise Hospital

The lung parenchyma presents the expected architecture and opacity; the intrapulmonary vascular branching is seen up to the third order lung vessels.

The diaphragm is well delineated with even surface and the expected mild cranial bulging of the diaphragmatic cupola.

REFERRING VET

Dr. Kristen Hellwarth

Abdomen

The left coxofemoral joint presents moderate osteophyte new bone formation.

INVOICE

51172

No abnormalities of the extraabdominal soft tissues are noted. The abdominal wall is smooth and thin.

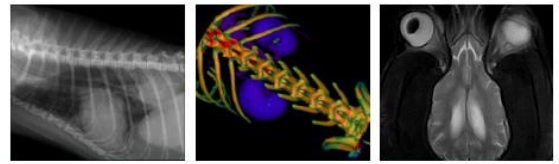
The serosal detail is maintained throughout the peritoneal and retroperitoneal space.

DATE

3-26-22

The hepatic volume is mild to moderately increased and the caudoventral margins are rounded.

The splenic head is in the anticipated position and within normal limits for size and opacity. The splenic body and tail are considered normal for position, size, shape and opacity.



PATIENT

Bella Marin

Both kidneys are seen and present with normal size, shape, delineation and opacity. The urinary bladder is in its anticipated position. No radiopaque calculi are noted throughout the upper and lower urinary tract.

The stomach is in its anticipated position and presents normal content.

SPECIES

Canine

The small intestinal loops are of even diameter and non-dilated, a small amount of gas is seen within the small intestinal loops and considered within normal limits.

The colon is seen in the expected position and presents with appropriate content.

BREED

Mixed Yorkshire
Terrier

RADIOGRAPHIC DIAGNOSIS

- Hepatomegaly
- Redundant tracheal membrane
- Degenerative osteoarthritis shoulder joints bilaterally
- Degenerative osteoarthritis right coxofemoral joint
- Spondylosis deformans

SEX

Female

INTERPRETATION OF THE FINDINGS & FURTHER RECOMMENDATIONS

AGE

11 Years

Potentials for the hepatomegaly include metabolic hepatic disease/steroid induced hepatopathy, hepatitis or neoplastic infiltration. Ultrasound including FNA sampling can be used as minimally advanced diagnostic tests.

INTERPRETED BY

Sebastian Schaub, DVM
Dr. med. vet. DipECVDI

The redundant tracheal membrane is considered incidental at this point but might be a precursor for tracheal collapse.

No additional clinically relevant abnormalities are appreciated.

HOSPITAL NAME

Animal Paradise
Hospital

REFERRING VET

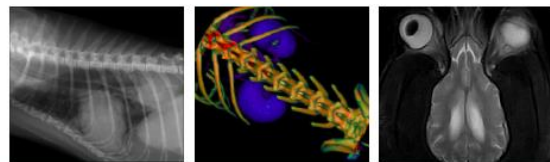
Dr. Kristen Hellwarth

INVOICE

51172

DATE

3-26-22



PATIENT

Bella Marin

SPECIES

Canine

BREED

Mixed Yorkshire
Terrier

SEX

Female

AGE

11 Years

INTERPRETED BY

Sebastian Schaub, DVM
Dr. med. vet. DipECVDI

HOSPITAL NAME

Animal Paradise
Hospital

REFERRING VET

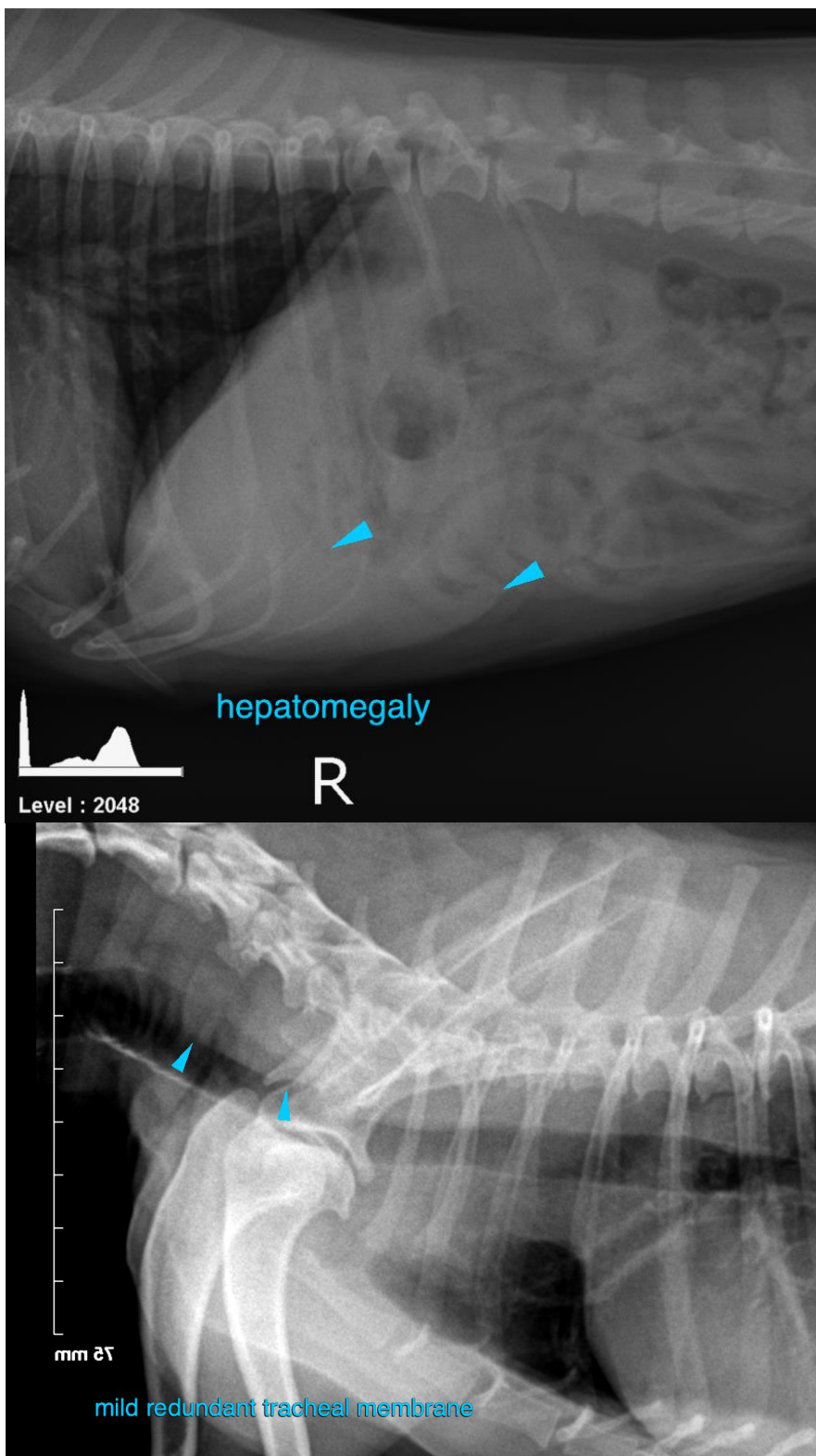
Dr. Kristen Hellwarth

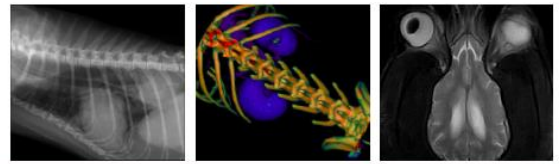
INVOICE

51172

DATE

3-26-22





PATIENT

Bella Marin

SPECIES

Canine

The information and recommendations provided are based on the images presented by the referring veterinarian/sonographer. No evaluation can be communicated regarding pathology that was not visible in the image/video clips provided.

BREED

Mixed Yorkshire
Terrier

Thank you for this referral. If the clinical or image interpretation does not parallel your findings or if I can be of any further assistance please contact me.

Sebastian Schaub, Sebastian Schaub, DVM, Dr. med. vet. DipECVDI
sebast.schaub@gmail.com

SEX

Female

AGE

11 Years

INTERPRETED BY

Sebastian Schaub, DVM
Dr. med. vet. DipECVDI

HOSPITAL NAME

Animal Paradise
Hospital

REFERRING VET

Dr. Kristen Hellwarth

INVOICE

51172

DATE

3-26-22