



PATIENT PRESENTING CLINICAL SIGNS

PATIENT Stella Gardner **PRESENTING CLINICAL SIGNS** Recent internal medicine consult and abdominal ultrasound due to urinary incontinence. Report attached

SPECIES COMPUTED TOMOGRAPHY OF THE ABDOMEN

SPECIES Canine **COMPUTED TOMOGRAPHY OF THE ABDOMEN** A high resolution pre- and post-contrast CT study of the abdomen is provided for review.

COMPUTED TOMOGRAPHIC FINDINGS

BREED

Mixed

The serosal fat presents normal attenuation behavior. There is no evidence of peritoneal effusion or peritonitis.

SEX

Spayed Female

Both kidneys present within normal limits for size, shape and organ architecture. After contrast administration a bilaterally symmetric and uniform nephro- and pyelogram is noted. The renal pelvis bilaterally is mildly dilated, measuring up to 3.9 mm in height. Both ureters are mildly prominent, measuring up to 2.1 mm in diameter. The right ureteral orifice is approximately 3.5 cm cranial to the urinary bladder neck and the left ureteral orifice is appreciated 2.9 cm cranial to the urinary bladder neck. No contrast is seen in the urinary bladder neck/urethra in all post contrast studies.

AGE

2 Years, 3 Months

No mineral attenuating material is seen throughout the upper and lower urinary tract.

The adrenal glands are within normal limits for size, shape and organ architecture.

INTERPRETED BY

Sebastian Schaub, DVM
Dr. med. vet. DipECVDI

Both liver and spleen present with normal shape, even surface, uniformly attenuating parenchyma and homogeneous contrast enhancement, unremarkable.

The portal vein presents a normal order of its tributary veins and intrahepatic branching. No abnormal vessel is noted inside and outside of the liver parenchyma.

HOSPITAL NAME

Mobile Pet Imaging

The pancreas is evenly contoured, the pancreatic parenchyma is homogeneous and presents uniform contrast enhancement.

The position, delineation, wall and content of the gastrointestinal tract are considered within normal limits throughout.

REFERRING VET

Meaux

The bony and surrounding soft tissue structures reveal no abnormalities.

COMPUTED TOMOGRAPHIC DIAGNOSIS

INVOICE

51155

- Very mild ureteral dilation bilaterally, L>R
- Very mild pyelectasis bilaterally, R>L
- No evidence of ureteral ectopia
- No mineral attenuating material is noted throughout the urinary tract.

DATE

3-25-22



PATIENT INTERPRETATION OF THE FINDINGS & FURTHER RECOMMENDATIONS

PATIENT Stella Gardner
 The CT is negative for ureteral ectopia. In case of strong clinical suspicion further workup by means of cystoscopy should be considered. Other underlying causes – such as urethrocele, urinary bladder/lower sphincter dyssynergia, behavioral problems, PU/PD – need to be considered as well.

SPECIES Canine
 The mild pyelectasis and ureteral dilation might be a sequela to polyuria, increased outflow resistance or inflammation.

BREED Mixed
 Also note that dogs that are spayed early at an age of < 3 months are known to have an incidence of incontinence of 12 % and dogs spayed at an age > 3 months of 5%*. Consider a therapy with ephedrine as first choice medication if underlying lower urinary tract infection can be ruled out.

SEX Spayed Female
 *Resources:
 Spain, C. Victor, Janet M. Scarlett, and Katherine A. Houpt. "Long-term risks and benefits of early-age gonadectomy in dogs." Journal of the American Veterinary Medical Association 224.3 (2004): 380-387.

AGE

2 Years, 3 Months

INTERPRETED BY

Sebastian Schaub, DVM
 Dr. med. vet. DipECVDI

HOSPITAL NAME

Mobile Pet Imaging

REFERRING VET

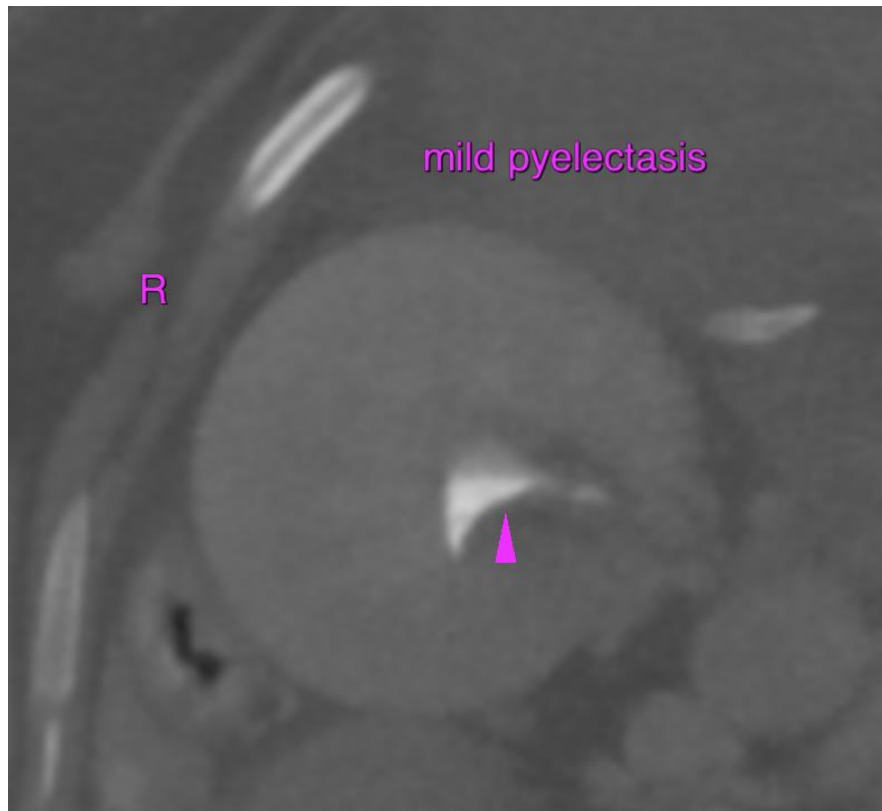
Meaux

INVOICE

51155

DATE

3-25-22





PATIENT

Stella Gardner

SPECIES

Canine

BREED

Mixed

SEX

Spayed Female

AGE

2 Years, 3 Months

INTERPRETED BY

Sebastian Schaub, DVM
Dr. med. vet. DipECVDI

HOSPITAL NAME

Mobile Pet Imaging

REFERRING VET

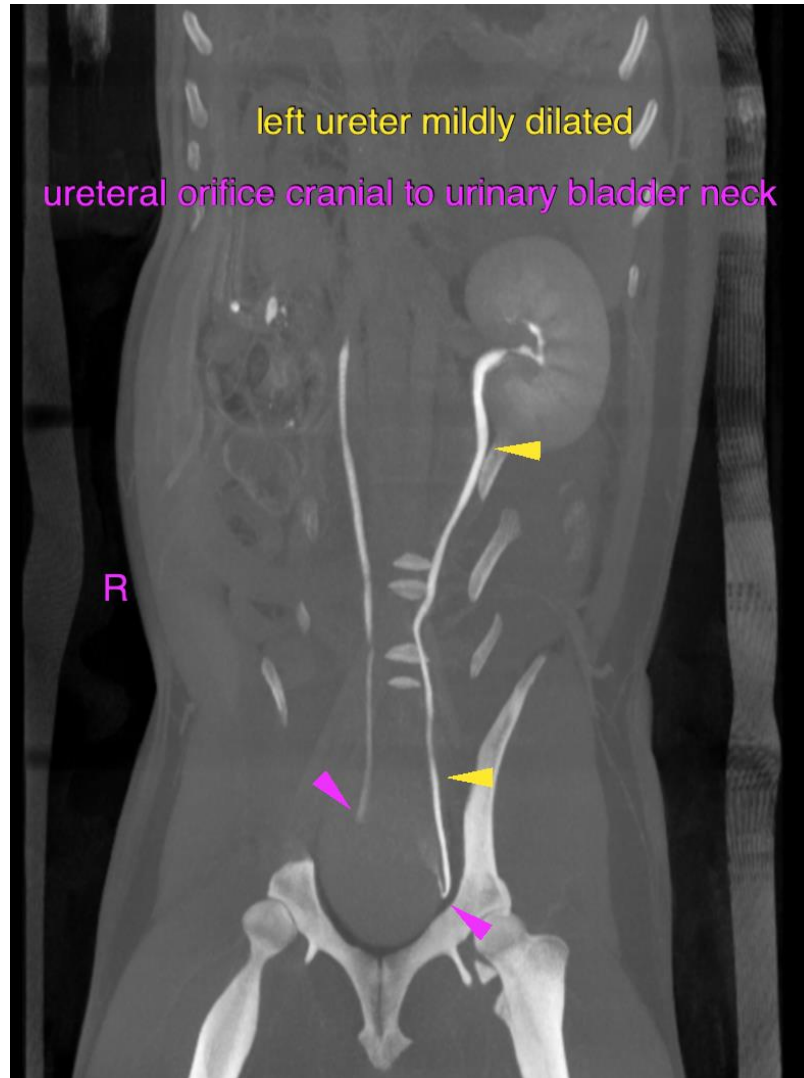
Meaux

INVOICE

51155

DATE

3-25-22



The information and recommendations provided are based on the images presented by the referring veterinarian/sonographer. No evaluation can be communicated regarding pathology that was not visible in the image/video clips provided.

Thank you for this referral. If the clinical or image interpretation does not parallel your findings or if I can be of any further assistance please contact me.

Sebastian Schaub, Sebastian Schaub, DVM, Dr. med. vet. DipECVDI
sebast.schaub@gmail.com