



PATIENT PRESENTING CLINICAL SIGNS

PATIENT Rocky Smith History: 2 view thoracic radiographs submitted for comparison with previous study performed on 3/3/22 (previous report with Sonopath was on 3/3/22) Rocky did a 10-day course of Clavamox starting on 3/10/22.

SPECIES Abnormal PE/Chem/CBC/UA Results:

Feline RADIOGRAPHIC STUDY OF THE THORAX

Radiographs of the thorax in two imaging planes are provided for review.

BREED RADIOGRAPHIC FINDINGS

DLH

SEX

The multifocal pulmonary nodules are stationary in size and position. The included cranial aspect of the thorax – was cropped by the collimation in the previous radiographic study – a well-defined bean shaped soft tissue opaque structured, measuring approximately one intercostal space in size is visible. Stationary multifocal moderate peribronchial cuffing is noted.

Neutered Male

RADIOGRAPHIC DIAGNOSIS

AGE

- Stationary structured nodular interstitial lung pattern and elongated soft tissue opaque mass like lesion cranial lung field
- Bronchial lung pattern – stationary

14 Years 8 Months

INTERPRETATION OF THE FINDINGS & FURTHER RECOMMENDATIONS

INTERPRETED BY

Sebastian Schaub,
DVM Dr. med. vet.
DipECVDI

The radiographic pattern is stationary in comparison to the preceding radiographic study. Unfortunately, the nodules are still not specific, but I would consider the odds for inflammatory lesions/mucus impaction of multiple bronchi higher than for neoplastic transformation. A CT study or follow up radiographs in approximately 1-2 month can be used to monitor the nodular lesions.

HOSPITAL NAME

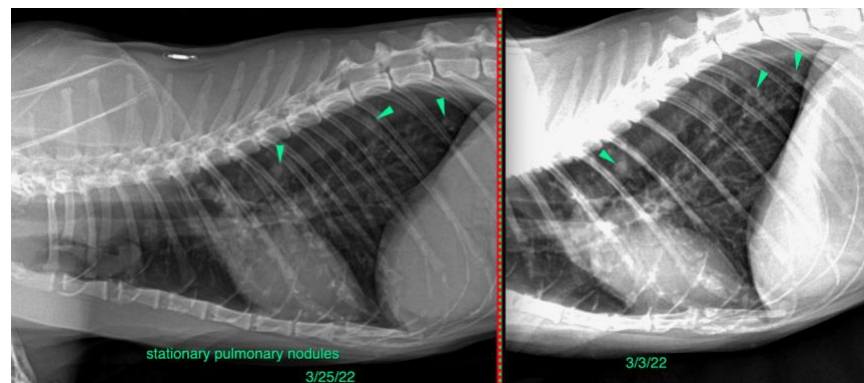
Tahoe Integrative VC

REFERRING VET

Dr. Wendy Robinson

INVOICE

14532



DATE

3/25/22



PATIENT

Rocky Smith

The information and recommendations provided are based on the images presented by the referring veterinarian/sonographer. No evaluation can be communicated regarding pathology that was not visible in the image/video clips provided.

SPECIES

Feline

Thank you for this referral. If the clinical or image interpretation does not parallel your findings or if I can be of any further assistance please contact me.

Sebastian Schaub, Sebastian Schaub, DVM, Dr. med. vet. DipECVDI
sebast.schaub@gmail.com

BREED

DLH

SEX

Neutered Male

AGE

14 Years 8 Months

INTERPRETED BY

Sebastian Schaub,
DVM Dr. med. vet.
DipECVDI

HOSPITAL NAME

Tahoe Integrative VC

REFERRING VET

Dr. Wendy Robinson

INVOICE

14532

DATE

3/25/22