SonoPath Teleradiology

EDUCATIONAL TELECONSULTATION SERVICES™

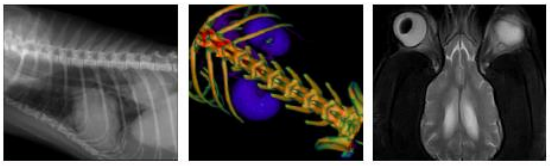

SonoPath.com
1-800-838-4268 info@sonopath.com

PATIENT

Luna Mottmann

SPECIES

Canine

BREED

Bulldog Mix

SEX

Fe

AGE

6 Months

INTERPRETED BY

Sebastian Schaub, DVM
Dr. med. vet. DipECVDI

HOSPITAL NAME

DPC Veterinary Hospital

REFERRING VET

Dr. Rivera

INVOICE

51158

DATE

3-25-22

PRESENTING CLINICAL SIGNS

Reason for Visit: Ears, LH History: P presents for ears and inflamed left hock. O states he noticed LH (hock area) was much larger than the right about 2 weeks ago. 3-4 days later P began favoring leg, while going up and down the stairs. No trauma occured per O. No pain noted either Abnormal PE/Chem/CBC/UA Results: CV/Respiratory: Normal heart rate and rhythm, no murmur, pulses strong and synchronous, normal bronchovesicular sounds. Panting!!! EENT: Clear OU. AU:mild to moderate brown exudate (AD>>AS), mild erythema, no swelling present, TM WNL. No nasal discharge. No cough on tracheal palpation. Oral cavity: N Musculoskeletal: BCS = 5/9. Ambulatory x 4. L hock: moderate firm swelling, non-painful on palpation or manipulation. Uro/Perineum: Intact female, no heat yet Abd/GI: Soft, non-painful. No masses or fluid wave palpated Lymph Nodes: No peripheral lymphadenopathy Neurological: Alert and appropriate. No significant abnormalities Skin: Good hair coat. No ectoparasites seen Mentation: BAR Hydration: N Fecal: Not performed today

RADIOGRAPHIC STUDY OF THE HIND PAWS

Radiographs of the left tarsal joint in two imaging planes are provided for review.

RADIOGRAPHIC FINDINGS

The radiographs of the tarsal joint are moderately rotated.

A moderate homogeneous soft tissue swelling is seen at the lateral aspect of the left tarsal joint.

At the medial aspect of the distal aspect of the tibia, an isolated mineralized body, measuring 5 x 4 mm in size.

No additional abnormalities are appreciated.

RADIOGRAPHIC DIAGNOSIS

- Soft tissue swelling lateral aspect of the left tarsal joint
- Mineralized body medial aspect of the left tibiotarsal joint

INTERPRETATION OF THE FINDINGS & FURTHER RECOMMENDATIONS

The radiographs of the tarsal joint are moderately rotated, limiting the diagnostic value. The soft tissue swelling appears to be extraarticular and most likely origin include traumatic or primary inflammatory, focal outpouching of the joint capsule is a differential but appears less likely.

The isolated mineralized body can present dystrophic mineralization, metaplasia of the joint capsule of the talocrural joint/synovial osteochondromatosis, avulsion fracture (but no signs for accompanying soft tissue swelling).

Ultrasound can be used as advanced diagnostic tool for assessing the soft tissue swelling laterally and rule in/out articular involvement. Rule out instability of the left talocrural joint as well. In case of doubt, recommend repeating radiographs of the tarsal joint in a well positioned mediolateral & dorsoplantar projection.

SonoPath Teleradiology

EDUCATIONAL TELECONSULTATION SERVICES™

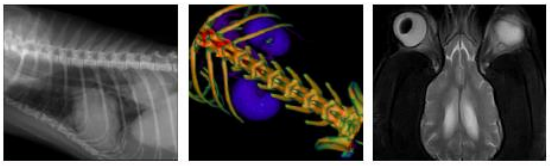

SonoPath.com
1-800-838-4268 info@sonopath.com

PATIENT

Luna Mottmann

SPECIES

Canine

BREED

Bulldog Mix

SEX

Fe

AGE

6 Months

INTERPRETED BY

Sebastian Schaub, DVM
Dr. med. vet. DipECVDI

HOSPITAL NAME

DPC Veterinary Hospital

REFERRING VET

Dr. Rivera

INVOICE

51158

DATE

3-25-22

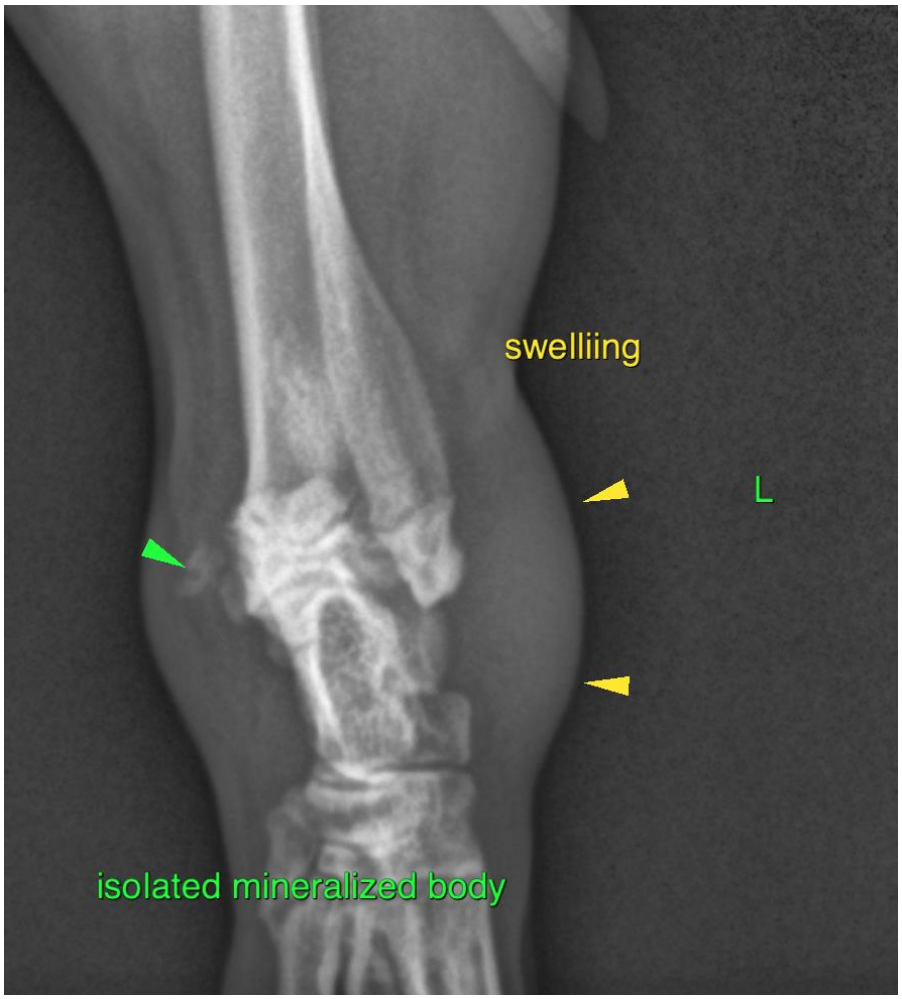

The information and recommendations provided are based on the images presented by the referring veterinarian/sonographer. No evaluation can be communicated regarding pathology that was not visible in the image/video clips provided.

Thank you for this referral. If the clinical or image interpretation does not parallel your findings or if I can be of any further assistance please contact me.

Sebastian Schaub, Sebastian Schaub, DVM, Dr. med. vet. DipECVDI
sebast.schaub@gmail.com