SonoPath Teleradiology

EDUCATIONAL TELECONSULTATION SERVICES™

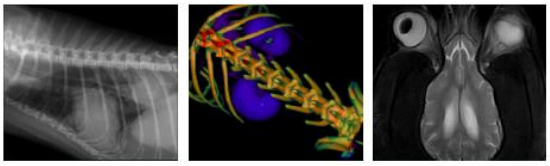

SonoPath.com
1-800-838-4268 info@sonopath.com

PATIENT

Buster Stewart

SPECIES

Canine

BREED

Rottweiler

SEX

Male

AGE

7 Years 10 Months

INTERPRETED BY

Sebastian Schaub, DVM Dr. med. vet. DipECVDI

HOSPITAL NAME

Elizabeth AH

REFERRING VET

Leon Anderson, DVM

INVOICE

14533

DATE

3/25/22

PRESENTING CLINICAL SIGNS

History: Buster has been limping on his right front and it seems occasional or later in the day. He will just be laying there and crying. He isn't playing as much - just laying around. He is eating and drinking fine though and taking treats. He usually demands that they play ball with him but he has been just taking the ball and going to lay down with it and is done.

Abnormal PE/Chem/CBC/UA Results: SR Blood work panel pending. Abd Ultrasound pending Physical Exam was within Normal Limits.

RADIOGRAPHIC STUDY OF THE FRONT LIMBS

A complete set of radiographs of the front limbs is provided for review.

RADIOGRAPHIC FINDINGS

Both shoulder joints present sclerosis of the bicipital groove.

The periarticular bones of the right elbow joint present mild osteophyte new bone formation. No additional abnormalities of the right elbow joint are appreciated.

The periarticular bones of the left elbow joint present moderate osteophyte new bone formation, most accentuated at the medial humeral epicondyle. The contour of the medial coronoid process is ill-defined, and the tip cannot be appreciated. In the proximal aspect of the left flexor muscles – at the medial aspect of the left elbow joint – an irregular roundish, but well-defined, mineralized body, measuring 13 x 9 mm in size is visible.

The osseous and surrounding soft tissue structures of the carpal joints bilaterally are within normal limits.

RADIOGRAPHIC DIAGNOSIS

- Coronoid disease left elbow joint
- Moderate degenerative osteoarthrosis left elbow joint with evidence of medial humeral epicondylitis
- Suspect left sided flexor enthesopathy left elbow joint
- Mild degenerative osteoarthrosis right elbow joint
- Sclerosis bicipital groove humerus bilaterally

INTERPRETATION OF THE FINDINGS & FURTHER RECOMMENDATIONS

The findings are consistent with pathology of the coronoid process of the left elbow joint with secondary degenerative joint disease and likely accompanying flexor enthesopathy with metaplasia in the proximal aspect of the left flexor muscle.

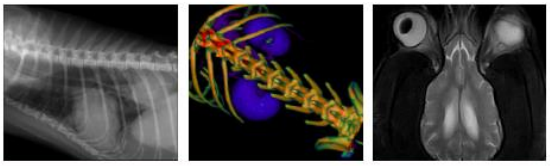

SonoPath.com
1-800-838-4268 info@sonopath.com

PATIENT

Buster Stewart

SPECIES

Canine

BREED

Rottweiler

SEX

Male

AGE

7 Years 10 Months

INTERPRETED BY

Sebastian Schaub, DVM Dr. med. vet. DipECVDI

HOSPITAL NAME

Elizabeth AH

REFERRING VET

Leon Anderson, DVM

INVOICE

14533

DATE

3/25/22

The mild degenerative joint disease of the right elbow joint might be a sequela to 'wear-and-tear' or underlying elbow dysplasia.

The sclerosis of the bicipital groove of the shoulder joints can indicate pathology of the bicipital tendon.

Rule out pathology of the bicipital tendon/rotator cuff of the shoulder joint as well as pain originating from the cervical spine/brachial plexus. If pain can be localized on the elbow joints, a CT study can be used as advanced imaging modality for further definition.

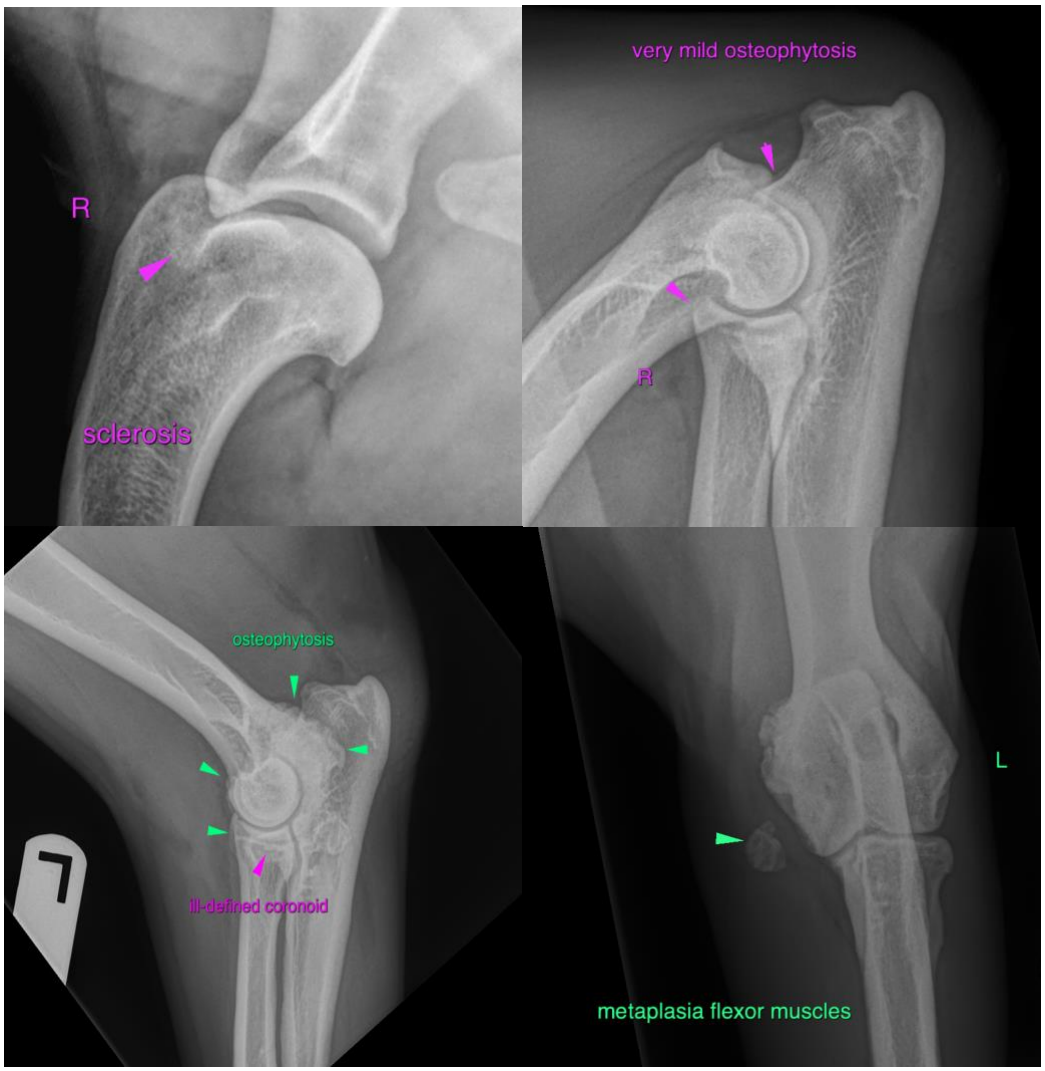

The information and recommendations provided are based on the images presented by the referring veterinarian/sonographer. No evaluation can be communicated regarding pathology that was not visible in the image/video clips provided.

SonoPath Teleradiology

EDUCATIONAL TELECONSULTATION SERVICES™

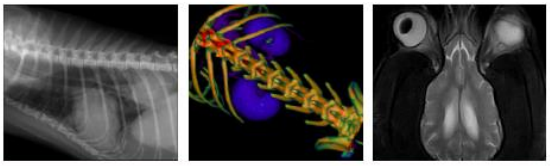

SonoPath.com
1-800-838-4268 info@sonopath.com

PATIENT

Buster Stewart

SPECIES

Canine

BREED

Rottweiler

SEX

Male

AGE

7 Years 10 Months

INTERPRETED BY

Sebastian Schaub, DVM Dr. med. vet. DipECVDI

HOSPITAL NAME

Elizabeth AH

REFERRING VET

Leon Anderson, DVM

INVOICE

14533

DATE

3/25/22

Thank you for this referral. If the clinical or image interpretation does not parallel your findings or if I can be of any further assistance please contact me.

Sebastian Schaub, Sebastian Schaub, DVM, Dr. med. vet. DipECVDI
sebast.schaub@gmail.com