



PATIENT PRESENTING CLINICAL SIGNS

Gus Cudia O thinks he had a seizure around 9pm, lasted 1-2 minutes. During seizure urinated but has not since and no bm since. Has had obsessive sneezing issues in the past, has been to vet twice and given antibiotics but in the past few days seems to have gotten worse again. Yesterday could have possibly gotten into chicken bones, O took them away but doesn't know if he got any. Marked decreased airflow from right nostril, no active nasal discharge upon exam. Suspect nasal lesion with metastasis to the brain. Awaiting radiographs from rDVM.

SPECIES Canine

Abnormal PE/Chem/CBC/UA Results: _CBC - mildly increased RBC but not HCT, markedly elevated WBC (neutrophilia and monocytosis)

BREED COMPUTED TOMOGRAPHY OF THE SKULL

Dachshund A high resolution pre- and post-contrast CT study of the skull is provided for review.

COMPUTED TOMOGRAPHIC FINDINGS

SEX The pictured parts of the dentition are complete and unremarkable in all jaw quadrants.

MN In the nasal cavity, a moderate amount of fluid attenuating material is attached to the nasal mucosal lining. Moderate destruction of the included aspects of the nasal conchal structures and the nasal turbinate structures is appreciated.

AGE The articular surface of the zygomatic process of the temporal bone bilaterally has a convex shape and the condylar process of the mandible bilaterally has a corresponding concave formation.

5 Years

INTERPRETED BY Both tympanic bullae are aerated, the mucosal lining is not seen, the bony wall is smooth and thin. The external ear canals are within normal limits.

Sebastian Schaub, DVM
Dr. med. vet. DipECVDI

The brain presents no deviation from normal anatomy and symmetry. The brain parenchyma is homogeneous and within normal limits for attenuation and distribution of contrast enhancement. The ventricular system is non-dilated and symmetric.

HOSPITAL NAME The submandibular and medial retropharyngeal lymph nodes are small and elongated with a normal short-to-long-axis-ratio is < 0.5, the attenuation and contrast enhancement pattern is uniform.

Bridgwater
Veterinary Hospital
and Wellness Centre

COMPUTED TOMOGRAPHIC DIAGNOSIS

- Destructive rhinitis
- Dysplasia temporomandibular joints
- Structural normal brain

REFERRING VET

Dr. J. Shapera

INTERPRETATION OF THE FINDINGS & FURTHER RECOMMENDATIONS

INVOICE The computed tomographic findings are suggestive for non-specific rhinitis (e.g. lymphocytic plasmocytic, eosinophilic) ± bacterial superinfection. The changes noted are not typical of fungal rhinitis, foreign body related rhinitis or underlying dental disease. There are no signs for nasal neoplastic disease. Rhinoscopy including sampling for histopathology and microbial can be used as advanced diagnostic test.

57485

DATE In the present study of the brain there is no evidence of macromorphological disease, which supports the presumptive diagnosis of idiopathic epilepsy. If not yet done so the workup should be complemented by examination of CSF and complete bloodwork to screen for brain disease that is not necessarily associated with structural changes of the brain parenchyma and rule out

3-24-23



PATIENT hepatoencephalopathy and other systemic illness. In case of the strong clinical suspicion of structural intraparenchymal changes an MRI may be considered.

Gus Cudia

SPECIES

Canine

BREED

Dachshund

SEX

MN

AGE

5 Years

INTERPRETED BY

Sebastian Schaub, DVM
Dr. med. vet. DipECVDI

HOSPITAL NAME

Bridgwater
Veterinary Hospital
and Wellness Centre

REFERRING VET

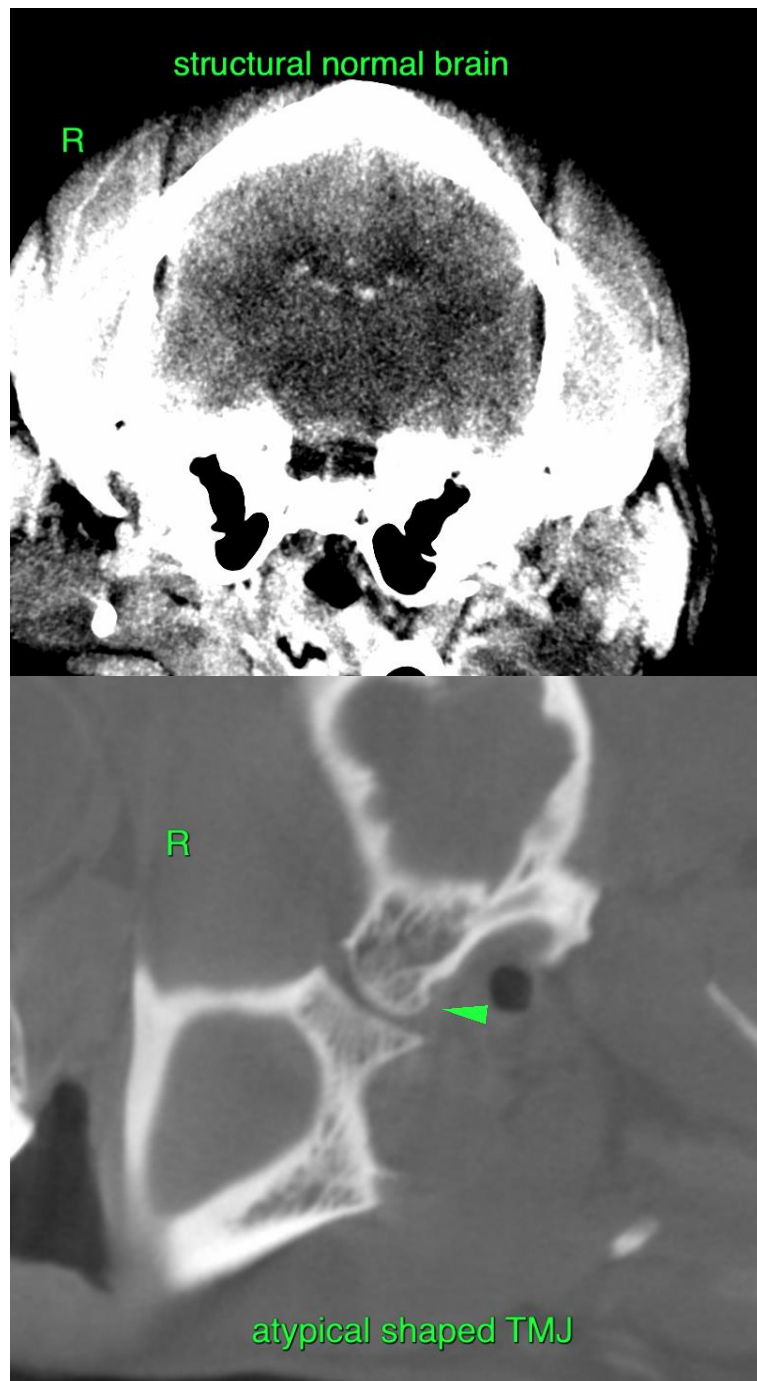
Dr. J. Shapera

INVOICE

57485

DATE

3-24-23





PATIENT

Gus Cudia

SPECIES

Canine

BREED

Dachshund

SEX

MN

AGE

5 Years

INTERPRETED BY

Sebastian Schaub, DVM
Dr. med. vet. DipECVDI

HOSPITAL NAME

Bridgwater
Veterinary Hospital
and Wellness Centre

REFERRING VET

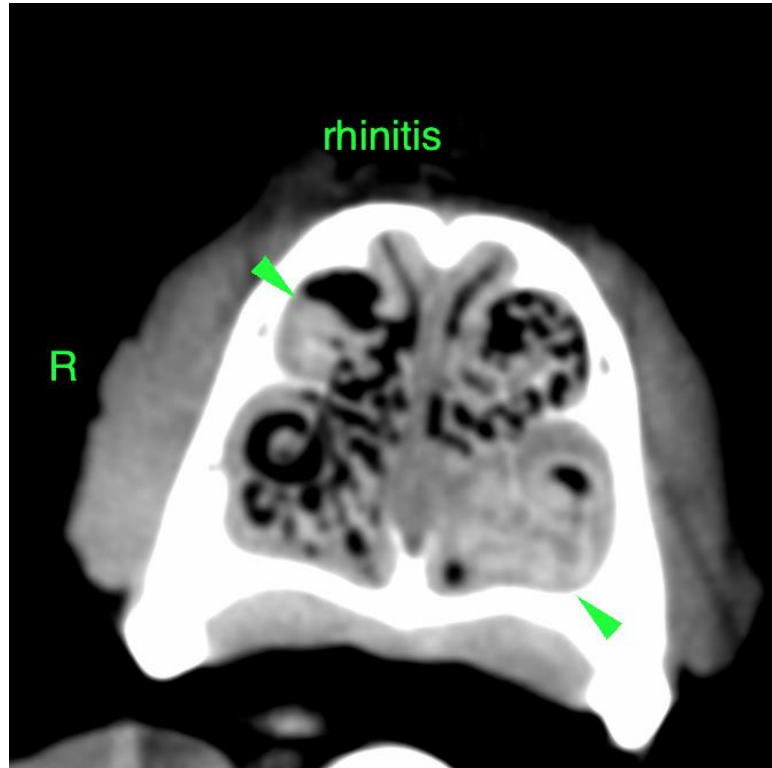
Dr. J. Shapera

INVOICE

57485

DATE

3-24-23



The information and recommendations provided are based on the images presented by the referring veterinarian/sonographer. No evaluation can be communicated regarding pathology that was not visible in the image/video clips provided.

Thank you for this referral. If the clinical or image interpretation does not parallel your findings or if I can be of any further assistance please contact me.

Sebastian Schaub, Sebastian Schaub, DVM, Dr. med. vet. DipECVDI
sebast.schaub@gmail.com