



PATIENT PRESENTING CLINICAL SIGNS

Sofie Setlock History: Nasal discharge
 Abnormal PE/Chem/CBC/UA Results: Mal-occlusion, Left lower K9 tooth has caused a defect in the rostral hard palate.

SPECIES COMPUTED TOMOGRAPHIC STUDY OF THE SKULL

Canine
 A high resolution pre- and post-contrast CT study of the skull is provided for review.

BREED COMPUTED TOMOGRAPHIC FINDINGS

Yorkie Poo Lingual deviation of triadan 304 is present. A defect is seen in the hard palate, at the palatine aspect of triadan 204. The tooth elements 105, 106, 205, 206, 305, 311, 405 and 411 are absent. The root of triadan 203 is perforating the left nasal cavity. Triadan 104 is oriented in a rostral direction.

SEX
 Spayed Female Moderate destruction of the left nasal conchal structures is seen in the rostroventral aspect.

AGE
 3 Years 6 Months Both temporomandibular joints present congruent joint spaces with even subchondral bone surfaces and are considered within normal limits.

INTERPRETED BY
 Sebastian Schaub, DVM
 Dr. med. vet. DipECVDI The brain presents no deviation from normal anatomy and symmetry. The brain parenchyma is homogeneous and within normal limits for attenuation and distribution of contrast enhancement. The ventricular system is non-dilated and symmetric.

HOSPITAL NAME
 Mobile Pet Imaging The submandibular and medial retropharyngeal lymph nodes are small and elongated with a normal short-to-long-axis-ratio is < 0.5, the attenuation and contrast enhancement pattern is uniform.

REFERRING VET
 Dr. Meaux **COMPUTED TOMOGRAPHIC DIAGNOSIS**

- History of lingual deviation of triadan 304, secondary traumatic oronasal fistula formation by perforation of the nasal cavity by triadan 304
- Oronasal fistula 203
- Left sided destructive rhinitis
- Multiple absent teeth

INVOICE INTERPRETATION OF THE FINDINGS & FURTHER RECOMMENDATIONS

14493 The findings are consistent with the history of oronasal fistula formation secondary to malposition of triadan 204 with perforation of the hard palate. There is evidence of the tooth root of triadan 203 perforating the left nasal cavity as well. Secondary left sided destructive rhinitis.

DATE
 3/24/22 Potential therapy options ± sparing triadan 204 can be discussed with dentist.



PATIENT

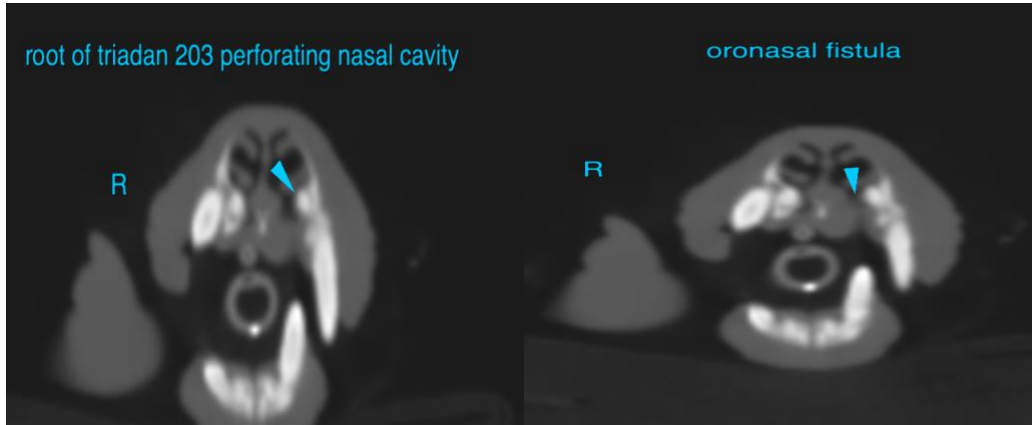
Sofie Setlock

SPECIES

Canine

BREED

Yorkie Poo



SEX

Spayed Female

The information and recommendations provided are based on the images presented by the referring veterinarian/sonographer. No evaluation can be communicated regarding pathology that was not visible in the image/video clips provided.

AGE

3 Years 6 Months

Thank you for this referral. If the clinical or image interpretation does not parallel your findings or if I can be of any further assistance please contact me.

Sebastian Schaub, Sebastian Schaub, DVM, Dr. med. vet. DipECVDI
sebast.schaub@gmail.com

INTERPRETED BY

Sebastian Schaub, DVM
Dr. med. vet. DipECVDI

HOSPITAL NAME

Mobile Pet Imaging

REFERRING VET

Dr. Meaux

INVOICE

14493

DATE

3/24/22