SonoPath Teleradiology

EDUCATIONAL TELECONSULTATION SERVICES™

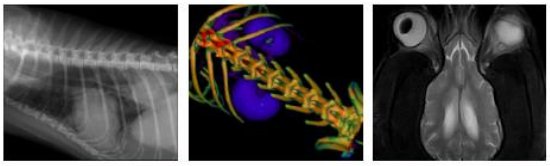

SonoPath.com
1-800-838-4268 info@sonopath.com

PATIENT

Leia Kenyon

SPECIES

Canine

BREED

Terrier Mix

SEX

Spayed Female

AGE

5 Years

INTERPRETED BY

Sebastian Schaub, DVM Dr. med. vet. DipECVDI

HOSPITAL NAME

Animal Health Care Denver

REFERRING VET

Cathryn Sayer

INVOICE

14529

DATE

3/24/22

PRESENTING CLINICAL SIGNS

History: Occasionally skips meals and occasionally has blood streaks in stool.
Abnormal PE/Chem/CBC/UA Results: Normal bloodwork, UA, and fecal test.

COMPUTED TOMOGRAPHIC STUDY OF THE ABDOMEN

A high resolution pre- and post-contrast CT study of the abdomen is provided for review.

COMPUTED TOMOGRAPHIC FINDINGS

The serosal fat presents normal attenuation behavior. There is no evidence of peritoneal effusion or peritonitis.

Both kidneys present within normal limits for size, shape and organ architecture. After contrast administration a bilaterally symmetric and uniform nephro- and pyelogram is noted.

The adrenal glands are within normal limits for size, shape and organ architecture.

Both liver and spleen present with normal shape, even surface, uniformly attenuating parenchyma and homogeneous contrast enhancement, unremarkable.

The gallbladder contains a moderate amount of mild hyperattenuating biliary sludge.

The pancreas is evenly contoured, the pancreatic parenchyma is homogeneous and presents uniform contrast enhancement.

The position, delineation, wall and content of the gastrointestinal tract are considered within normal limits throughout.

The bony and surrounding soft tissue structures reveal no abnormalities.

COMPUTED TOMOGRAPHIC DIAGNOSIS

- Normal abdomen but moderate biliary sludge without signs of obstruction

INTERPRETATION OF THE FINDINGS & FURTHER RECOMMENDATIONS

The CT study of the abdomen presents without abnormalities.

SonoPath Teleradiology

EDUCATIONAL TELECONSULTATION SERVICES™

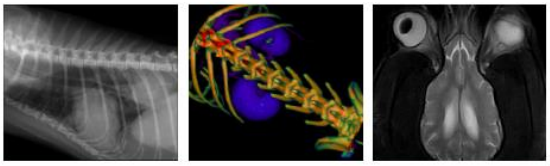

SonoPath.com
1-800-838-4268 info@sonopath.com

PATIENT

Leia Kenyon

SPECIES

Canine

BREED

Terrier Mix

SEX

Spayed Female

AGE

5 Years

INTERPRETED BY

Sebastian Schaub, DVM Dr. med. vet. DipECVDI

HOSPITAL NAME

Animal Health Care Denver

REFERRING VET

Cathryn Sayer

INVOICE

14529

DATE

3/24/22

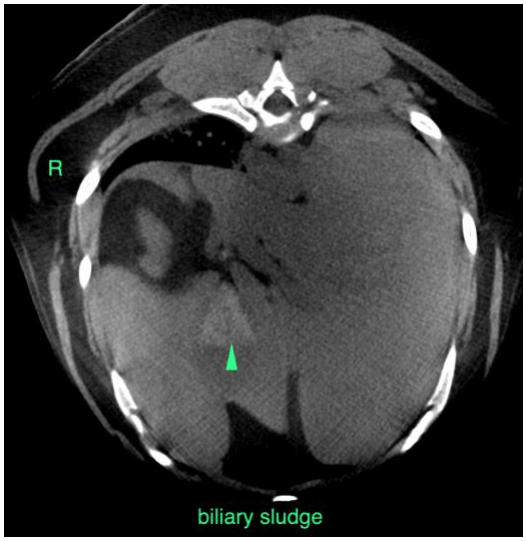

The information and recommendations provided are based on the images presented by the referring veterinarian/sonographer. No evaluation can be communicated regarding pathology that was not visible in the image/video clips provided.

Thank you for this referral. If the clinical or image interpretation does not parallel your findings or if I can be of any further assistance please contact me.

Sebastian Schaub, Sebastian Schaub, DVM, Dr. med. vet. DipECVDI
sebast.schaub@gmail.com