



PATIENT PRESENTING CLINICAL SIGNS

Sassy Garrett Sassy has been seen at Creekside and Livingspring vet for coughing. The coughing started about 6 months ago and she was/is actively blowing green snot out of her nose. She has been on Doxycycline for the cough/snot and it has not seemed to help at all. Last night Sassy ate her food and this morning around 10:30am they noticed vomit around the dog room. She will start coughing, which turns into a gag and then she vomits up yellow/red liquid. She was shaking a lot. She did not eat this morning. Sassy will also have intense shaking fits and she has been panting an excessive amount. Previous records show that in 7/11/23 the radiographs of the chest showed a consolidation of the left middle lung lobe. Was treated with ciprofloxacin

SPECIES

Canine

BREED

Catahoula Leopard Dog Mix

Abnormal PE/Chem/CBC/UA Results: Cardiovascular/Respiratory: -No murmur or arrhythmia. - DECREASED LUNG SOUND LEFT SIDE. -Eupnic. MUCOID DISCHARGE FORM LEFT NOSTRIL Ambulatory X 4STIFF GAIT DECREASED MUSCLE MASS IN REAR.

RADIOGRAPHIC STUDY OF THE THORAX

Radiographs of the thorax in three imaging planes are provided for review.

SEX

FS

RADIOGRAPHIC FINDINGS

The vertebral endplates T3/T4 present moderate spondylosis formation.

The extrathoracic soft tissues present homogeneous without abnormalities.

AGE

9 Years, 5 Months

The heart is of normal size and shape, there is no evidence of cardiac chamber or vascular enlargement. The pulmonary vasculature is within normal limits.

INTERPRETED BY

Sebastian Schaub, DVM
Dr. med. vet. DipECVDI

The cranial mediastinum presents the expected soft tissue opacity. The mediastinal width is less than twice the width of the vertebral column at the same level.

The trachea is normal in diameter and presents the anticipated course. The luminal outline of the trachea is smooth.

HOSPITAL NAME

Elizabeth Animal Hospital

The right middle lung lobe is consolidated with air-bronchograms and maintained volume, presenting a lobar sign. The consolidated right middle lung lobe causes border effacement of the right lateral aspect of the cardiac silhouette.

The diaphragm is well delineated with even surface and the expected mild cranial bulging of the diaphragmatic cupola.

REFERRING VET

Kim Allyn, DVM

RADIOGRAPHIC DIAGNOSIS

- Alveolar pattern right middle lung lobe

INVOICE

57425

INTERPRETATION OF THE FINDINGS & FURTHER RECOMMENDATIONS

Regarding the history, there appears to be alternating consolidation of different lung lobes increasing the odds for pneumonia. If there is stationary or progressive consolidation of the right middle lung lobe the odds for chronic pneumonia with hepatization or neoplastic infiltration are high. Recommend complementing workup by FNA sampling of the consolidated right middle lung lobe.

DATE

3-23-23



PATIENT

Sassy Garrett

SPECIES

Canine

BREED

Catahoula Leopard
Dog Mix

SEX

FS

AGE

9 Years, 5 Months

INTERPRETED BY

Sebastian Schaub, DVM
Dr. med. vet. DipECVDI

HOSPITAL NAME

Elizabeth Animal
Hospital

REFERRING VET

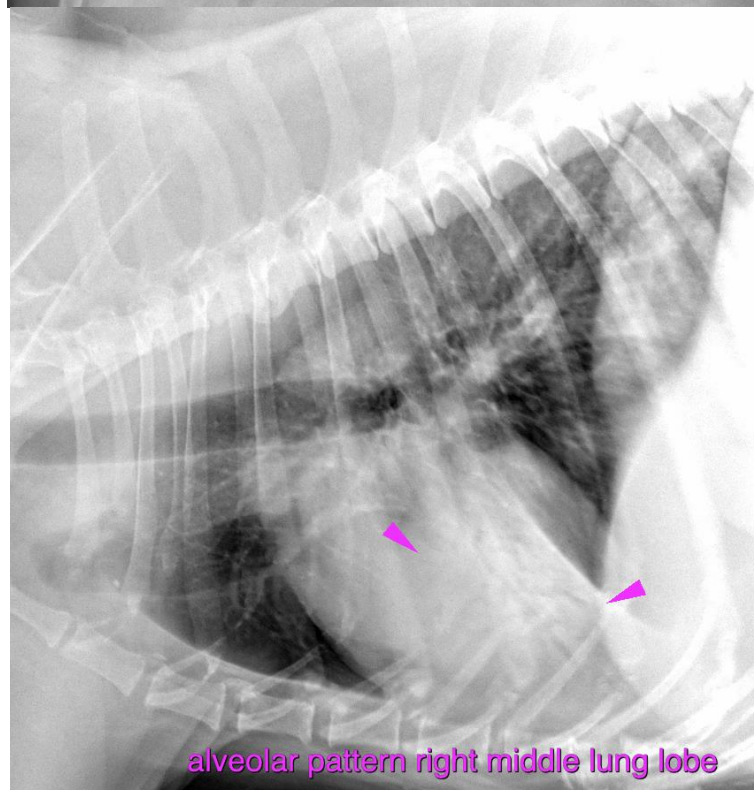
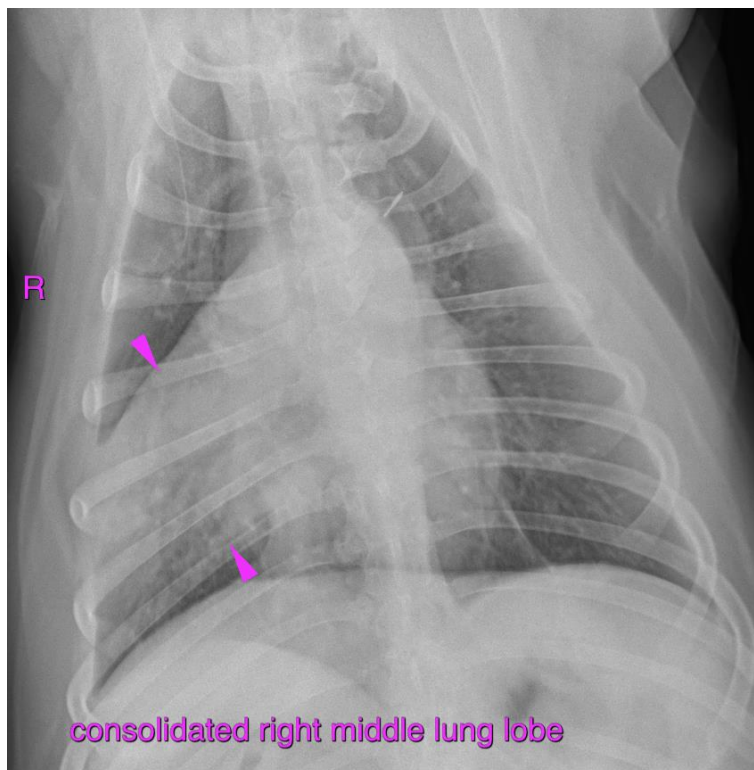
Kim Allyn, DVM

INVOICE

57425

DATE

3-23-23





PATIENT

Sassy Garrett

SPECIES

Canine

BREED

Catahoula Leopard
Dog Mix

The information and recommendations provided are based on the images presented by the referring veterinarian/sonographer. No evaluation can be communicated regarding pathology that was not visible in the image/video clips provided.

Thank you for this referral. If the clinical or image interpretation does not parallel your findings or if I can be of any further assistance please contact me.

SEX

FS

Sebastian Schaub, Sebastian Schaub, DVM, Dr. med. vet. DipECVDI
sebast.schaub@gmail.com

AGE

9 Years, 5 Months

INTERPRETED BY

Sebastian Schaub, DVM
Dr. med. vet. DipECVDI

HOSPITAL NAME

Elizabeth Animal
Hospital

REFERRING VET

Kim Allyn, DVM

INVOICE

57425

DATE

3-23-23