



PATIENT PRESENTING CLINICAL SIGNS

GG Deaton History: Reason for Visit: limping RH History: 5y 7m old SF Pitbull presents for limping RH leg since 3/12/22. No known injury, O says sometimes paws are sore so she wonders if that could be the reason. O also wants ears checked, hx of ear infection 2020

SPECIES

Canine

RADIOGRAPHIC STUDY OF THE RIGHT HIND PAW

Radiographs of the right hind paw in two imaging planes are provided for review.

BREED

Pitbull

RADIOGRAPHIC FINDINGS

The soft tissue shadow of the popliteal lymph node is prominent.

The soft tissues of the fourth digit appear prominent.

SEX

Spayed Female

The osseous structures of the right hind paw are within normal limits.

RADIOGRAPHIC DIAGNOSIS

AGE

5 Years 7 Months

- Equivocal soft tissue swelling 4. digit right hind paw
- Lymphadenopathy right popliteal lymph node

INTERPRETATION OF THE FINDINGS & FURTHER RECOMMENDATIONS

INTERPRETED BY

Sebastian Schaub,
DVM Dr. med. vet.
DipECVDI

The suspected swelling might be a subjective impression, due to oblique projection accentuating the pad of the fourth digit. Check clinically for swelling of the digits which can be traumatic, inflammatory or less likely neoplastic in origin.

FNA sampling of the right popliteal lymph node appears beneficial to differentiate between reactive hyperplasia or neoplastic transformation.

HOSPITAL NAME

DPC Veterinary
Hospital

REFERRING VET

Dr. Oldenhoff

INVOICE

14455

DATE

3/23/22



PATIENT

GG Deaton

SPECIES

Canine

BREED

Pitbull

SEX

Spayed Female

AGE

5 Years 7 Months

INTERPRETED BY

Sebastian Schaub,
DVM Dr. med. vet.
DipECVDI

HOSPITAL NAME

DPC Veterinary
Hospital

REFERRING VET

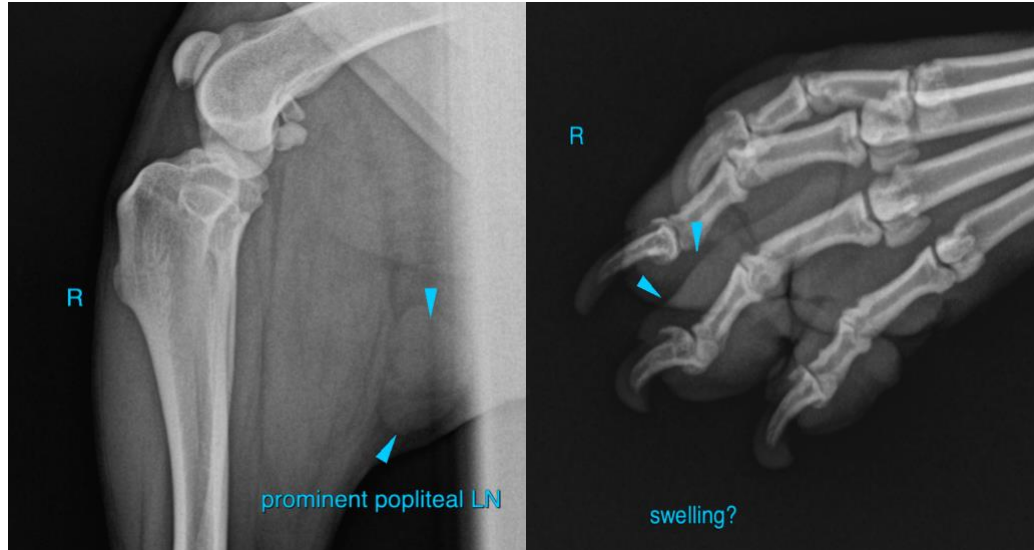
Dr. Oldenhoff

INVOICE

14455

DATE

3/23/22



The information and recommendations provided are based on the images presented by the referring veterinarian/sonographer. No evaluation can be communicated regarding pathology that was not visible in the image/video clips provided.

Thank you for this referral. If the clinical or image interpretation does not parallel your findings or if I can be of any further assistance please contact me.

Sebastian Schaub, Sebastian Schaub, DVM, Dr. med. vet. DipECVDI
sebast.schaub@gmail.com