



PATIENT PRESENTING CLINICAL SIGNS

Max Olish Mass effect right mandible - suspect Amelanotic melanoma

COMPUTED TOMOGRAPHY OF THE SKULL & THORAX

SPECIES A high resolution pre- and post-contrast CT study of the skull and a post-contrast CT study of the thorax are provided for review.

Canine

COMPUTED TOMOGRAPHIC FINDINGS

BREED Skull

Advanced abrasion of the crowns of all teeth is seen.

German Shepherd

Originating from the left lower lip, an ill-defined, uniform soft tissue attenuating and mild irregular contrast enhancing mass is seen, measuring 10.2 x 5.5 x 5.2 cm in size.

SEX

A small amount of fluid attenuating material is attached to the mucosal lining of the nasal conchal structures.

MI

Both temporomandibular joints present congruent joint spaces with even subchondral bone surfaces and are considered within normal limits.

AGE

11 Years

Both tympanic bullae are aerated, the mucosal lining is not seen, the bony wall is smooth and thin. The external ear canals present the expected width and mild to moderate mineralization of the walls.

INTERPRETED BY

The brain presents no deviation from normal anatomy and symmetry. The brain parenchyma is homogeneous and within normal limits for attenuation and distribution of contrast enhancement. The ventricular system is non-dilated and symmetric.

Sebastian Schaub, DVM
Dr. med. vet. DipECVDI

The mandibular lymph nodes are enlarged, L>>R.

HOSPITAL NAME

Thorax

Animal Surgical
Center

Multifocal spondylosis formation is seen along the thoracic spine.

The sternal, cranial mediastinal and tracheobronchial lymph nodes are small elongated with a normal short-to-long-axis-ratio is < 0.5, the attenuation and contrast enhancement pattern is uniform and considered within normal limits.

REFERRING VET

Integrative
Veterinary Therapies

The cardiovascular structures including the pulmonary vasculature are within normal limits.

The bronchial tree presents with regular branching and tapers uniformly towards the periphery as expected, the bronchial walls are thin and smooth. The bronchus-to-artery ratio is within normal limits.

INVOICE

The lung parenchyma presents the expected architecture and attenuation behavior, but zones of dystelectasis of the ventral dependent aspects of the lung parenchyma.

57350

Small incidental gas pockets are seen within the esophageal lumen, there is no evidence of abnormal dilation.

COMPUTED TOMOGRAPHIC DIAGNOSIS

DATE

3-21-23

- Soft tissue mass left lower lip
- Lymphadenopathy mandibular lymph nodes, L>R
- Mild rhinitis



PATIENT

Max Olish

- Abrasion of the crowns of all teeth
- Dystrophic mineralization external ear canals
- Spondylosis deformans thoracic spine
- No evidence of pulmonary metastatic disease

SPECIES

Canine

BREED

German Shepherd

SEX

MI

AGE

11 Years

INTERPRETED BY

Sebastian Schaub, DVM
Dr. med. vet. DipECVDI

HOSPITAL NAME

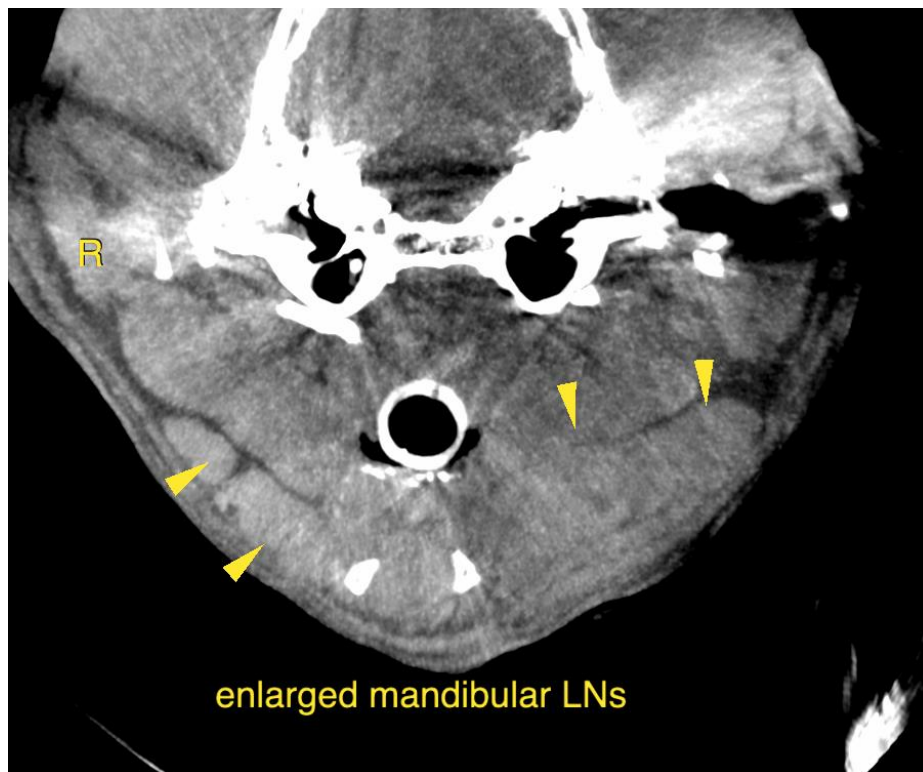
Animal Surgical
Center

REFERRING VET

Integrative
Veterinary Therapies

INTERPRETATION OF THE FINDINGS & FURTHER RECOMMENDATIONS

The CT study is fitting the history of soft tissue mass originating from the left lower lip – regarding the history there is suspicion for amelanotic melanoma. The mass has ill-defined margins but presents without signs of osseous involvement. The enlarged mandibular lymph nodes are highly suggestive for metastatic disease.



INVOICE

57350

DATE

3-21-23



PATIENT

Max Olish

SPECIES

Canine

BREED

German Shepherd

SEX

MI

AGE

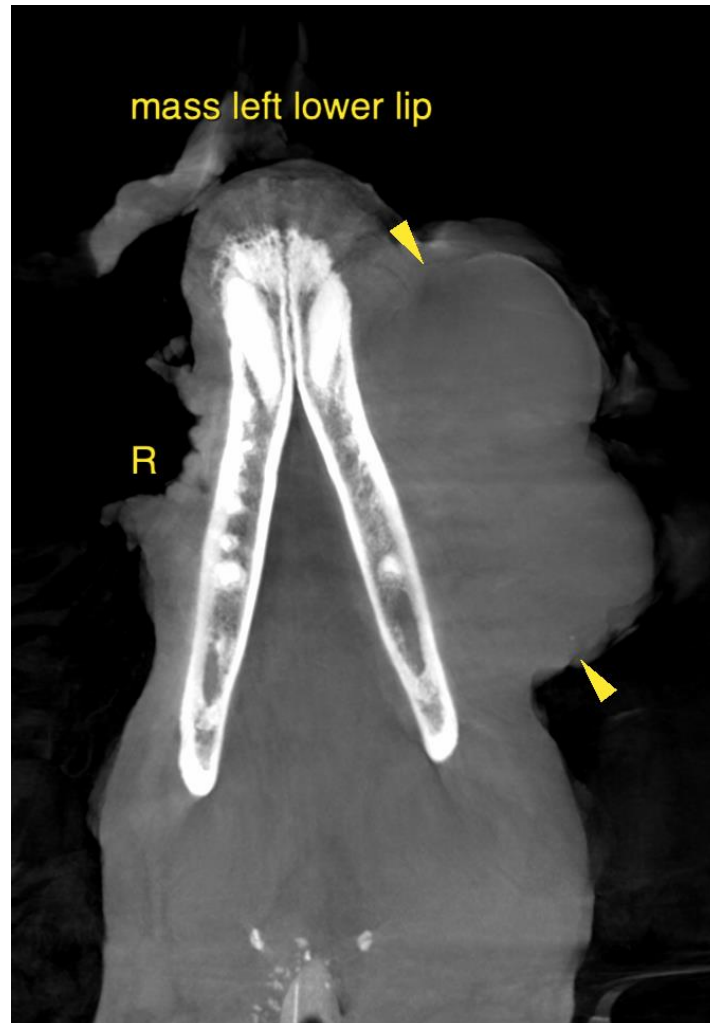
11 Years

INTERPRETED BY

Sebastian Schaub, DVM
Dr. med. vet. DipECVDI

HOSPITAL NAME

Animal Surgical
Center



REFERRING VET

Integrative
Veterinary Therapies

The information and recommendations provided are based on the images presented by the referring veterinarian/sonographer. No evaluation can be communicated regarding pathology that was not visible in the image/video clips provided.

Thank you for this referral. If the clinical or image interpretation does not parallel your findings or if I can be of any further assistance please contact me.

INVOICE

57350

Sebastian Schaub, Sebastian Schaub, DVM, Dr. med. vet. DipECVDI
sebast.schaub@gmail.com

DATE

3-21-23