



PATIENT PRESENTING CLINICAL SIGNS

Nami Oveson Pt was presented on 3/15/22 with bloodshot and swollen eyes. Exam- OS hyphema, conjunctiva visible from upper eyelid and hemorrhagic, corneal surface abnormal and stippled ventrally, miotic pupil, OD mydriatic pupil with normal PLR, no murmur ausculted, abdomen soft and pliable.

SPECIES Concern for intraocular lesion but unclear whether hemorrhage or tumor.
 Feline Abnormal PE/Chem/CBC/UA Results: Fluorescein stain - uptake positive over stippling
 Decreased nasal air flow through left nares visualized on glass microscope slide. Discussed partial proptosis due to trauma vs. possible retrobulbar disease such as neoplasia or abscess.

BREED COMPUTED TOMOGRAPHY OF THE SKULL, THORAX AND ABDOMEN

DLH A high resolution pre- and post-contrast CT study of the skull and abdomen and a post-contrast CT study of the thorax are provided for review.

SEX COMPUTED TOMOGRAPHIC FINDINGS

FS Skull

Multiple teeth but some incisor teeth are absent.

AGE The left ocular bulb is enlarged, and a funnel shaped membrane is protruding into the vitreous chamber of the left eye. The contrast enhancing membrane is separated from the sclera by mild hyperattenuating material.
 10 Years

INTERPRETED BY The nasal cavity presents the expected aerated spaces between thin & even conchae and turbinates with smooth mucosal lining.
 Sebastian Schaub, DVM
 Dr. med. vet. DipECVDI

Both temporomandibular joints present congruent joint spaces with even subchondral bone surfaces and are considered within normal limits.

HOSPITAL NAME Both tympanic bullae are aerated, the mucosal lining is not seen, the bony wall is smooth and thin. The external ear canals are within normal limits.
 Mountain West
 Veterinary Hospital

The brain presents no deviation from normal anatomy and symmetry. The brain parenchyma is homogeneous and within normal limits for attenuation and distribution of contrast enhancement. The ventricular system is non-dilated and symmetric.

REFERRING VET The submandibular and medial retropharyngeal lymph nodes are small and elongated with a normal short-to-long-axis-ratio is < 0.5, the attenuation and contrast enhancement pattern is uniform.
 Allison Bowersox

INVOICE Thorax

51034 The bony and surrounding soft tissue structures are within normal limits.

DATE The sternal, cranial mediastinal and tracheobronchial lymph nodes are small elongated with a normal short-to-long-axis-ratio is < 0.5, the attenuation and contrast enhancement pattern is uniform and considered within normal limits.
 3-20-22

The cardiovascular structures including the pulmonary vasculature are within normal limits.



PATIENT

Nami Oveson

Multifocal moderate peribronchial cuffing is seen.

The lung parenchyma presents the expected architecture and attenuation behavior.

SPECIES

Feline

Small incidental gas pockets are seen within the esophageal lumen, there is no evidence of abnormal dilation.

Abdomen

BREED

DLH

The serosal fat presents normal attenuation behavior. There is no evidence of peritoneal effusion or peritonitis.

SEX

FS

Both kidneys present within normal limits for size, shape and organ architecture. A mild amount of mineral attenuating material is associated with the left renal pelvis. After contrast administration a bilaterally symmetric and uniform nephro- and pyelogram is noted.

The adrenal glands are within normal limits for size, shape and organ architecture.

AGE

10 Years

Both liver and spleen present with normal shape, even surface, uniformly attenuating parenchyma and homogeneous contrast enhancement, unremarkable.

The portal vein presents a normal order of its tributary veins and intrahepatic branching. No abnormal vessel is noted inside and outside of the liver parenchyma.

INTERPRETED BY

Sebastian Schaub, DVM
Dr. med. vet. DipECVDI

The pancreas is evenly contoured, the pancreatic parenchyma is homogeneous and presents uniform contrast enhancement.

The position, delineation, wall and content of the gastrointestinal tract are considered within normal limits throughout.

HOSPITAL NAME

Mountain West
Veterinary Hospital

Multiple mineral attenuating sutures are seen along the ventral abdominal wall.

COMPUTED TOMOGRAPHIC DIAGNOSIS

REFERRING VET

Allison Bowersox

- Suspect sided retinal detachment versus mass encompassing the right ocular bulb
- Bronchial lung pattern with multifocal peribronchial interstitial pattern
- History of full mouth extraction
- Normal abdomen

INTERPRETATION OF THE FINDINGS & FURTHER RECOMMENDATIONS

INVOICE

51034

DATE

3-20-22

The chances of the left ocular bulb are most consistent with retinal detachment, likely due to hemorrhage. The caudal margins of the left ocular bulb are ill-defined and either a mass encompassing the left ocular bulb caudally (e.g. such as feline restrictive orbital myofibroblastic sarcoma) or retrobulbar hemorrhage (e.g. secondary to blunt trauma to the eye with possible laceration of the ocular bulb) are considerations. I would consider the odds for traumatic insult higher than for neoplastic disease. Unfortunately, further definition is limited due to limited image contrast, ultrasound can be used as advanced diagnostic test. If there is evidence of traumatic laceration of the left ocular bulb, enucleation is considered as the therapy of choice.



PATIENT

Nami Oveson

The bronchial lung pattern is compatible with feline bronchial disease – check if there is a history of cough/wheezing.

SPECIES

Feline

BREED

DLH

SEX

FS

AGE

10 Years

INTERPRETED BY

Sebastian Schaub, DVM
Dr. med. vet. DipECVDI

HOSPITAL NAME

Mountain West
Veterinary Hospital

REFERRING VET

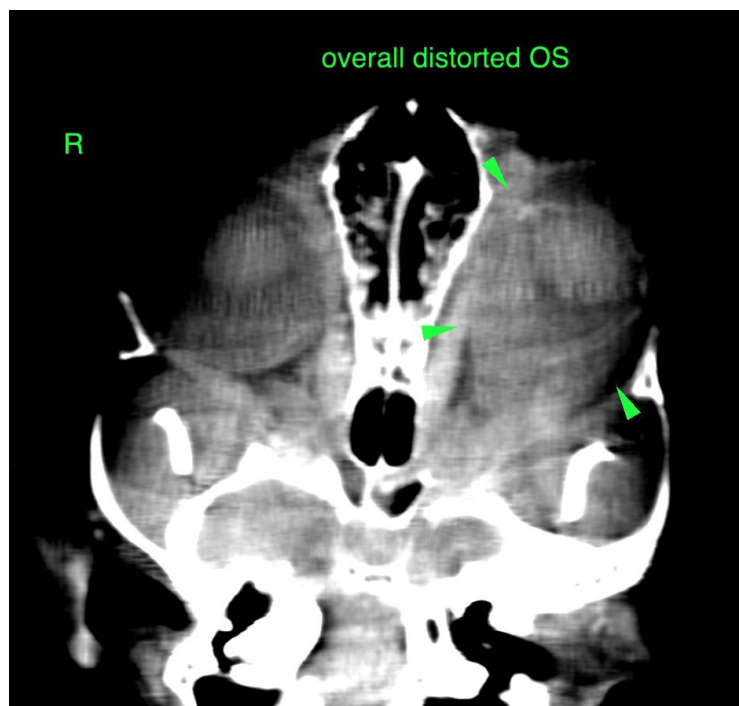
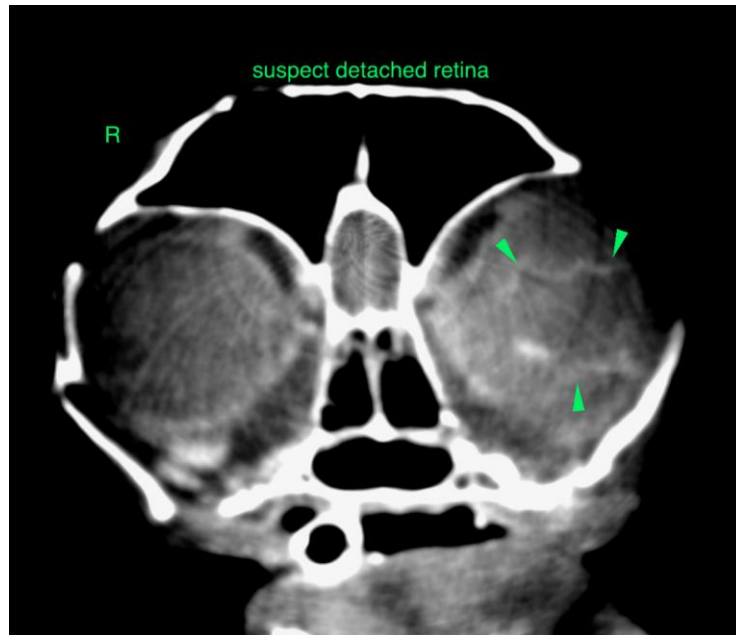
Allison Bowersox

INVOICE

51034

DATE

3-20-22





PATIENT

Nami Oveson

SPECIES

Feline

BREED

DLH

SEX

FS

AGE

10 Years

INTERPRETED BY

Sebastian Schaub, DVM
Dr. med. vet. DipECVDI

HOSPITAL NAME

Mountain West
Veterinary Hospital

REFERRING VET

Allison Bowersox

INVOICE

51034

DATE

3-20-22

The information and recommendations provided are based on the images presented by the referring veterinarian/sonographer. No evaluation can be communicated regarding pathology that was not visible in the image/video clips provided.

Thank you for this referral. If the clinical or image interpretation does not parallel your findings or if I can be of any further assistance please contact me.

Sebastian Schaub, Sebastian Schaub, DVM, Dr. med. vet. DipECVDI
sebast.schaub@gmail.com