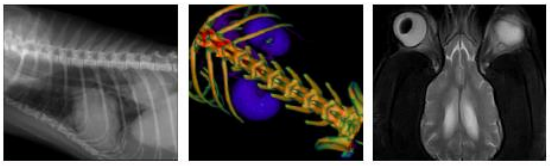

SonoPath.com
1-800-838-4268 info@sonopath.com

PATIENT

Jino Terpstra

SPECIES

Canine

BREED

Border Collie Mix

SEX

Neutered Male

AGE

11 Years

INTERPRETED BY

Sebastian Schaub, DVM Dr. med. vet. DipECVDI

HOSPITAL NAME

Catskill VC, PLLC

REFERRING VET

Dr. Marie Quattro

INVOICE

21441

DATE

3/2/23

PRESENTING CLINICAL SIGNS

History: P was referred by RDVM for a CT of the head to see if the tumor in P's right eye has wrapped around the bone, preventing the removal of the eye. CTed chest to check for metastasis.

COMPUTED TOMOGRAPHIC STUDY OF THE SKULL & THORAX

A high resolution pre- and post-contrast CT study of the skull and a plain CT study of the thorax are provided for review.

COMPUTED TOMOGRAPHIC FINDINGS

Skull

Triadan 108 is absent.

In the ventral/caudoventral aspect of the right orbit, between the right ocular bulb and the zygomatic arch, a well-defined, uniform soft tissue attenuating and heterogeneous contrast enhancing roundish mass is measuring 3.6 x 3.2 x 3.6 cm is seen. The right ocular bulb is displaced dorsally and rostrally by the mass effect. The right zygomatic gland is deviated ventrally. The mass is encompassing the right optic nerve. The mass in the right orbit is in contact with the inner surface of the right zygomatic arch and small moth-eaten osteolytic lesions of the zygomatic arch level with the mass are appreciated.

The nasal cavity presents the expected aerated spaces between thin & even conchae and turbinates with smooth mucosal lining.

Both temporomandibular joints present congruent joint spaces with even subchondral bone surfaces and are considered within normal limits.

Both tympanic bullae are aerated, the mucosal lining is not seen, the bony wall is smooth and thin. The external ear canals are within normal limits.

The brain presents no deviation from normal anatomy and symmetry. The brain parenchyma is homogeneous and within normal limits for attenuation and distribution of contrast enhancement. The ventricular system is non-dilated and symmetric.

The right medial retropharyngeal lymph node is mildly prominent.

Thorax

The bony and surrounding soft tissue structures are within normal limits.

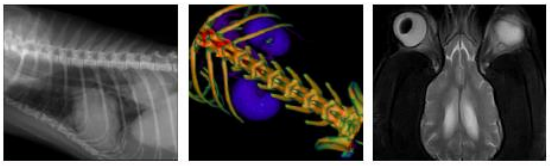

SonoPath.com
1-800-838-4268 info@sonopath.com

PATIENT

Jino Terpstra

SPECIES

Canine

BREED

Border Collie Mix

SEX

Neutered Male

AGE

11 Years

INTERPRETED BY

Sebastian Schaub, DVM Dr. med. vet. DipECVDI

HOSPITAL NAME

Catskill VC, PLLC

REFERRING VET

Dr. Marie Quattro

INVOICE

21441

DATE

3/2/23

The sternal, cranial mediastinal and tracheobronchial lymph nodes are small elongated with a normal short-to-long-axis-ratio is < 0.5, the attenuation pattern is uniform and considered within normal limits.
The cardiovascular structures including the pulmonary vasculature are within normal limits.

The bronchial tree presents with regular branching and tapers uniformly towards the periphery as expected, the bronchial walls are thin and smooth. The bronchus-to-artery ratio is within normal limits.
The lung parenchyma presents the expected architecture and attenuation behavior with randomly distributed interspersed punctuate mineralization.

Small incidental gas pockets are seen within the esophageal lumen, there is no evidence of abnormal dilation.

COMPUTED TOMOGRAPHIC DIAGNOSIS

- Soft tissue mass caudoventral aspect right orbit
- Secondary right sided exophthalmos
- Mild lymphadenopathy right medial retropharyngeal lymph node
- Absent triadan 108
- Pulmonary osteomas
- No evidence of pulmonary metastatic disease

INTERPRETATION OF THE FINDINGS & FURTHER RECOMMENDATIONS

The soft tissue mass in the right orbit is fitting the history and soft tissue neoplasia is the diagnosis – such as optic nerve meningioma, melanoma, myxosarcoma, carcinoma, other. Complete surgical excision of the mass by orbit exenteration is considered feasible and should include partial resection of the rostral segment of the zygomatic arch level with the mass (rostral base and rostral third of the zygomatic arch).

Recommend FNA sampling of the right medial retropharyngeal lymph node to rule out metastatic disease.

SonoPath Teleradiology

EDUCATIONAL TELECONSULTATION SERVICES™

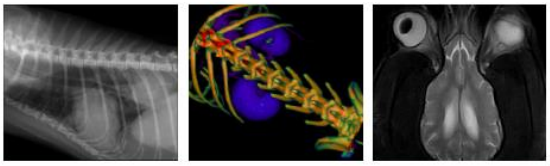

SonoPath.com
1-800-838-4268 info@sonopath.com

PATIENT

Jino Terpstra

SPECIES

Canine

BREED

Border Collie Mix

SEX

Neutered Male

AGE

11 Years

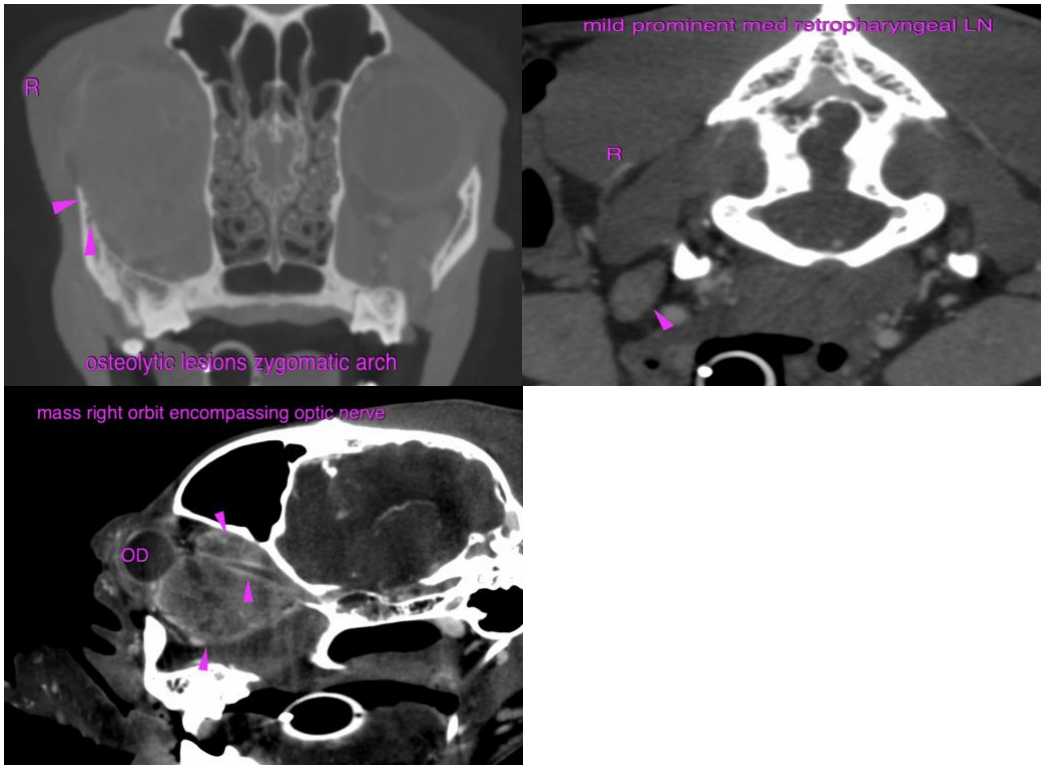

INTERPRETED BY

Sebastian Schaub, DVM Dr. med. vet. DipECVDI

HOSPITAL NAME

Catskill VC, PLLC

REFERRING VET

Dr. Marie Quattro

INVOICE

21441

DATE

3/2/23

The information and recommendations provided are based on the images presented by the referring veterinarian/sonographer. No evaluation can be communicated regarding pathology that was not visible in the image/video clips provided.

Thank you for this referral. If the clinical or image interpretation does not parallel your findings or if I can be of any further assistance please contact me.

Sebastian Schaub, Sebastian Schaub, DVM, Dr. med. vet. DipECVDI
sebast.schaub@gmail.com