



PATIENT PRESENTING CLINICAL SIGNS

Yuki Lucchesi Chronic intermittent coughing/hacking, possible heart murmur in the past, one not appreciated today

SPECIES RADIOGRAPHIC STUDY OF THE THORAX

Feline Radiographs of the thorax in three imaging planes are provided for review.

RADIOGRAPHIC FINDINGS

BREED

The surrounding bony structures are within normal limits.

Savannah

The extrathoracic soft tissues present homogeneous without abnormalities.

SEX

The heart is of normal size and shape, there is no evidence of cardiac chamber or vascular enlargement. The aortic arch is prominent and causes a small soft tissue bulging at the left cranial aspect of the heart in the VD view. The pulmonary vasculature is within normal limits.

MN

AGE

The trachea is normal in diameter and presents the anticipated course. The luminal outline of the trachea is smooth.

4.6 Years

Multifocal mild peribronchial cuffing is noted.

INTERPRETED BY

The lung parenchyma presents the expected architecture and opacity; the intrapulmonary vascular branching is seen up to the third order lung vessels.

Sebastian Schaub, DVM
Dr. med. vet. DipECVDI

The diaphragm is well delineated with even surface and the expected mild cranial bulging of the diaphragmatic cupola.

HOSPITAL NAME

RADIOGRAPHIC DIAGNOSIS

Boca Park Animal Hospital

- Mild bronchial pattern without signs for air-trapping
- Redundant aortic arch - incidental

REFERRING VET

INTERPRETATION OF THE FINDINGS & FURTHER RECOMMENDATIONS

Laura Warren

The bronchial lung pattern in combination with the intermittent cough is compatible with feline bronchial disease ("feline asthma"). The odds for infectious bronchitis - viral, bacterial, parasitic - are considered low. Recommend empirical management.

INVOICE

50680

DATE

3-2-22



PATIENT

Yuki Lucchesi

SPECIES

Feline

BREED

Savannah

SEX

MN

AGE

4.6 Years

INTERPRETED BY

Sebastian Schaub, DVM
Dr. med. vet. DipECVDI

HOSPITAL NAME

Boca Park Animal
Hospital

REFERRING VET

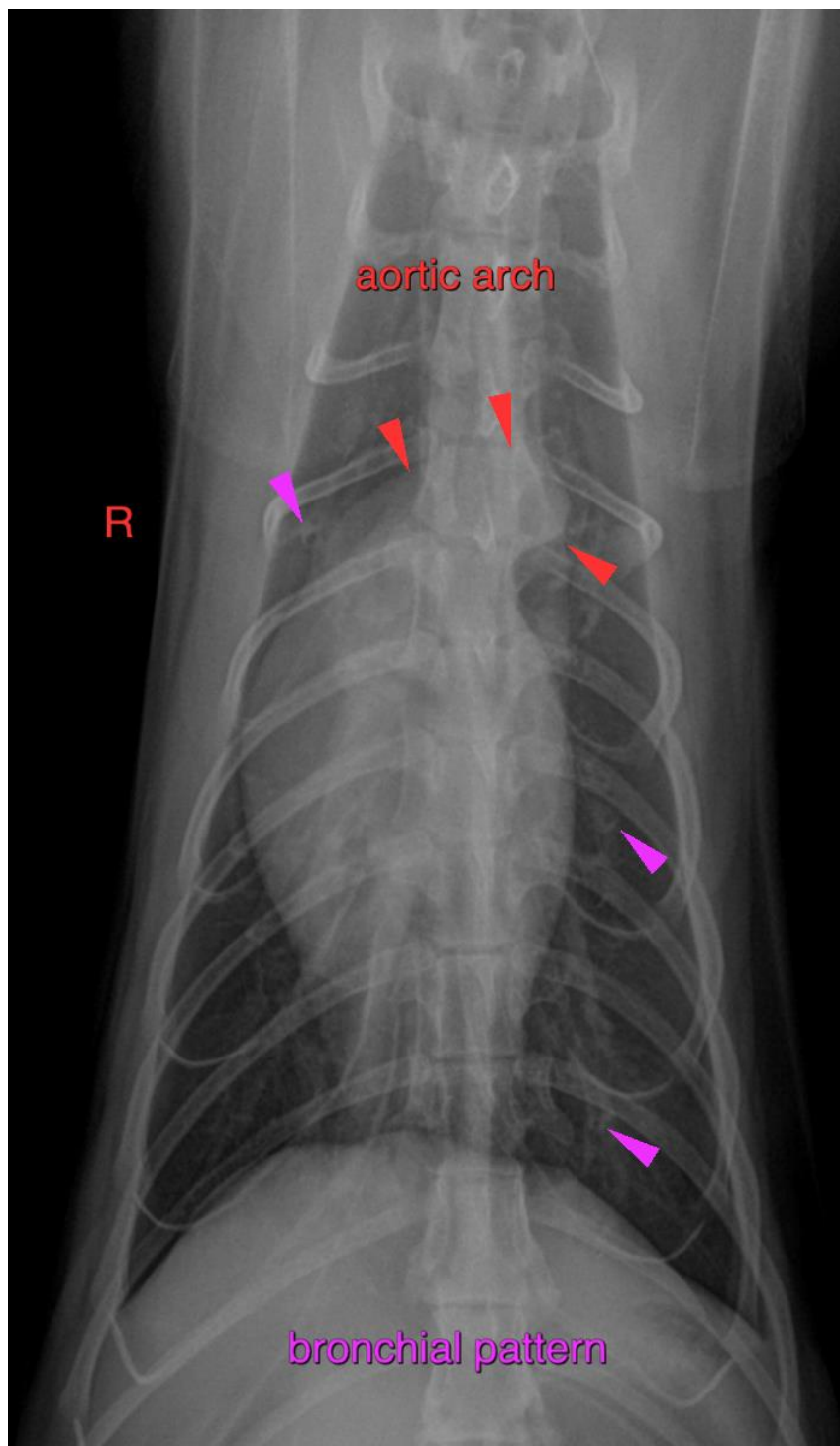
Laura Warren

INVOICE

50680

DATE

3-2-22





PATIENT

Yuki Lucchesi

SPECIES

Feline

BREED

Savannah

SEX

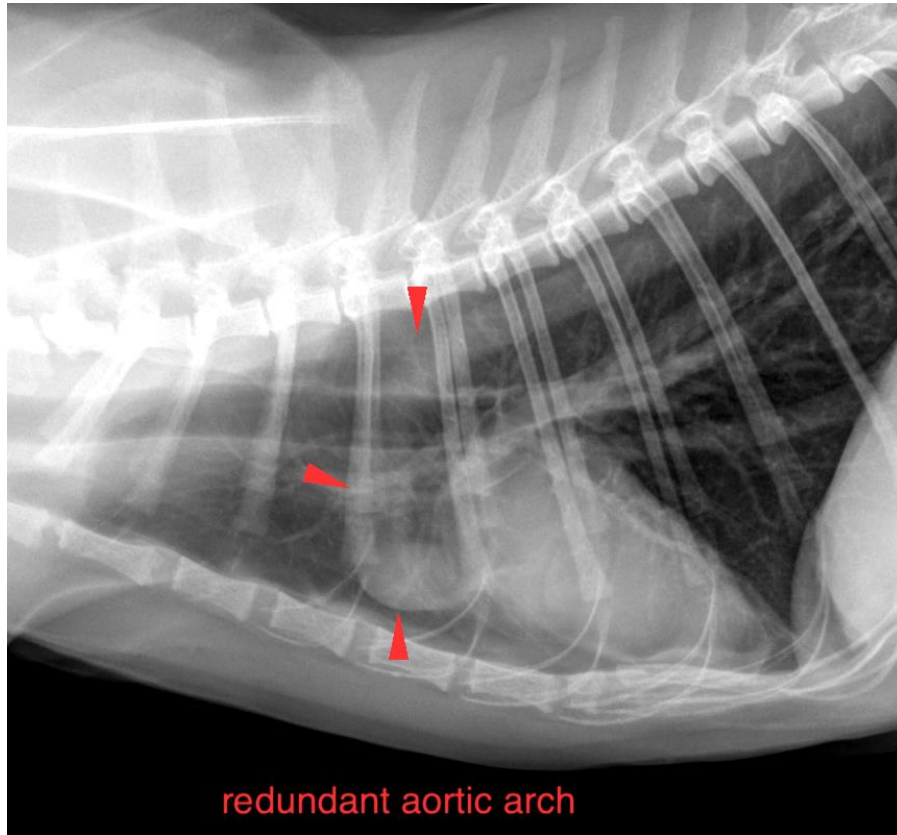
MN

AGE

4.6 Years

INTERPRETED BY

Sebastian Schaub, DVM
Dr. med. vet. DipECVDI



HOSPITAL NAME

Boca Park Animal
Hospital

REFERRING VET

Laura Warren

INVOICE

50680

DATE

3-2-22

The information and recommendations provided are based on the images presented by the referring veterinarian/sonographer. No evaluation can be communicated regarding pathology that was not visible in the image/video clips provided.

Thank you for this referral. If the clinical or image interpretation does not parallel your findings or if I can be of any further assistance please contact me.

Sebastian Schaub, Sebastian Schaub, DVM, Dr. med. vet. DipECVDI
sebast.schaub@gmail.com