



PATIENT PRESENTING CLINICAL SIGNS

Pixie Petersen
 Pixie was brought in today for further evaluation of chronic nasal congestion. She will produce a lot of mucus from both nostrils and tend to both sneeze and reverse sneeze. She has been a bit snorer for years. Rhinoscopy with Dr. Applegate performed about 4 years ago revealed chronic inflammation. Her nasal signs seemed to worsen shortly after rhinoscopy was performed. She presented on an ER for a right sided nose bleed on 2/20. Labwork was unremarkable and she was sent home with cerenia and Yunnan Baiyao. Currently she is sneezing, congested, and blowing snot, but she is not bleeding and has not bled since we saw her. She is both eating and drinking well but she tends to choke when drinking. She has had evidence of nasal bleeding (possibly from her right nostril) 4-5 times over the past few years - smudges around the home from her walking through it, spatter from sneezing, sometimes dripping, occasional clots. She cannot seem to smell well for the past few years - she can't seem to find her food.

SPECIES

Canine

BREED

Papillon

SEX

Female

AGE

12 Years

INTERPRETED BY

Sebastian Schaub, DVM
 Dr. med. vet. DipECVDI

HOSPITAL NAME

Southern Oregon
 Veterinary Specialty
 Center

REFERRING VET

Kim Winters

COMPUTED TOMOGRAPHY OF THE SKULL

A high resolution pre- and post-contrast CT study of the skull is provided for review.

COMPUTED TOMOGRAPHIC FINDINGS

Multiple teeth are absent.

The left nasal cavity is occupied by soft tissue attenuating and heterogeneous contrast enhancing soft tissue material. Advanced destruction of the associated conchal & turbinate structures is seen. The nasal septum is mildly deviated to the right by the mass effect. The left maxillary bone, approximately level with absent 206/207 presents moth eaten osteolytic lesions and mild solid periosteal new bone formation.

Both temporomandibular joints present congruent joint spaces with even subchondral bone surfaces and are considered within normal limits.

Both tympanic bullae are aerated, the mucosal lining is not seen, the bony wall is smooth and thin. The external ear canals are within normal limits.

The brain presents no deviation from normal anatomy and symmetry. The brain parenchyma is homogeneous and within normal limits for attenuation and distribution of contrast enhancement. The ventricular system is non-dilated and symmetric.

The submandibular and medial retropharyngeal lymph nodes are small and elongated with a normal short-to-long-axis-ratio is < 0.5, the attenuation and contrast enhancement pattern is uniform.

INVOICE COMPUTED TOMOGRAPHIC DIAGNOSIS

- 50677
- Soft tissue mass left nasal cavity
 - Multiple teeth are absent

DATE

3-2-22

INTERPRETATION OF THE FINDINGS & FURTHER RECOMMENDATIONS

The left sided nasal soft tissue mass is concerning for low aggressive nasal neoplasia, such as adenocarcinoma, sarcoma, round cell tumor. Due to the low malignant biological imaging



PATIENT

Pixie Petersen

features, adenomatoid polyp, Sticker sarcoma, (mycotic) granuloma are potentials. Recommend rhinoscopy including biopsy for further definition. If neoplastic disease is confirm, the Adam tumor stage is T2.

SPECIES

Canine

BREED

Papillon

SEX

Female

AGE

12 Years

INTERPRETED BY

Sebastian Schaub, DVM
Dr. med. vet. DipECVDI

HOSPITAL NAME

Southern Oregon
Veterinary Specialty
Center

REFERRING VET

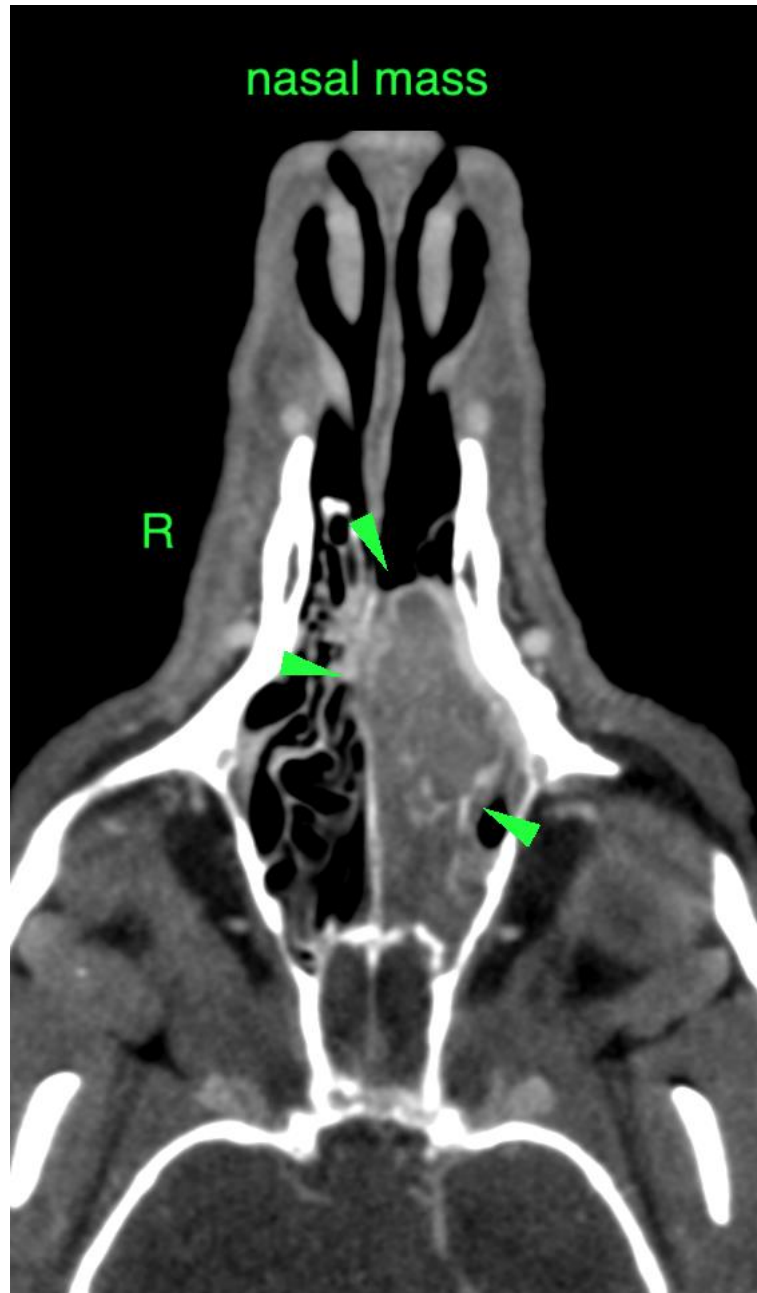
Kim Winters

INVOICE

50677

DATE

3-2-22





PATIENT

Pixie Petersen

SPECIES

Canine

BREED

Papillon

SEX

Female

AGE

12 Years

INTERPRETED BY

Sebastian Schaub, DVM
Dr. med. vet. DipECVDI

HOSPITAL NAME

Southern Oregon
Veterinary Specialty
Center

REFERRING VET

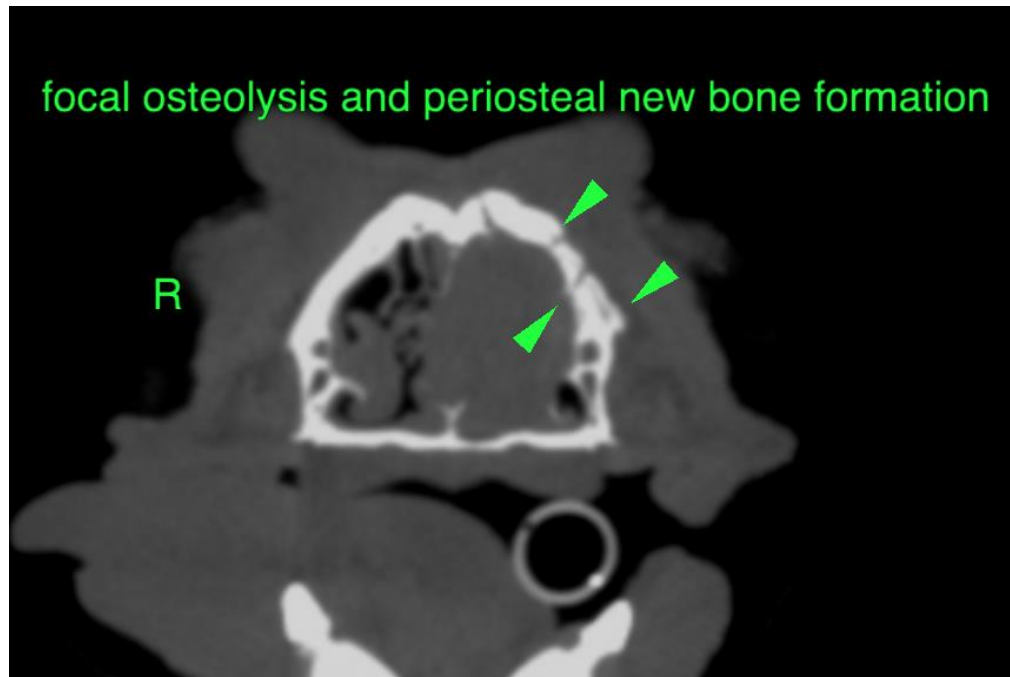
Kim Winters

INVOICE

50677

DATE

3-2-22



The information and recommendations provided are based on the images presented by the referring veterinarian/sonographer. No evaluation can be communicated regarding pathology that was not visible in the image/video clips provided.

Thank you for this referral. If the clinical or image interpretation does not parallel your findings or if I can be of any further assistance please contact me.

Sebastian Schaub, Sebastian Schaub, DVM, Dr. med. vet. DipECVDI
sebast.schaub@gmail.com