



**PATIENT**

Marshall Winter

**PRESENTING CLINICAL SIGNS**

Hops up and down the stairs sometimes. No lameness. He got neutered today and we performed his pelvic radiographs.  
Abnormal PE/Chem/CBC/UA Results: CBC and chemistry WNI

**SPECIES**

Canine

**RADIOGRAPHIC STUDY OF THE PELVIS**

Two radiographs of the pelvis – VD extended & flexed – are provided for review.

**BREED**

Golden Retriever

**RADIOGRAPHIC FINDINGS**

The growth plates are age related visible.

**SEX**

MN

The osseous and surrounding soft tissue structures of the pelvis are within normal limits. Both coxofemoral joints present smooth osseous margins. The femoral heads are well covered by the dorsal acetabular rim. A very mild medial widening of the craniomedial joint space of the coxofemoral joints bilaterally is seen.

**RADIOGRAPHIC DIAGNOSIS**

**AGE**

8 Months

- Normal pelvis & coxofemoral joints

**INTERPRETATION OF THE FINDINGS & FURTHER RECOMMENDATIONS**

**INTERPRETED BY**

Sebastian Schaub, DVM  
Dr. med. vet. DipECVDI

The radiographic study of the pelvis presents without abnormalities.

**HOSPITAL NAME**

Balmy Beach Pet  
Hospital

**REFERRING VET**

Dr. Singh

**INVOICE**

50670

**DATE**

3-2-22



**PATIENT**

Marshall Winter

**SPECIES**

Canine

**BREED**

Golden Retriever

**SEX**

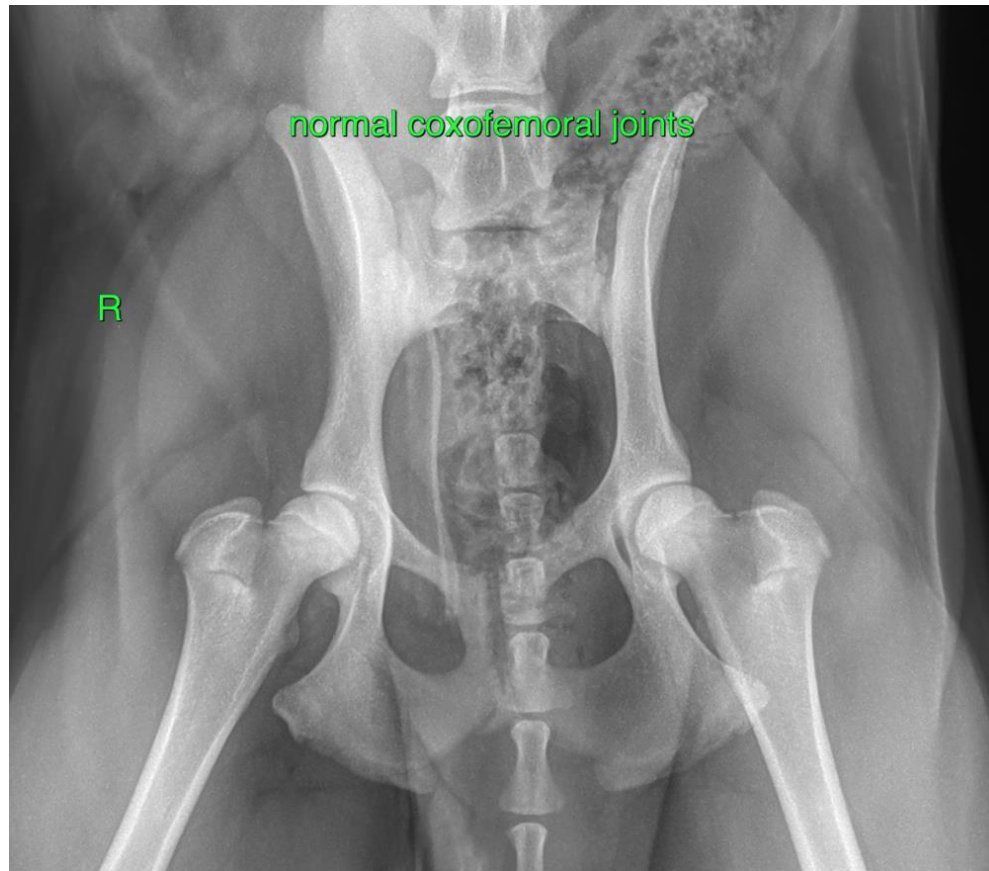
MN

**AGE**

8 Months

**INTERPRETED BY**

Sebastian Schaub, DVM  
Dr. med. vet. DipECVDI



**HOSPITAL NAME**

Balmy Beach Pet  
Hospital

**REFERRING VET**

Dr. Singh

**INVOICE**

50670

**DATE**

3-2-22

**The information and recommendations provided are based on the images presented by the referring veterinarian/sonographer. No evaluation can be communicated regarding pathology that was not visible in the image/video clips provided.**

Thank you for this referral. If the clinical or image interpretation does not parallel your findings or if I can be of any further assistance please contact me.

**Sebastian Schaub**, Sebastian Schaub, DVM, Dr. med. vet. DipECVDI  
sebast.schaub@gmail.com