

**PATIENT**

Bella Greves

PRESENTING CLINICAL SIGNS

presented for standard COHAT.

SPECIES

Canine

COMPUTED TOMOGRAPHY OF THE SKULL

A high resolution pre- and post-contrast CT study of the skull is provided for review.

BREED

Dachshund

COMPUTED TOMOGRAPHIC FINDINGS

The tooth elements 101, 102, 109, 306, 308, 311, 408 and 411 are absent. Triadan 104 presents a mild widening of the periodontal space. Triadan 206 presents advanced resorption of the distal root. Triadan 306 presents with extensive resorption of the crown and roots and small fragments of the crown are seen level with the distal root. Triadan 406 presents with multiple resorptive lesions of the crown and tooth root resorption. The periodontal space of triadan 307&407 is lost.

SEX

FS

The nasal cavity presents the expected aerated spaces between thin & even conchae and turbinates with smooth mucosal lining.

AGE

12 Years

Both temporomandibular joints present congruent joint spaces with even subchondral bone surfaces and are considered within normal limits.

Both tympanic bullae are aerated, the mucosal lining is not seen, the bony wall is smooth and thin. The external ear canals are within normal limits.

INTERPRETED BYSebastian Schaub, DVM
Dr. med. vet. DipECVDI

The submandibular and medial retropharyngeal lymph nodes are small and elongated with a normal short-to-long-axis-ratio is < 0.5, the attenuation pattern is uniform.

COMPUTED TOMOGRAPHIC DIAGNOSIS**HOSPITAL NAME**South Bay Animal
Hospital & Pet Resort

- Dental resorptive lesions 206, 306 and 406
- Periodontal disease 104
- Ankylosis of the tooth roots 307&407
- Multiple absent teeth, see above

REFERRING VET

Dr. Ravinder Atwal

INTERPRETATION OF THE FINDINGS & FURTHER RECOMMENDATIONS

The CT study presents evidence of multifocal chronic periodontal disease with resorptive dental lesions and ankylosis of triadan 307&407. A complete dental workup has already been performed.

INVOICE

50657

DATE

3-2-22



PATIENT

Bella Greves

SPECIES

Canine

BREED

Dachshund

SEX

FS

AGE

12 Years

INTERPRETED BY

Sebastian Schaub, DVM
Dr. med. vet. DipECVDI

HOSPITAL NAME

South Bay Animal
Hospital & Pet Resort

REFERRING VET

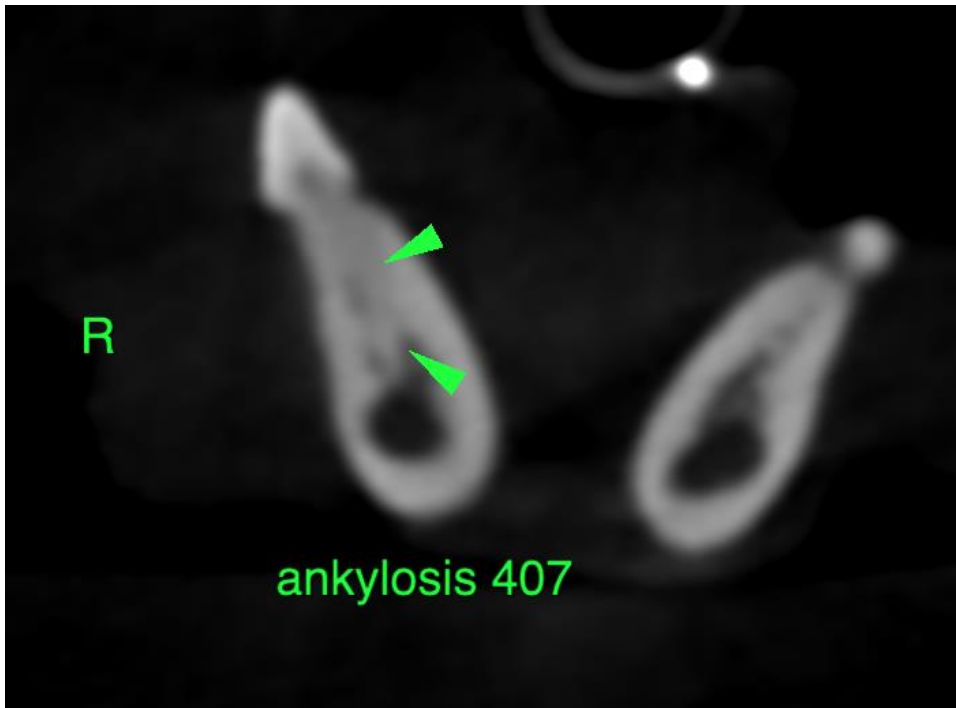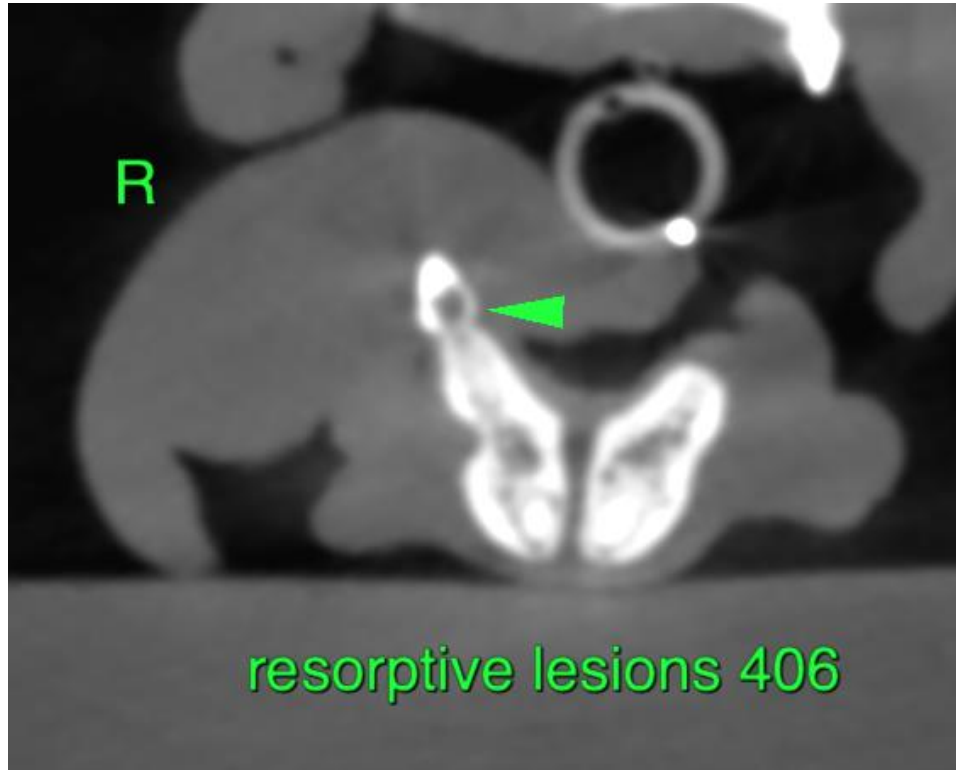
Dr. Ravinder Atwal

INVOICE

50657

DATE

3-2-22





PATIENT

Bella Greves

The information and recommendations provided are based on the images presented by the referring veterinarian/sonographer. No evaluation can be communicated regarding pathology that was not visible in the image/video clips provided.

SPECIES

Canine

Thank you for this referral. If the clinical or image interpretation does not parallel your findings or if I can be of any further assistance please contact me.

BREED

Dachshund

Sebastian Schaub, Sebastian Schaub, DVM, Dr. med. vet. DipECVDI
sebast.schaub@gmail.com

SEX

FS

AGE

12 Years

INTERPRETED BY

Sebastian Schaub, DVM
Dr. med. vet. DipECVDI

HOSPITAL NAME

South Bay Animal
Hospital & Pet Resort

REFERRING VET

Dr. Ravinder Atwal

INVOICE

50657

DATE

3-2-22