



PATIENT

Driggs Clark

SPECIES

Canine

BREED

Lab

SEX

Neutered Male

AGE

7 Years

WEIGHT

75.3 pounds

INTERPRETED BY

Sebastian Schaub, DVM
Dr. med. vet. DipECVDI

IMAGING PERFORMED BY

Amanda Mazzante
CVT

HOSPITAL NAME

Williamsport West
Veterinary Hospital

REFERRING VET

Dr. Jenni Slotterback
DVM

INVOICE

14500

DATE

03/19/26

PRESENTING CLINICAL SIGNS

- Left elbow arthroscope done in August 2025. Findings included moderate inflammation and synovitis. Also found damaged bone on the medial coronoid process that was non-viable and was removed.
- Has been having pain since about 6 weeks prior to the arthroscope. Limping has persisted since then
- Acupuncture and therapeutic laser has been done regularly since November, some improvement seen but not entirely.
- CT done to investigate further issues with elbow but also to investigate if any issues are present in the shoulder or carpus

COMPUTED TOMOGRAPHIC STUDY OF THE FRONT LIMBS

A high resolution pre- and post-contrast CT study of the front limbs is provided for review.

COMPUTED TOMOGRAPHIC FINDINGS

At the lateral surface of the major tubercle of the right humerus – in the insertion of the infraspinatus tendon – a shallow irregular concave depression is appreciated. Along the right supraspinatus tendon and in the distal aspect of the right infraspinatus muscle, punctuate mineralization are visible. Otherwise, both shoulder joints present smooth margins of the periarticular bones and no abnormalities of the surrounding soft tissue structures.

The periarticular bones of both elbow joints present mild (right) to moderate (left) new bone formation. The cranial tip of the medial coronoid process of the left elbow joint is irregular and has a heterogeneous density. The tip of the medial coronoid process of the right elbow joint is mildly irregular. Post contrast administration the synovial lining of the left elbow joint is moderately thickened and increased contrast enhancing.

The osseous and surrounding soft tissue structures of the carpal joints are unremarkable.

COMPUTED TOMOGRAPHIC DIAGNOSIS

- History of arthroscopy left elbow joint due to coronoid disease
- Moderate osteoarthritis left elbow joint
- Synovitis and joint effusion left elbow joint
- Possible coronoid disease right elbow joint
- Mild osteoarthritis right elbow joint
- Insertion desmopathy right infraspinatus tendon with osseous remodeling and metaplasia
- Normal shoulder joints, but the above mentioned insertional desmopathy
- Normal carpal joints

INTERPRETATION OF THE FINDINGS & FURTHER RECOMMENDATIONS

The main finding is the degenerative joint disease of the left elbow joint due to the history of elbow dysplasia – the appreciated degenerative changes are irreversible and are likely to contribute to the clinical signs. A synovial tap of the left elbow joint can be performed to rule out septic arthritis.

No additional clinically relevant abnormalities are appreciated along the left front limb.

The desmopathy of the right infraspinatus tendon is considered incidental.



PATIENT

Driggs Clark

SPECIES

Canine

BREED

Lab

SEX

Neutered Male

AGE

7 Years

WEIGHT

75.3 pounds

INTERPRETED BY

Sebastian Schaub, DVM
Dr. med. vet. DipECVDI

IMAGING PERFORMED BY

Amanda Mazzante
CVT

HOSPITAL NAME

Williamsport West
Veterinary Hospital

REFERRING VET

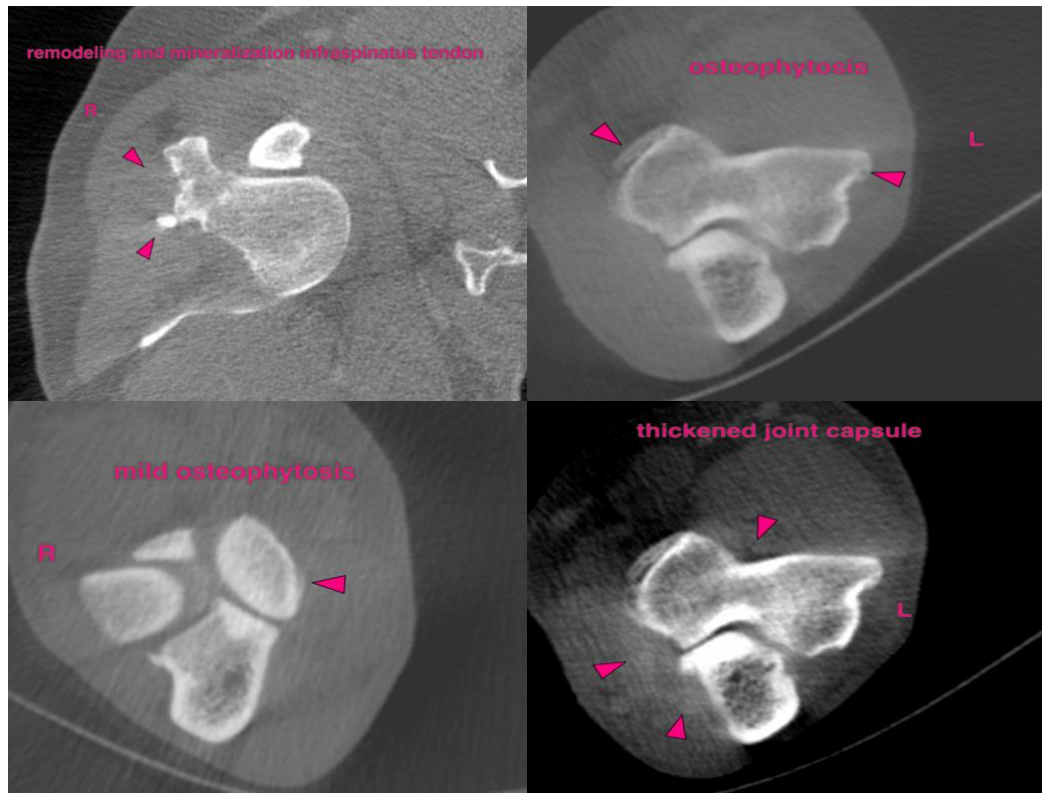
Dr. Jenni Slotterback
DVM

INVOICE

14500

DATE

03/19/26



The information and recommendations provided are based on the images presented by the referring veterinarian/sonographer. No evaluation can be communicated regarding pathology that was not visible in the image/video clips provided.

Thank you for this referral. If the clinical or image interpretation does not parallel your findings or if I can be of any further assistance please contact me.

Sebastian Schaub, DVM, Dr. med. vet. DipECVDI
info@sonopath.com