



PATIENT

Dingo Howard

SPECIES

Canine

BREED

Rottweiler

SEX

Spayed Female

AGE

5 Years 2 Months

WEIGHT

72.4

INTERPRETED BY

Sebastian Schaub, DVM
Dr. med. vet. DipECVDI

IMAGING PERFORMED BY

Dr. Sarah Green

HOSPITAL NAME

Healing Spirit Animal
Wellness

REFERRING VET

Dr. Sarah Green

INVOICE

14511

DATE

3/19/26

PRESENTING CLINICAL SIGNS

Several month history of regurgitation after eating, gastroesophageal reflux suspected, partial improvement noted with Omeprazole. megaesophagus not appreciated on thoracic radiographs

has more recently been ingesting rocks/ gravel

Abnormal PE/Chem/CBC/UA Results: PE unremarkable

FLUOROSCOPIC SWALLOWING STUDY

A positive contrast swallowing study of the neck and thorax is provided for review – the fluoroscopy has only been performed in a DV projection.

FLUOROSCOPY FINDINGS

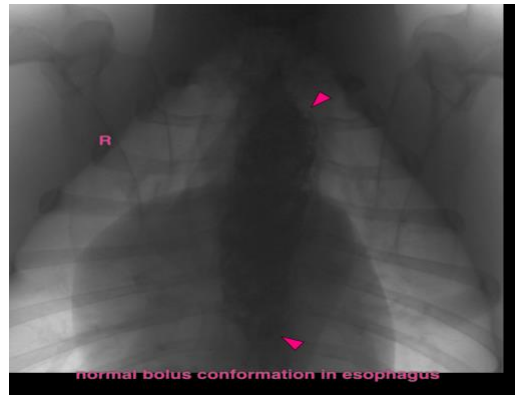
The esophagus presents a physiological motility. The boluses are propelled into the stomach by primary and secondary waves. The boluses in the esophagus present a physiological shape with a convex caudal border and is tapering in the cranial aspect. The boluses are propelled by primary or secondary waves through the cardia into the stomach. No reflux of gastric content into the esophagus is appreciated.

FLUOROSCOPY DIAGNOSIS & THERAPEUTIC RECOMMENDATIONS

- Normal swallowing study, no evidence of esophageal dysmotility nor gastro-esophageal reflux

INTERPRETATION OF THE FINDINGS & FURTHER RECOMMENDATIONS

The fluoroscopic study reveals no signs of esophageal dysmotility.



The information and recommendations provided are based on the images presented by the referring veterinarian/sonographer. No evaluation can be communicated regarding pathology that was not visible in the image/video clips provided.

Thank you for this referral. If the clinical or image interpretation does not parallel your findings or if I can be of any further assistance please contact me.

Sebastian Schaub, DVM, Dr. med. vet. DipECVDI
info@sonopath.com