



PATIENT

Bullet Overy

SPECIES

Canine

BREED

Labrador Retriever

SEX

Neutered Male

AGE

6.5 Years

WEIGHT

85 pounds

INTERPRETED BY

Sebastian Schaub, DVM
Dr. med. vet. DipECVDI

IMAGING PERFORMED BY

Kim & Katlin

HOSPITAL NAME

Animal Clinic
Northview

REFERRING VET

Dr. Randall V.
Hutchinson DVM

INVOICE

14505

DATE

03/19/26

PRESENTING CLINICAL SIGNS

- poss seizure or vestibular event
- evaluating brain and ears for any underlying pathology

COMPUTED TOMOGRAPHIC STUDY OF THE SKULL

A high resolution pre- and post-contrast CT study of the skull is provided for review.

COMPUTED TOMOGRAPHIC FINDINGS

The pictured parts of the dentition are complete and unremarkable in all jaw quadrants.

The nasal cavity presents the expected aerated spaces between thin & even conchae and turbinates with smooth mucosal lining.

Both temporomandibular joints present congruent joint spaces with even subchondral bone surfaces and are considered within normal limits.

Both tympanic bullae are aerated, the mucosal lining is not seen, the bony wall is smooth and thin. The external ear canals are within normal limits.

The brain presents no deviation from normal anatomy and symmetry. The brain parenchyma is homogeneous and within normal limits for attenuation and distribution of contrast enhancement. The ventricular system is non-dilated and symmetric.

The submandibular and medial retropharyngeal lymph nodes are small and elongated with a normal short-to-long-axis-ratio is < 0.5, the attenuation and contrast enhancement pattern is uniform.

COMPUTED TOMOGRAPHIC DIAGNOSIS

- Normal brain
- Normal skull
- No evidence of otitis media or interna

INTERPRETATION OF THE FINDINGS & FURTHER RECOMMENDATIONS

In the present study of the brain there is no evidence of macromorphological disease and an underlying cause for described neurological clinical signs cannot be specified.

If not yet done so the workup should be complemented by examination of CSF and complete bloodwork to screen for brain disease that is not necessarily associated with structural changes of the brain parenchyma and rule out hepatoencephalopathy and other systemic illness. In case of the strong clinical suspicion of structural intraparenchymal changes an MRI may be considered.



PATIENT

Bullet Overy

SPECIES

Canine

BREED

Labrador Retriever

SEX

Neutered Male

AGE

6.5 Years

WEIGHT

85 pounds

INTERPRETED BY

Sebastian Schaub, DVM
Dr. med. vet. DipECVDI

IMAGING PERFORMED BY

Kim & Katlin

HOSPITAL NAME

Animal Clinic
Northview

REFERRING VET

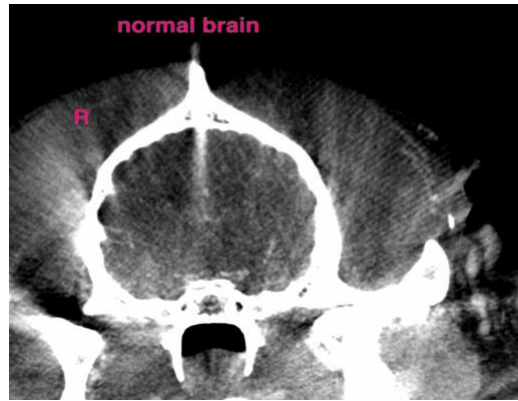
Dr. Randall V.
Hutchinson DVM

INVOICE

14505

DATE

03/19/26



The information and recommendations provided are based on the images presented by the referring veterinarian/sonographer. No evaluation can be communicated regarding pathology that was not visible in the image/video clips provided.

Thank you for this referral. If the clinical or image interpretation does not parallel your findings or if I can be of any further assistance please contact me.

Sebastian Schaub, DVM, Dr. med. vet. DipECVDI
info@sonopath.com