



PATIENT

Sammy Reichmuth

PRESENTING CLINICAL SIGNS

Coughing fits last few weeks. No heart murmur noted, lungs sounds normal. Had similar issue in Feb 2021. Cough worse with activity. Temaril -p & hydrocodone has helped in the past

SPECIES

Canine

RADIOGRAPHIC STUDY OF THE THORAX

Radiographs of the thorax in two imaging planes are provided for review.

BREED

Chihuahua Mix

RADIOGRAPHIC FINDINGS

The body condition score is 7/9.

The surrounding bony structures are within normal limits.

SEX

Spayed Female

The extrathoracic soft tissues present homogeneous without abnormalities.

The heart is of normal size and shape, there is no evidence of cardiac chamber or vascular enlargement. The pulmonary vasculature is within normal limits.

AGE

6 Years, 8 Months

The cranial mediastinum presents the expected soft tissue opacity. The mediastinal width is less than twice the width of the vertebral column at the same level.

INTERPRETED BY

Sebastian Schaub, DVM
Dr. med. vet. DipECVDI

The trachea is normal in diameter and presents the anticipated course. The luminal outline of the trachea is smooth.

The lung parenchyma presents a generalized mild to moderate ground glass opacification, blurring the pulmonary vasculature. Mild peribronchial cuffing is noted.

HOSPITAL NAME

Reid Veterinary
Hospital

The diaphragm is well delineated with even surface and the expected mild cranial bulging of the diaphragmatic cupola.

RADIOGRAPHIC DIAGNOSIS

REFERRING VET

Diane Heider

- Broncho-interstitial lung pattern

INTERPRETATION OF THE FINDINGS & FURTHER RECOMMENDATIONS

INVOICE

51023

The radiographic findings are compatible with bronchitis and pneumonitis – although the interstitial pattern might be accentuated by the mild obesity. Immune mediated broncho pneumopathy (e.g. lymphocytic plasmocytic, eosinophilic, mixed) is considered more likely than infectious bronchitis – viral, bacterial, parasitic.

Bronchoscopy including a broncho-alveolar lavage might be used as advanced diagnostic test.

DATE

3-18-22



PATIENT

Sammy Reichmuth

SPECIES

Canine

BREED

Chihuahua Mix

SEX

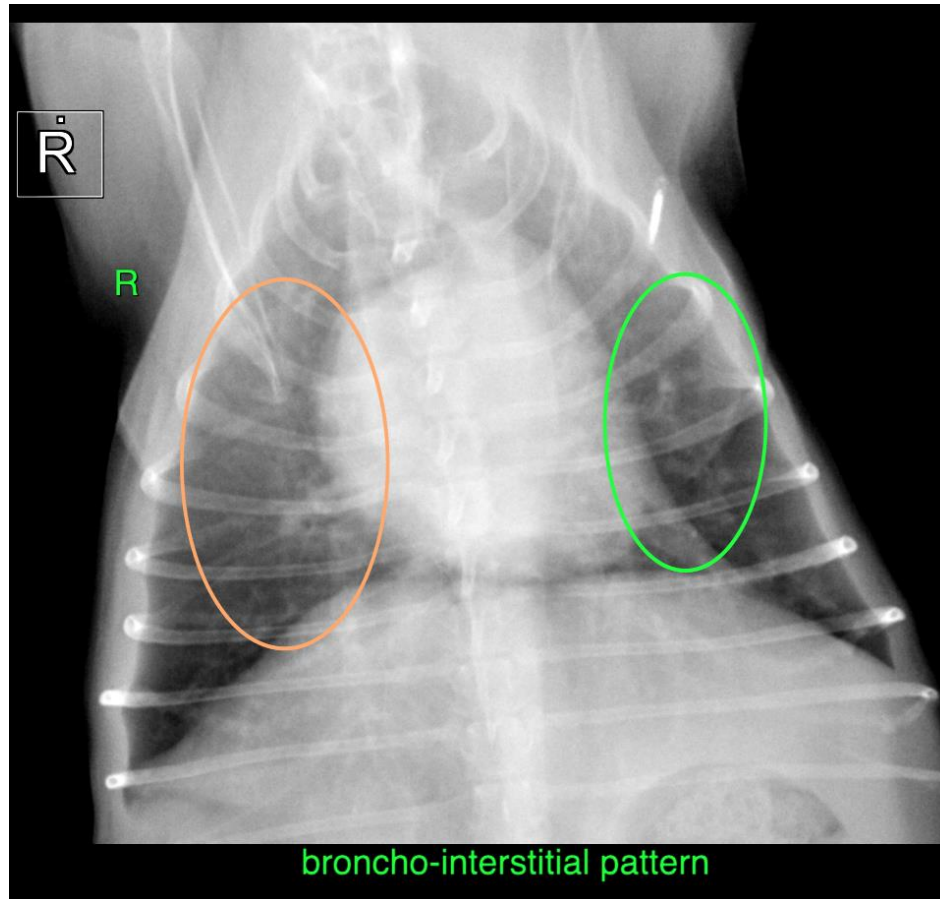
Spayed Female

AGE

6 Years, 8 Months

INTERPRETED BY

Sebastian Schaub, DVM
Dr. med. vet. DipECVDI



HOSPITAL NAME

Reid Veterinary
Hospital

REFERRING VET

Diane Heider

INVOICE

51023

DATE

3-18-22

The information and recommendations provided are based on the images presented by the referring veterinarian/sonographer. No evaluation can be communicated regarding pathology that was not visible in the image/video clips provided.

Thank you for this referral. If the clinical or image interpretation does not parallel your findings or if I can be of any further assistance please contact me.

Sebastian Schaub, Sebastian Schaub, DVM, Dr. med. vet. DipECVDI
sebast.schaub@gmail.com