



PATIENT PRESENTING CLINICAL SIGNS

Abby Fritz History: Presented for routine periodontal therapy. No concerns at home. No sneezing, nasal discharge.

SPECIES Abnormal PE/Chem/CBC/UA Results: Grade 2 periodontal disease. PE unremarkable. No lab value concerns.

Canine

COMPUTED TOMOGRAPHIC STUDY OF THE SKULL

BREED A high resolution plain CT study of the splanchnocranium is provided for review.

Vizsla

COMPUTED TOMOGRAPHIC FINDINGS

Triadan 101, 201, 305 and 405 are absent.

SEX

Spayed Female

The nasal cavity presents the expected aerated spaces between thin & even conchae and turbinates with smooth mucosal lining. In the right nasal cavity, a well-defined, nodular homogeneous mineralized thickening of a conchae is seen, measuring 5 mm in diameter. In the right nasal cavity, focal nodular osseous thickening of the turbinalia is seen.

AGE

11 Years 6 Months

COMPUTED TOMOGRAPHIC DIAGNOSIS

- Benign osteoproliferative ossifying lesion left conchae and right turbinates
- Absent triadan 101, 201, 305 and 405

INTERPRETED BY

Sebastian Schaub,
DVM Dr. med. vet.
DipECVDI

INTERPRETATION OF THE FINDINGS & FURTHER RECOMMENDATIONS

The mineralizing lesions in the nasal cavity are highly suggestive for osteoma or ossifying fibroma. The focal mild osseous thickening of the right turbinalia can present osseous turbinate hyperplasia as differential. The lesions are considered benign and are likely incidental findings.

HOSPITAL NAME

Gentle Doctor AH

REFERRING VET

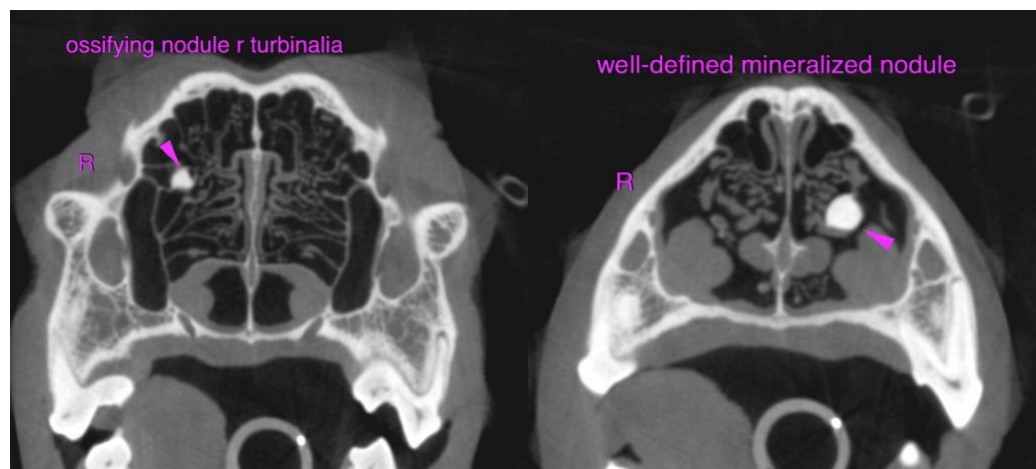
Adrienne Kanne, DVM

INVOICE

21694

DATE

3/17/23





PATIENT

Abby Fritz

The information and recommendations provided are based on the images presented by the referring veterinarian/sonographer. No evaluation can be communicated regarding pathology that was not visible in the image/video clips provided.

SPECIES

Canine

Thank you for this referral. If the clinical or image interpretation does not parallel your findings or if I can be of any further assistance please contact me.

BREED

Vizsla

Sebastian Schaub, Sebastian Schaub, DVM, Dr. med. vet. DipECVDI
sebast.schaub@gmail.com

SEX

Spayed Female

AGE

11 Years 6 Months

INTERPRETED BY

Sebastian Schaub,
DVM Dr. med. vet.
DipECVDI

HOSPITAL NAME

Gentle Doctor AH

REFERRING VET

Adrienne Kanne, DVM

INVOICE

21694

DATE

3/17/23