



PATIENT PRESENTING CLINICAL SIGNS

Snowflake Cagill Incompletely excised soft tissue sarcoma on sternum. Previous surgeries to remove it and pet had radiation therapy.

SPECIES COMPUTED TOMOGRAPHY OF THE THORAX AND ABDOMEN

Feline A high resolution pre- and post-contrast CT study of the thorax and abdomen are provided for review.

COMPUTED TOMOGRAPHIC FINDINGS

BREED

Thorax

DSH

At the right cranioventral thoracic wall, an ovoid shaped, homogeneous soft tissue attenuating and post contrast heterogeneous contrast enhancing and central mild hypoattenuating bilobed mass is seen along the level of the manubrium sterni up to the level of the third sternebra. The mass is measuring 4.4 x 5.4 x 2.3 cm in size.

SEX

Neutered Male

Multifocal mild spondylosis formation is seen along the caudal thoracic spine.

AGE

9 Years

The sternal, cranial mediastinal and tracheobronchial lymph nodes are small elongated with a normal short-to-long-axis-ratio is < 0.5, the attenuation and contrast enhancement pattern is uniform and considered within normal limits.

The cardiovascular structures including the pulmonary vasculature are within normal limits.

INTERPRETED BY

Sebastian Schaub, DVM
Dr. med. vet. DipECVDDI

The bronchial tree presents with regular branching and tapers uniformly towards the periphery as expected, the bronchial walls are thin and smooth. The bronchus-to-artery ratio is within normal limits.

The lung parenchyma presents the expected architecture and attenuation behavior.

HOSPITAL NAME

Mobile Pet Imaging

Small incidental gas pockets are seen within the esophageal lumen, there is no evidence of abnormal dilation.

Abdomen

REFERRING VET

Meaux

The serosal fat presents normal attenuation behavior. There is no evidence of peritoneal effusion or peritonitis.

Both kidneys present within normal limits for size, shape and organ architecture. After contrast administration a bilaterally symmetric and uniform nephro- and pyelogram is noted.

INVOICE

50994

The adrenal glands are within normal limits for size, shape and organ architecture.

Both liver and spleen present with normal shape, even surface, uniformly attenuating parenchyma and homogeneous contrast enhancement, unremarkable.

DATE

3-17-22

The pancreas is evenly contoured, the pancreatic parenchyma is homogeneous and presents uniform contrast enhancement.



PATIENT Post contrast administration, the outer layer of the wall of the small intestinal loops is prominent.

Snowflake Cagill The bony and surrounding soft tissue structures reveal no abnormalities.

COMPUTED TOMOGRAPHIC DIAGNOSIS

SPECIES

Feline

- History of sarcoma right cranioventral thoracic wall with reoccurrence of soft tissue mass right cranioventral thoracic wall without signs of invasion of the thorax
- Suspect prominent muscularis layer of the small intestinal tract
- Spondylosis deformans
- No evidence of pulmonary metastatic disease

BREED

DSH

INTERPRETATION OF THE FINDINGS & FURTHER RECOMMENDATIONS

SEX

Neutered Male

The soft tissue mass at the right cranialateral thoracic wall is consistent with the history of reoccurrence of sarcoma. I suppose that complete surgical excision would warrant radical surgery with amputation of the right front limb and partial resection of the associated segments of the thoracic wall (up to the 3rd or 4th intercostal space).

AGE

9 Years

The prominent muscular layer of the small intestinal loops can be a sequela to chronic inflammation (e.g. lymphocytic plasmocytic, eosinophilic), hyperthyroidism or round cell neoplasia.

INTERPRETED BY

Sebastian Schaub, DVM
Dr. med. vet. DipECVDI

HOSPITAL NAME

Mobile Pet Imaging

REFERRING VET

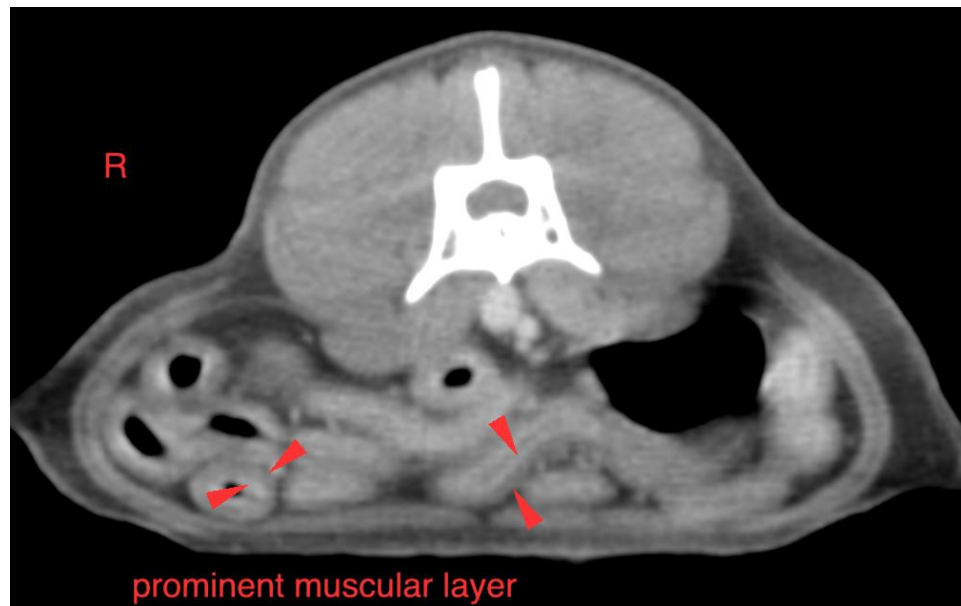
Meaux

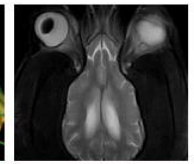
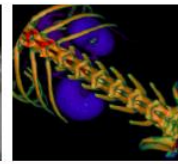
INVOICE

50994

DATE

3-17-22





PATIENT

Snowflake Cagill

SPECIES

Feline

BREED

DSH

SEX

Neutered Male

AGE

9 Years

INTERPRETED BY

Sebastian Schaub, DVM
Dr. med. vet. DipECVDI

HOSPITAL NAME

Mobile Pet Imaging

REFERRING VET

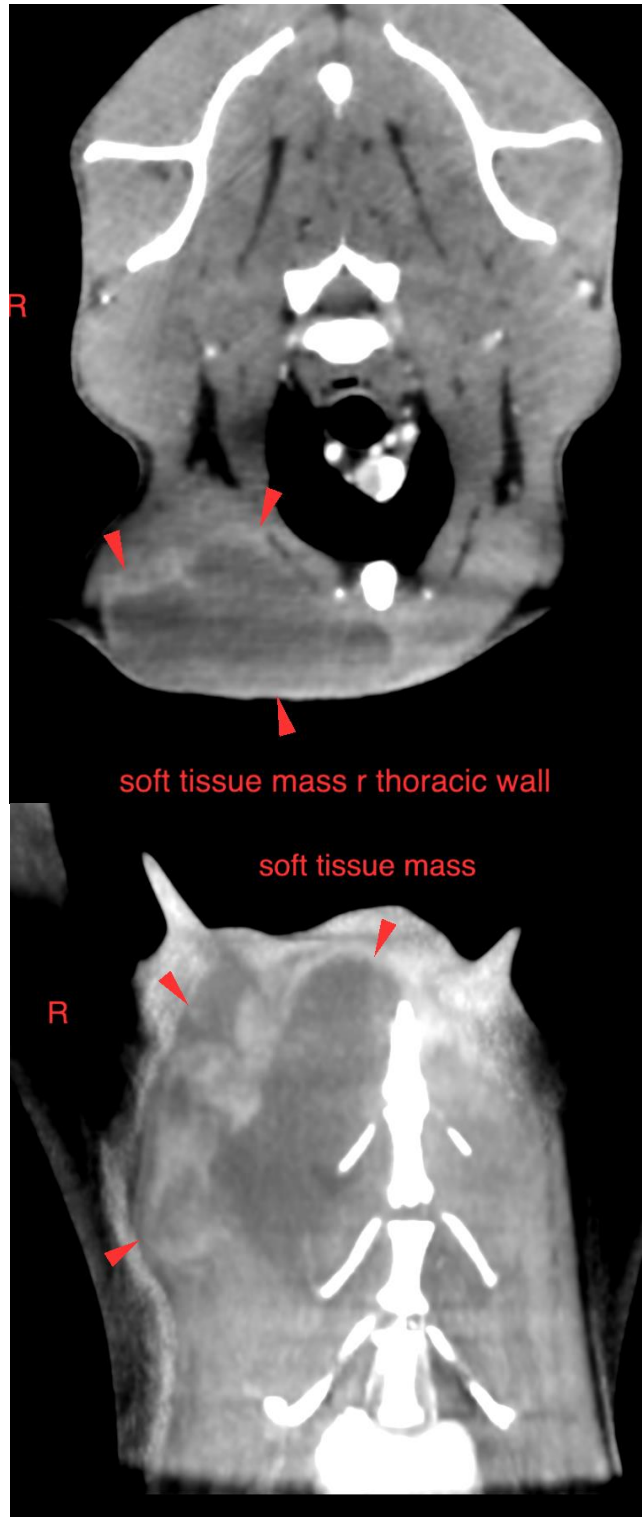
Meaux

INVOICE

50994

DATE

3-17-22





PATIENT

Snowflake Cagill

SPECIES

Feline

The information and recommendations provided are based on the images presented by the referring veterinarian/sonographer. No evaluation can be communicated regarding pathology that was not visible in the image/video clips provided.

BREED

DSH

Thank you for this referral. If the clinical or image interpretation does not parallel your findings or if I can be of any further assistance please contact me.

Sebastian Schaub, Sebastian Schaub, DVM, Dr. med. vet. DipECVDI
sebast.schaub@gmail.com

SEX

Neutered Male

AGE

9 Years

INTERPRETED BY

Sebastian Schaub, DVM
Dr. med. vet. DipECVDI

HOSPITAL NAME

Mobile Pet Imaging

REFERRING VET

Meaux

INVOICE

50994

DATE

3-17-22