



**PATIENT**

Nova Ruben

**PRESENTING CLINICAL SIGNS**

Limping on right hind leg for a week

**SPECIES**

K9

**RADIOGRAPHIC STUDY OF THE THORACIC&LUMBAR SPINE**

Radiographs of the thoracic & lumbar spine in two imaging planes are provided for review.

**BREED**

German Shepherd

**RADIOGRAPHIC FINDINGS**

Generalized mild to moderate spondylosis formation is seen along the pictured parts of the caudal thoracic and the lumbar spine.

Superimposed on the ventral aspect of the neuroforamina L1/L2, L2/L3 and L7/S1, convex shaped mineralized material is seen.

**SEX**

FS

**RADIOGRAPHIC DIAGNOSIS**

- Advanced ventral & lateral spondylosis formation thoracic and lumbar spine
- Mineralized material superimposed on neuroforamina L1/L2, L2/L3 and L7/S1

**AGE**

7 Years

**INTERPRETATION OF THE FINDINGS & FURTHER RECOMMENDATIONS**

There are moderate degenerative changes of the thoracic & lumbar spine. The mineralized material superimposed on multiple neuroforamina of the lumbar spine can present lateral spondylosis formation or mineralized disc material protruding into the vertebral canal.

Lateralized intervertebral disc protrusion can be a source for lameness – cross-sectional imaging is warranted in case of strong suspicion for compressive myelopathy.

**INTERPRETED BY**

Sebastian Schaub, DVM  
Dr. med. vet. DipECVDI

**HOSPITAL NAME**

Blairstown Animal  
Hospital

**REFERRING VET**

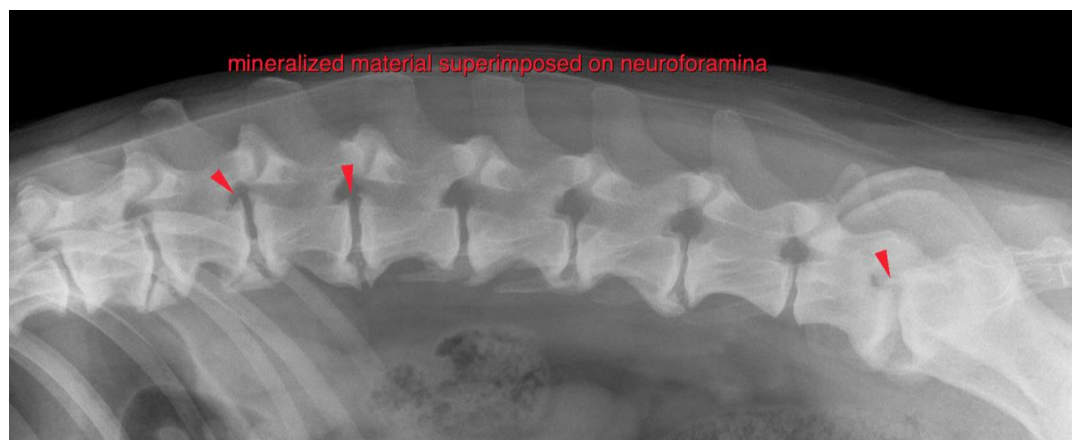
Dr. Clegg

**INVOICE**

50997

**DATE**

3-17-22





**PATIENT**

Nova Ruben

The information and recommendations provided are based on the images presented by the referring veterinarian/sonographer. No evaluation can be communicated regarding pathology that was not visible in the image/video clips provided.

Thank you for this referral. If the clinical or image interpretation does not parallel your findings or if I can be of any further assistance please contact me.

**SPECIES**

K9

**Sebastian Schaub**, Sebastian Schaub, DVM, Dr. med. vet. DipECVDI  
sebast.schaub@gmail.com

**BREED**

German Shepherd

**SEX**

FS

**AGE**

7 Years

**INTERPRETED BY**

Sebastian Schaub, DVM  
Dr. med. vet. DipECVDI

**HOSPITAL NAME**

Blairstown Animal  
Hospital

**REFERRING VET**

Dr. Clegg

**INVOICE**

50997

**DATE**

3-17-22