



PATIENT PRESENTING CLINICAL SIGNS

Apollo Rivera Shunt hunt. Elevated bile acids, Hx of ataxia and drooling. Uroliths. Seen by internist, previous CT scan inconclusive. Under medical management with diet and medications.

SPECIES

Canine

Abnormal PE/Chem/CBC/UA Results: Total Protein 5.1, Alb 2.6, ALP 183, AST 68 Bile acids pre: 275, post 398 Previous abdominal ultrasound: there was a mild - moderate volume of gas and thus a complete study could not be performed, there were 3-4 small stones in the urinary bladder, enlargement of both kidneys, and increase turbulence of blood flow around the hilus of the liver (where all the blood vessels enter)

BREED

French Bulldog

COMPUTED TOMOGRAPHY OF THE ABDOMEN

A high resolution pre- and post-contrast CT study of the abdomen is provided for review.

COMPUTED TOMOGRAPHIC FINDINGS

SEX

Intact Male

The serosal fat presents normal attenuation behavior. There is no evidence of peritoneal effusion or peritonitis.

AGE

11 Months

Both kidneys present within normal limits for size, shape and organ architecture. A mild to moderate amount of mineral attenuating material is associated with the renal pelvis bilaterally. After contrast administration a bilaterally symmetric and uniform nephro- and pyelogram is noted. Three small (<1 mm) mineral attenuating calculi are seen on the ventral urinary bladder wall.

The adrenal glands are within normal limits for size, shape and organ architecture.

INTERPRETED BY

Sebastian Schaub, DVM
Dr. med. vet. DipECVDI

The spleen presents with normal shape, even surface, uniformly attenuating parenchyma and homogeneous contrast enhancement, unremarkable.

The hepatic volume is moderately decreased. The hepatic parenchyma is uniform soft tissue attenuating and contrast enhancing.

HOSPITAL NAME

Mobile Pet Imaging

The portal vein presents a normal order of its tributary veins. Originating from the right medial intrahepatic branch of the portal vein, a short anomalous vascular connection with the left hepatic vein is visible, measuring approximately 9 mm in diameter. The right lateral intrahepatic branch of the portal vein presents a significantly decreased diameter, and the left intrahepatic branch is not appreciated.

REFERRING VET

Meaux

The pancreas is evenly contoured, the pancreatic parenchyma is homogeneous and presents uniform contrast enhancement.

INVOICE

50993

The position, delineation, wall and content of the gastrointestinal tract are considered within normal limits throughout.

The bony and surrounding soft tissue structures reveal no abnormalities.

COMPUTED TOMOGRAPHIC DIAGNOSIS

DATE

3-16-22

- Single congenital intrahepatic portosystemic shunt, central divisional shunt
- Secondary nephrolithiasis and cystolithiasis – likely ammonium urate
- Microhepatica



PATIENT INTERPRETATION OF THE FINDINGS & FURTHER RECOMMENDATIONS

Apollo Rivera The findings are consistent with a congenital single intrahepatic central divisional portosystemic shunt. Hepatic encephalopathy is a potential cause for the neurological clinical signs.

SPECIES Either interventional shunt closure or a surgical technique, using a slow progressive closure technique (coil, ameroid constrictor) is the therapy of choice. Empirical treatment until surgery along with feeding of a hepatic diet is recommended.
Canine

BREED

French Bulldog

SEX

Intact Male

AGE

11 Months

INTERPRETED BY

Sebastian Schaub, DVM
Dr. med. vet. DipECVDI

HOSPITAL NAME

Mobile Pet Imaging

REFERRING VET

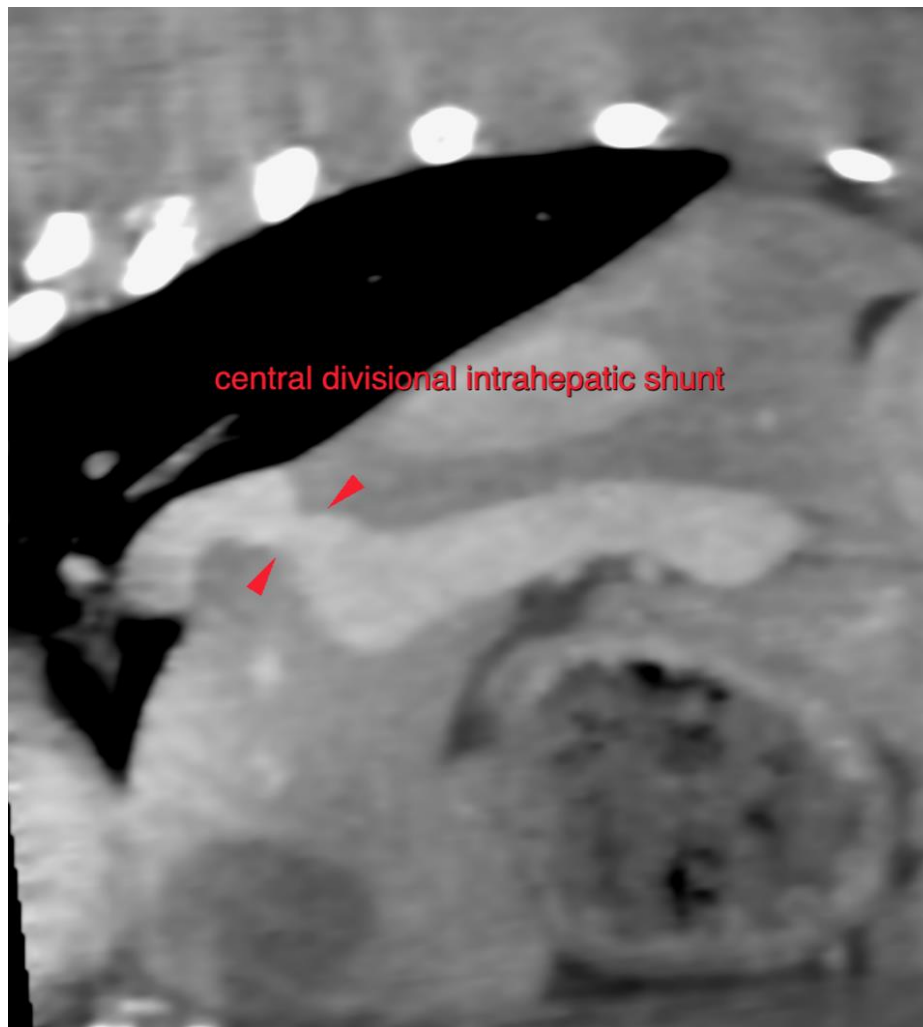
Meaux

INVOICE

50993

DATE

3-16-22





PATIENT

Apollo Rivera

SPECIES

Canine

BREED

French Bulldog

SEX

Intact Male

AGE

11 Months

INTERPRETED BY

Sebastian Schaub, DVM
Dr. med. vet. DipECVDI

HOSPITAL NAME

Mobile Pet Imaging

REFERRING VET

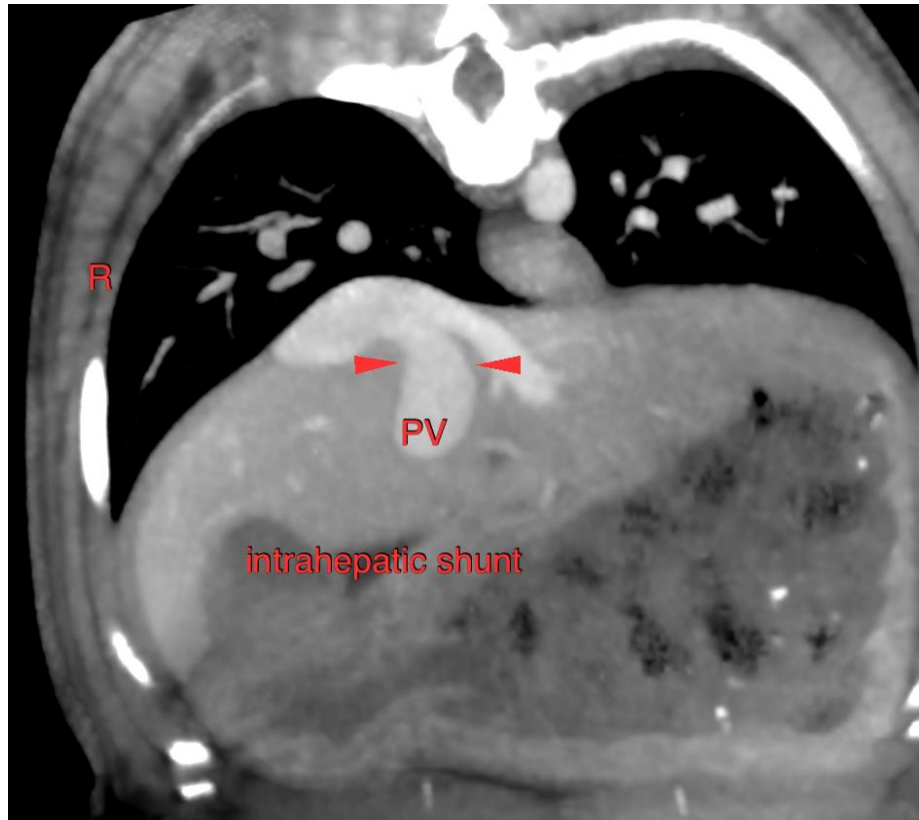
Meaux

INVOICE

50993

DATE

3-16-22



The information and recommendations provided are based on the images presented by the referring veterinarian/sonographer. No evaluation can be communicated regarding pathology that was not visible in the image/video clips provided.

Thank you for this referral. If the clinical or image interpretation does not parallel your findings or if I can be of any further assistance please contact me.

Sebastian Schaub, Sebastian Schaub, DVM, Dr. med. vet. DipECVDI
sebast.schaub@gmail.com