



## PATIENT

Toby Rodriguez

## SPECIES

Canine

## BREED

Pekingese Mix

## SEX

MN

## AGE

14Y

## WEIGHT

19lbs

## INTERPRETED BY

Sebastian Schaub, DVM  
Dr. med. vet.  
DipECVDI

## IMAGING PERFORMED BY

JR/JA

## HOSPITAL NAME

The Pet Hospital of  
Stratford

## REFERRING VET

Dr. Giuliani

## INVOICE

74215

## DATE

3-16-26

## PRESENTING CLINICAL SIGNS

- Toby has been limping for few weeks on left hind, unable to put weight since last night. On exam there is Left hind limb lameness with toe touching. Muscle atrophy and positive drawer sign. Per o p has had historical bladder stones.

Abnormal PE/Chem/CBC/UA Results: Pending CBC/CHEM/UA results

## RADIOGRAPHIC STUDY OF THE STIFLE JOINTS

Radiographs of the stifle joints in two orthogonal image planes are provided for review.

## RADIOGRAPHIC FINDINGS

The periarticular bones of both stifle joints present moderate osteophyte new bone formation, R>L. Both stifle joints present a mild increased intracapsular soft tissue shadow. Sloping of the caudal aspect of the tibial plateau is appreciated.

In the craniocaudal view of the hind limbs, multiple gas opacities are superimposed on the proximolateral aspect of the right thigh musculature – fitting the history of preceding vaccination.

In the pictured parts of the abdomen, an innumerable amount of well-defined, roundish mineral opaque calculi are superimposed on the urinary bladder.

## RADIOGRAPHIC DIAGNOSIS

- Osteoarthritis stifle joint bilaterally
- Mild articular swelling both stifle joints
- Cystolithiasis without mechanical obstruction

## INTERPRETATION OF THE FINDINGS & FURTHER RECOMMENDATIONS

The most common underlying cause for the degenerative joint disease and mild effusion of the stifle joints is pathology of the cranial cruciate ligament ± meniscal pathology. The positive drawer sign or tibial compression test is supporting the diagnosis – partial rupture of the cranial cruciate ligament and potential thickening of the synovial capsule can result in only mild instability.



## PATIENT

Toby Rodriguez

## SPECIES

Canine

## BREED

Pekingese Mix

## SEX

MN

## AGE

14Y

## WEIGHT

19lbs

## INTERPRETED BY

Sebastian Schaub, DVM  
Dr. med. vet.  
DipECVDI

## IMAGING PERFORMED BY

JR/JA

## HOSPITAL NAME

The Pet Hospital of  
Stratford

## REFERRING VET

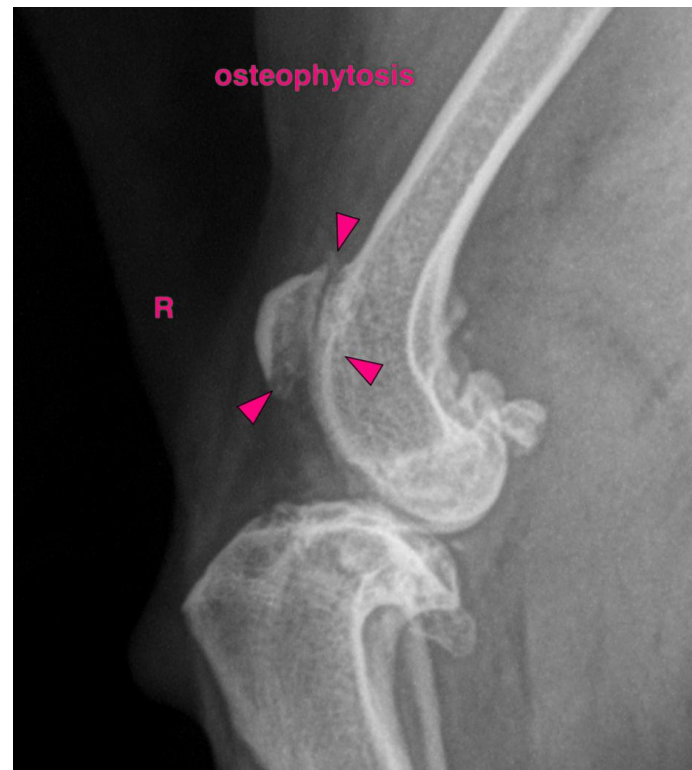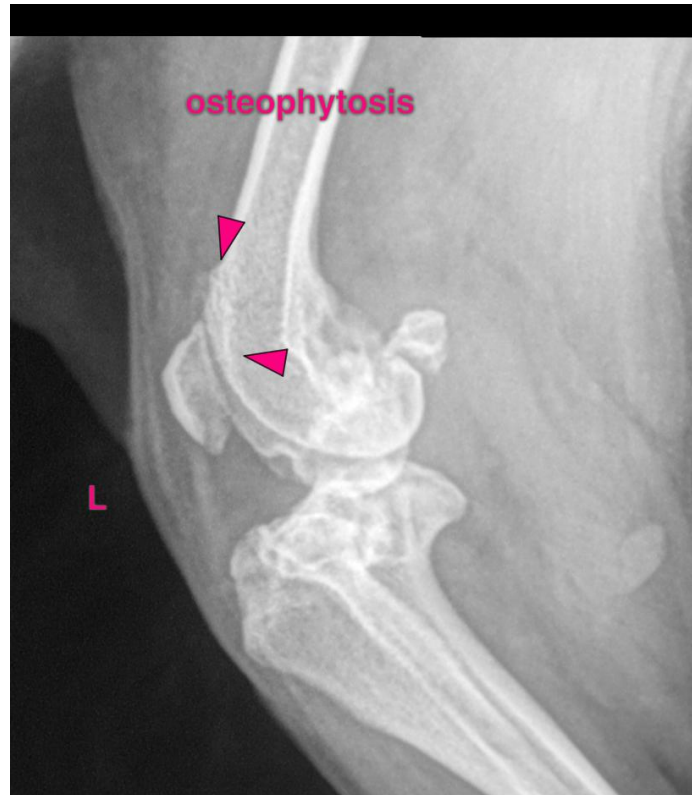
Dr. Giuliani

## INVOICE

74215

## DATE

3-16-26





## PATIENT

Toby Rodriguez

## SPECIES

Canine

## BREED

Pekingese Mix

## SEX

MN

## AGE

14Y

## WEIGHT

19lbs

## INTERPRETED BY

Sebastian Schaub, DVM  
Dr. med. vet.  
DipECVDI

## IMAGING PERFORMED BY

JR/JA

## HOSPITAL NAME

The Pet Hospital of  
Stratford

## REFERRING VET

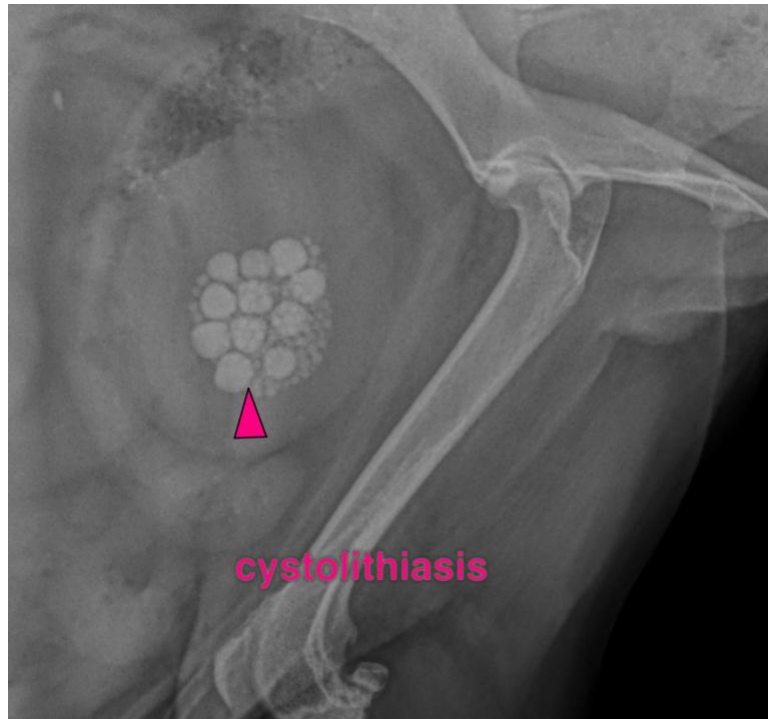
Dr. Giuliani

## INVOICE

74215

## DATE

3-16-26



The information and recommendations provided are based on the images presented by the referring veterinarian/sonographer. No evaluation can be communicated regarding pathology that was not visible in the image/video clips provided.

Thank you for this referral. If the clinical or image interpretation does not parallel your findings or if I can be of any further assistance please contact me.

**Sebastian Schaub**, Sebastian Schaub, DVM, Dr. med. vet. DipECVDI  
[info@sonopath.com](mailto:info@sonopath.com)