



PATIENT

Champ Asencio

SPECIES

Canine

BREED

French Bulldog

SEX

MI

AGE

4

WEIGHT

10.9

INTERPRETED BY

Sebastian Schaub, DVM
Dr. med. vet.
DipECVDI

IMAGING PERFORMED BY

David

HOSPITAL NAME

Animal Surgical Center
- Oceanside

REFERRING VET

Kam

INVOICE

74206

DATE

3-16-26

PRESENTING CLINICAL SIGNS

- paraplegia, CP deficits on both hind limbs, negative motor function and deep pain on both hind limbs, absent patella reflex and withdrawal test on both hind limbs, thoracic limbs positive deep pain and motor function, both weak on both sides, no CP deficits, head tremor,
- urinary incontinences, dribbling urine, bladder overflow, severe irritation of the scrotum due to the urinary incontinence,
- CNs intact.
- non ambulatory on all four limbs, was able to walk on his thoracic limbs, but not volenriarly

COMPUTED TOMOGRAPHY OF THE THORACIC AND LUMBAR SPINE

A high resolution plain and myelographic CT study of the thoracic and lumbar spine is provided for review.

COMPUTED TOMOGRAPHIC FINDINGS

THE LAST RIB BEARING VERTEBRA IS COUNTED AS T13.

The intervertebral disc space T13/L1 is mildly narrowed, and the respective intervertebral disc presents moderate central mineralization. Level with the intervertebral disc space T13/L1, mild hyperattenuating material is appreciated in the left lateral aspect of the vertebral canal, occupying approximately up to 20% of the cross-sectional area of the vertebral canal at the same level. The mild hyperattenuating material T13/L1 is extending cranially up to the level of the cranial vertebral endplate T13 and caudally up to the level of the caudal third of the vertebral body L1. The dural tube level T13/L1 is deviated to the right and distorted.

Level with the intervertebral disc space L5/L6 AND L7/S1, disc material is protruding into the vertebral canal, occupying approximately up to 15% (L5/L6)/60% (L7/S1) of the cross-sectional area of the vertebral canal at the same level.

Multiple intervertebral discs along the lumbar spine present mild central mineralization.

After intrathecal contrast administration, the contrast media is dissecting along the epidural space – resulting in a heterogeneous/irregular contrast column. The contrast column stops approximately level L1/L2.

COMPUTED TOMOGRAPHIC DIAGNOSIS

- Left sided intervertebral disc extrusion T13/L1 with compressive myelopathy
- Intervertebral disc protrusion L5/L6 and L7/S1 with possible dynamic myelocompression
- Multifocal chondroid disc degeneration

INTERPRETATION OF THE FINDINGS & FURTHER RECOMMENDATIONS

The intervertebral disc extrusion T13/L1 is a plausible explanation for the presenting clinical signs – although the volume of the material appears only small it may be underestimated by CT or presents predominantly blood. Anyway surgical decompression ± durotomy appears beneficial.



PATIENT

Champ Asencio

SPECIES

Canine

BREED

French Bulldog

SEX

MI

AGE

4

WEIGHT

10.9

INTERPRETED BY

Sebastian Schaub, DVM
Dr. med. vet.
DipECVDI

IMAGING PERFORMED BY

David

HOSPITAL NAME

Animal Surgical Center
- Oceanside

REFERRING VET

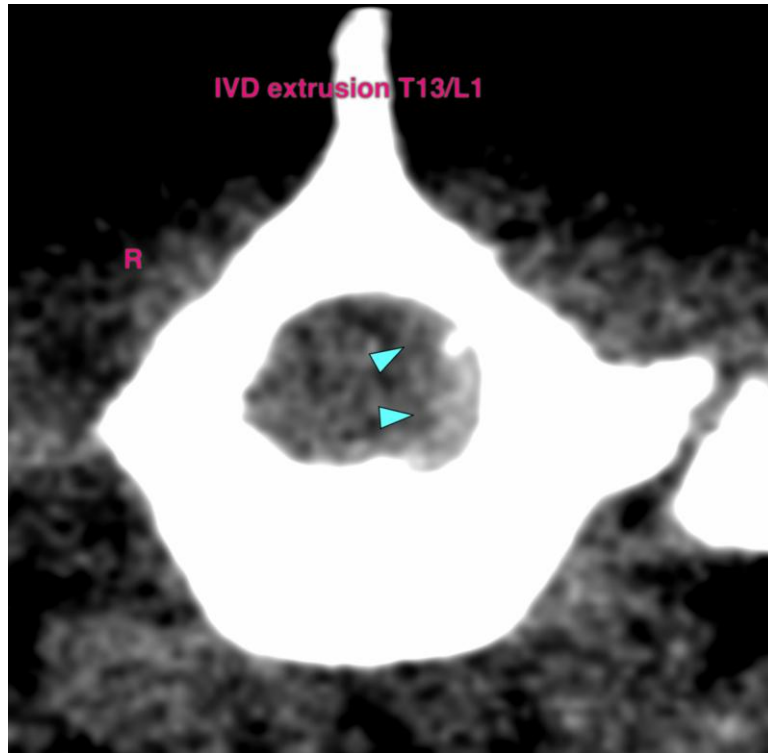
Kam

INVOICE

74206

DATE

3-16-26



The information and recommendations provided are based on the images presented by the referring veterinarian/sonographer. No evaluation can be communicated regarding pathology that was not visible in the image/video clips provided.

Thank you for this referral. If the clinical or image interpretation does not parallel your findings or if I can be of any further assistance please contact me.

Sebastian Schaub, Sebastian Schaub, DVM, Dr. med. vet. DipECVDI
info@sonopath.com