



PATIENT PRESENTING CLINICAL SIGNS

Leo Kellams Follow Up/Recheck of Known murmur and HCOM diagnosis. Increase in coughing recently. Had x-rays sent 2 years ago invoice 43974. Submitting recheck blood work as well. Will consult with cardiologist again soon.

SPECIES RADIOGRAPHIC STUDY OF THE THORAX

Feline Radiographs of the thorax in three imaging planes are provided for review.

RADIOGRAPHIC FINDINGS

BREED The body condition score is 8/9.

Tabby The surrounding bony structures are within normal limits.

The extrathoracic soft tissues present homogeneous without abnormalities.

SEX The cranial mediastinum presents the expected soft tissue opacity. The mediastinal width is less than twice the width of the vertebral column at the same level.

MN

The trachea is normal in diameter and presents the anticipated course. The luminal outline of the trachea is smooth.

AGE

13 Years

Multiple bronchial segments present a mild increased visibility of the bronchial walls.

INTERPRETED BY

The lung parenchyma presents the expected architecture and opacity; the intrapulmonary vascular branching is seen up to the third order lung vessels.

Sebastian Schaub, DVM
Dr. med. vet. DipECVDI

The diaphragm is well delineated with even surface and the expected mild cranial bulging of the diaphragmatic cupola.

RADIOGRAPHIC DIAGNOSIS

HOSPITAL NAME

Gentle Doctor Animal
Hospital

- Stationary bronchial pattern
- Redundant aortic arch
- Obesity

REFERRING VET

Dr. Thomassen

INTERPRETATION OF THE FINDINGS & FURTHER RECOMMENDATIONS

The bronchial pattern in combination with the history is consistent with feline bronchial disease – commonly primary allergic in origin.

The cardiovascular structures present without clinically relevant radiographic changes; the redundant aortic arch is an age related entity.

INVOICE

57282

DATE

3-16-23



PATIENT

Leo Kellams

SPECIES

Feline

BREED

Tabby

SEX

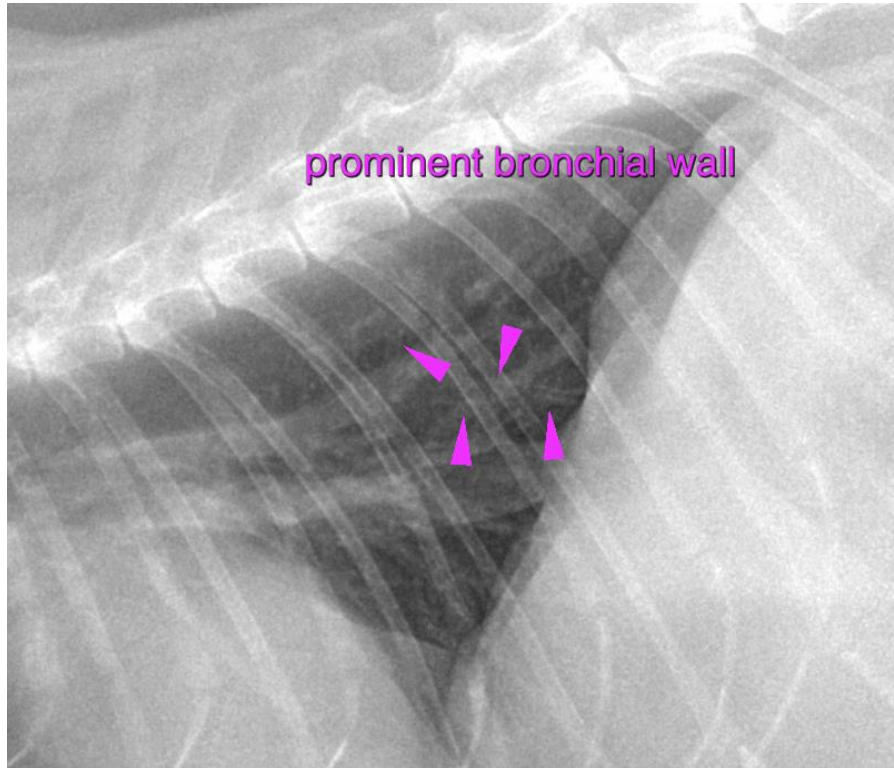
MN

AGE

13 Years

INTERPRETED BY

Sebastian Schaub, DVM
Dr. med. vet. DipECVDI



HOSPITAL NAME

Gentle Doctor Animal
Hospital

REFERRING VET

Dr. Thomassen

The information and recommendations provided are based on the images presented by the referring veterinarian/sonographer. No evaluation can be communicated regarding pathology that was not visible in the image/video clips provided.

Thank you for this referral. If the clinical or image interpretation does not parallel your findings or if I can be of any further assistance please contact me.

Sebastian Schaub, Sebastian Schaub, DVM, Dr. med. vet. DipECVDI
sebast.schaub@gmail.com

INVOICE

57282

DATE

3-16-23