



**PATIENT**

Teddy Bear  
O'Conner-Sanchez

**PRESENTING CLINICAL SIGNS**

Patient came in as a walk in with a swelling under neck and mouth. Rannula notice by DVM. CT performed followed by surgery  
Abnormal PE/Chem/CBC/UA Results: PLT 543 PCT 0.53 ALT 328

**SPECIES**

Canine

**COMPUTED TOMOGRAPHY OF THE SKULL**

A high resolution pre- and post-contrast CT study of the skull is provided for review.

**BREED**

Shih Tzu Mix

**COMPUTED TOMOGRAPHIC FINDINGS**

Machine settings of patient positioning are flipped – settings are with patient in prone position, but it is in supine position and right and left are flipped; R is indicating actually the left side of the patient and vice versa.

**SEX**

MN

The tooth elements 101, 108, 201, 206, 301-303, 305, 311, 401, 402, 405 and 411 are absent. A supernumerary triadan 105 is present.

**AGE**

9 Years

Alongside the right ventrolateral aspect of the tongue, a well-defined, peripheral contrast enhancing and central fluid attenuating tubular mass is seen, protruding into the oral cavity. The tubular mass is measuring 4.0 x 2.4 x 7.4 cm in size. In the caudal aspect the tubular mass is extending up to the level of the right mandibular salivary gland.

**INTERPRETED BY**

Sebastian Schaub, DVM  
Dr. med. vet. DipECVDI

The nasal cavity presents the expected aerated spaces between thin & even conchae and turbinates with smooth mucosal lining.

Both temporomandibular joints present congruent joint spaces with even subchondral bone surfaces and are considered within normal limits.

**HOSPITAL NAME**

Petroglyph Animal  
Hospital

Both tympanic bullae are aerated, the mucosal lining is not seen, the bony wall is smooth and thin. The external ear canals are within normal limits.

The brain presents no deviation from normal anatomy and symmetry. The brain parenchyma is homogeneous and within normal limits for attenuation and distribution of contrast enhancement. The ventricular system is non-dilated and symmetric.

**REFERRING VET**

Dr. Raymond Hudgell

The submandibular and medial retropharyngeal lymph nodes are small and elongated with a normal short-to-long-axis-ratio is < 0.5, the attenuation and contrast enhancement pattern is uniform.

**INVOICE**

50987

The intervertebral disc C6/C7 is mildly protruding into the vertebral canal, distorting the ventral epidural space at the same level.

**DATE**

3-16-22

**COMPUTED TOMOGRAPHIC DIAGNOSIS**

- Right sided sublingual mucocele
- Multiple absent teeth, see above
- Supernumerary triadan 105
- Mild intervertebral disc protrusion C6/C7 without compressive myelopathy



**PATIENT**

Teddy Bear  
O'Conner-Sanchez

**INTERPRETATION OF THE FINDINGS & FURTHER RECOMMENDATIONS**

The CT study is consistent with the history of sublingual mucocele, and surgical management has already been performed, regarding the history. No additional clinically relevant pathology is appreciated.

**SPECIES**

Canine

**BREED**

Shih Tzu Mix

**SEX**

MN

**AGE**

9 Years

**INTERPRETED BY**

Sebastian Schaub, DVM  
Dr. med. vet. DipECVDI

**HOSPITAL NAME**

Petroglyph Animal  
Hospital

**REFERRING VET**

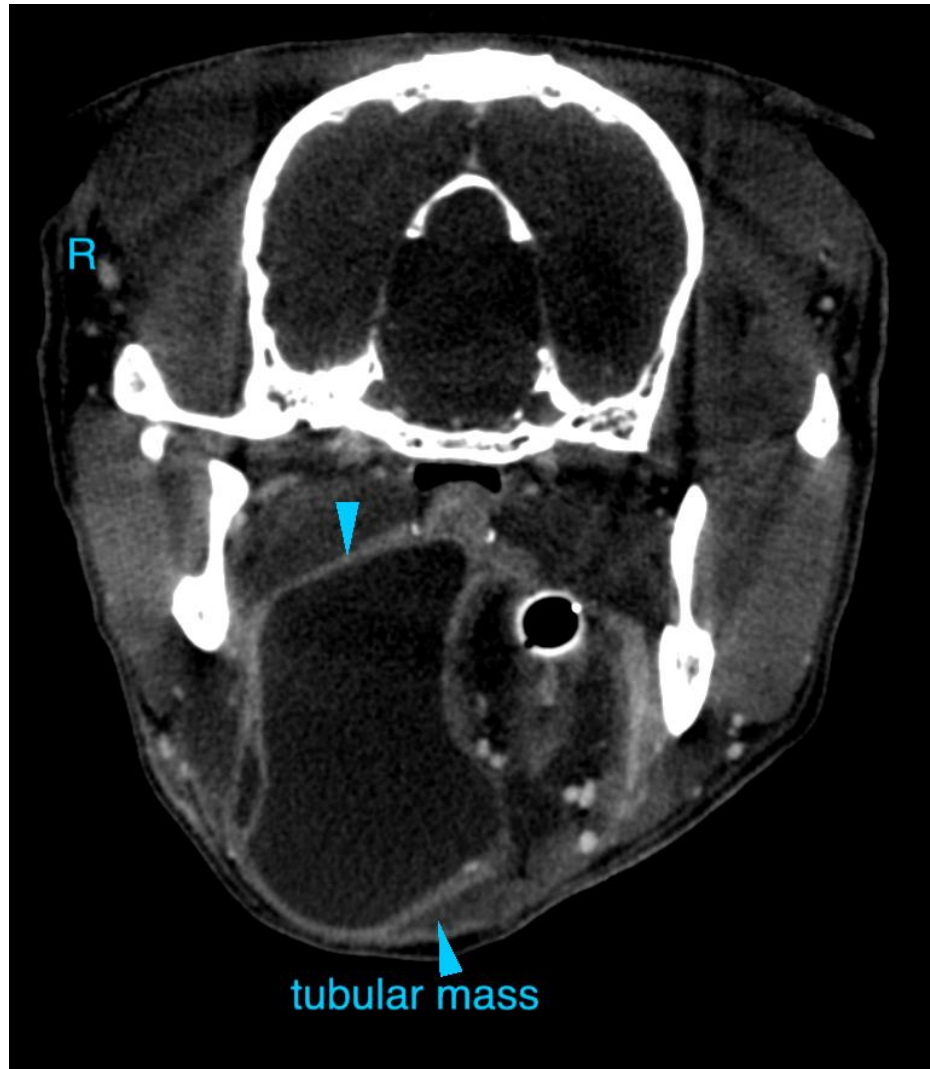
Dr. Raymond Hudgell

**INVOICE**

50987

**DATE**

3-16-22





**PATIENT**

Teddy Bear  
O'Conner-Sanchez

**SPECIES**

Canine

**BREED**

Shih Tzu Mix

**SEX**

MN

**AGE**

9 Years

**INTERPRETED BY**

Sebastian Schaub, DVM  
Dr. med. vet. DipECVDI

**HOSPITAL NAME**

Petroglyph Animal  
Hospital

**REFERRING VET**

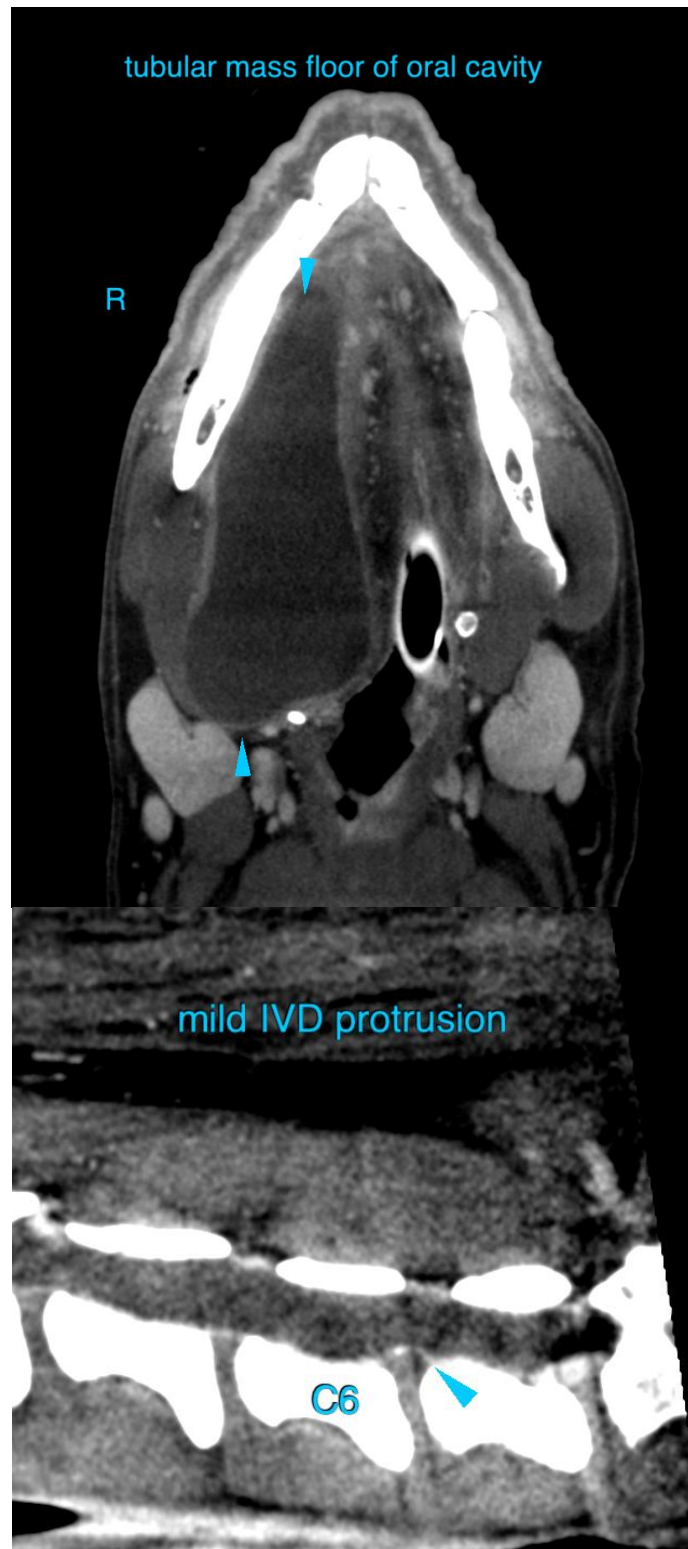Dr. Raymond Hudgell

**INVOICE**

50987

**DATE**

3-16-22





**PATIENT**

Teddy Bear  
O'Conner-Sanchez

**SPECIES**

Canine

The information and recommendations provided are based on the images presented by the referring veterinarian/sonographer. No evaluation can be communicated regarding pathology that was not visible in the image/video clips provided.

**BREED**

Shih Tzu Mix

Thank you for this referral. If the clinical or image interpretation does not parallel your findings or if I can be of any further assistance please contact me.

**Sebastian Schaub**, Sebastian Schaub, DVM, Dr. med. vet. DipECVDI  
sebast.schaub@gmail.com

**SEX**

MN

**AGE**

9 Years

**INTERPRETED BY**

Sebastian Schaub, DVM  
Dr. med. vet. DipECVDI

**HOSPITAL NAME**

Petroglyph Animal  
Hospital

**REFERRING VET**

Dr. Raymond Hudgell

**INVOICE**

50987

**DATE**

3-16-22