



PATIENT

Rocco Chambers

PRESENTING CLINICAL SIGNS

Limping on the Right Hind Limb. Otherwise, no concerns.
Abnormal PE/Chem/CBC/UA Results: Non-weight bear on RHL. Positive Drawer's test of RHL under sedation.

SPECIES

Canine

RADIOGRAPHIC STUDY OF THE STIFLE JOINTS

Radiographs of both stifle joints in two imaging planes are provided for review.

BREED

Staffordshire Terrier

RADIOGRAPHIC FINDINGS

The growth plates are age related open.

SEX

Male

Most accentuated in the tibial diaphysis – R>L – and in the region of the nutritional foramen of the femora bilaterally, fingerprint like zones of sclerosis are visible.

The osseous margins of both stifle joints are smooth and there are no signs for pathological intracapsular swelling of the stifle joints.

AGE

5 Months

RADIOGRAPHIC DIAGNOSIS

- Myelosclerosis diaphysis of the femora & tibiae
- Normal stifle joints

INTERPRETED BY

Sebastian Schaub, DVM
Dr. med. vet. DipECVDI

INTERPRETATION OF THE FINDINGS & FURTHER RECOMMENDATIONS

The findings are compatible with panosteitis, a plausible source for the described clinical signs. Check if pain can be elicited by pressure on the diaphysis of the long bones of the hind limbs.

HOSPITAL NAME

Truscott Animal
Hospital

No abnormalities of the stifle joints are appreciated, and the synovial soft tissue volume is considered normal for the age of the patient. Be aware that in young patients there is an increased laxity, possibly mimicking cranial cruciate ligament.

I would recommend a clinical trial with dietary changes and NSAID and re-evaluating the patient in 3-4 weeks.

REFERRING VET

Medhat Meawad

INVOICE

50992

DATE

3-16-22



PATIENT

Rocco Chambers

SPECIES

Canine

BREED

Staffordshire Terrier

SEX

Male

AGE

5 Months

INTERPRETED BY

Sebastian Schaub, DVM
Dr. med. vet. DipECVDI

HOSPITAL NAME

Truscott Animal
Hospital

REFERRING VET

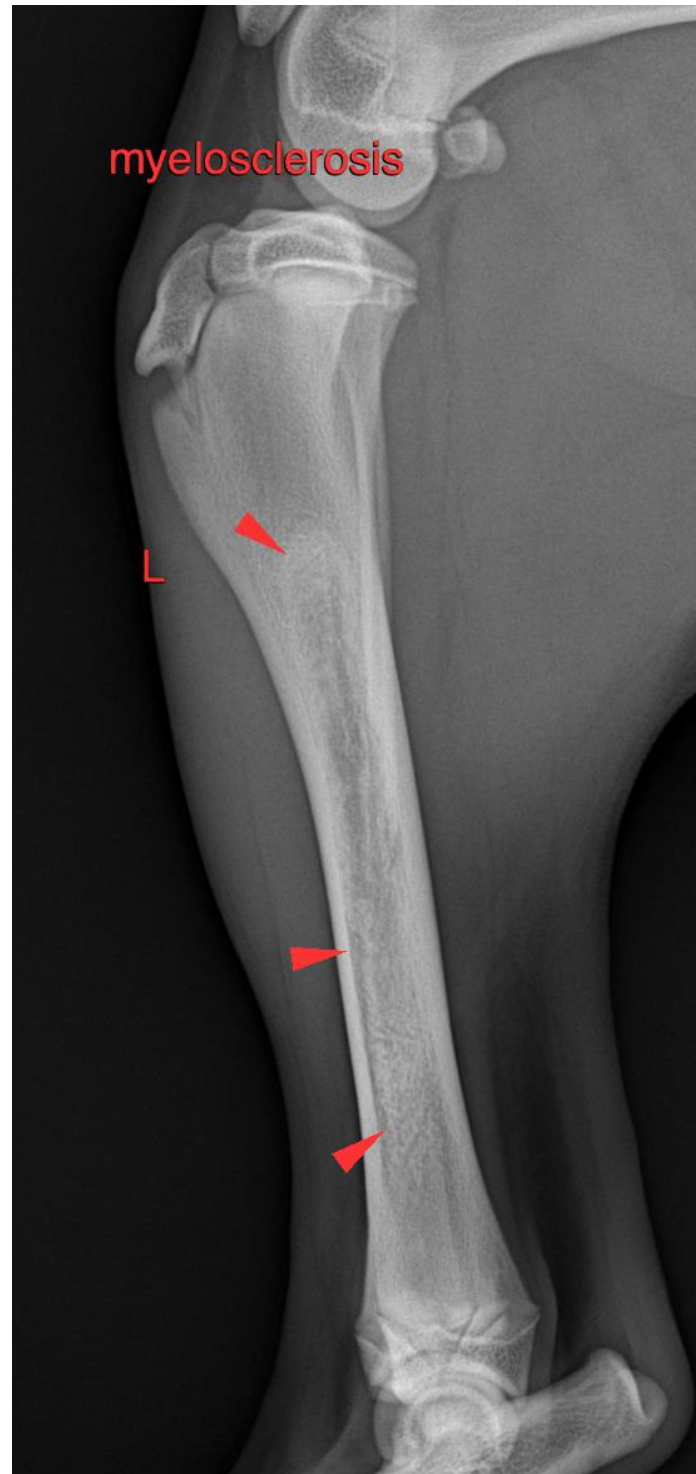Medhat Meawad

INVOICE

50992

DATE

3-16-22





PATIENT

Rocco Chambers

SPECIES

Canine

BREED

Staffordshire Terrier

SEX

Male

AGE

5 Months

INTERPRETED BY

Sebastian Schaub, DVM
Dr. med. vet. DipECVDI

HOSPITAL NAME

Truscott Animal
Hospital

REFERRING VET

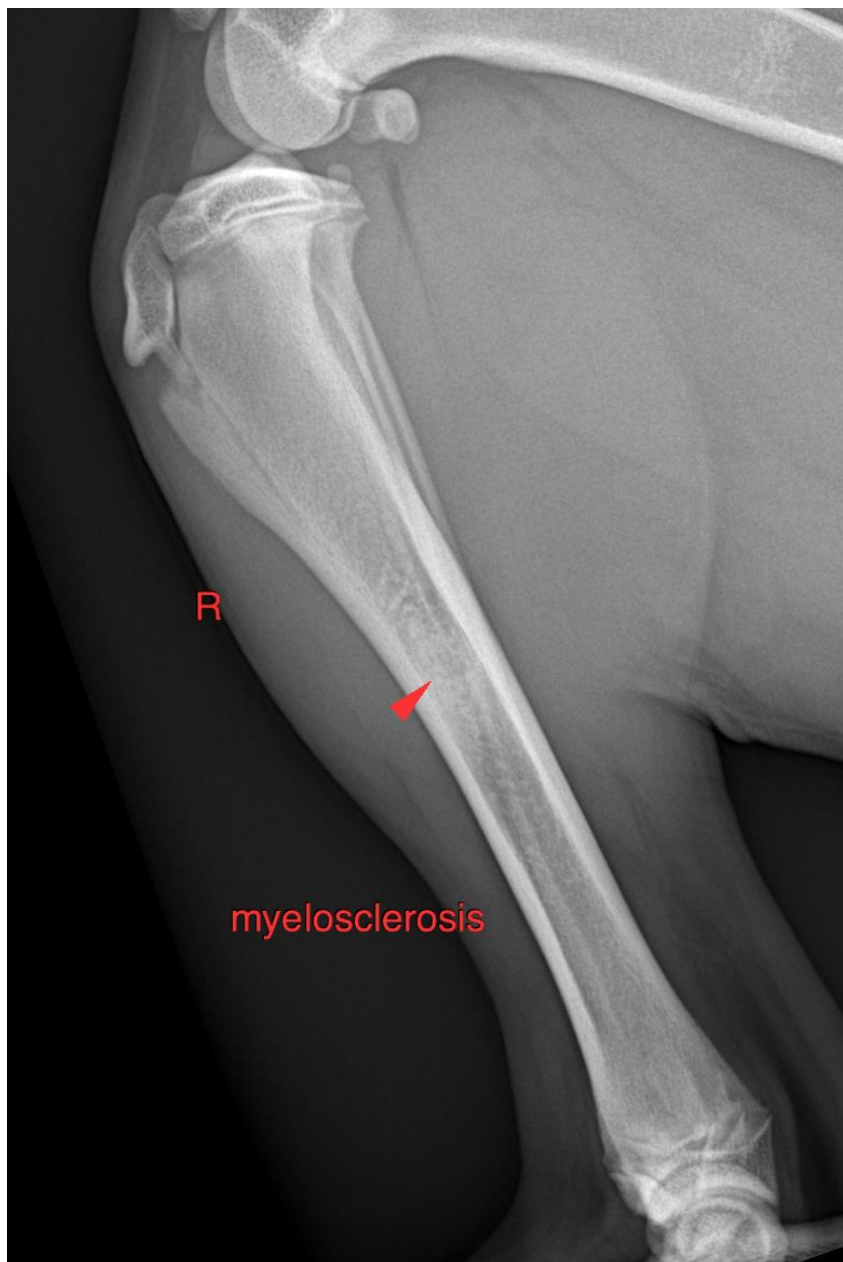
Medhat Meawad

INVOICE

50992

DATE

3-16-22





PATIENT

Rocco Chambers

SPECIES

Canine

BREED

Staffordshire Terrier

SEX

Male

AGE

5 Months

INTERPRETED BY

Sebastian Schaub, DVM
Dr. med. vet. DipECVDI

HOSPITAL NAME

Truscott Animal
Hospital

REFERRING VET

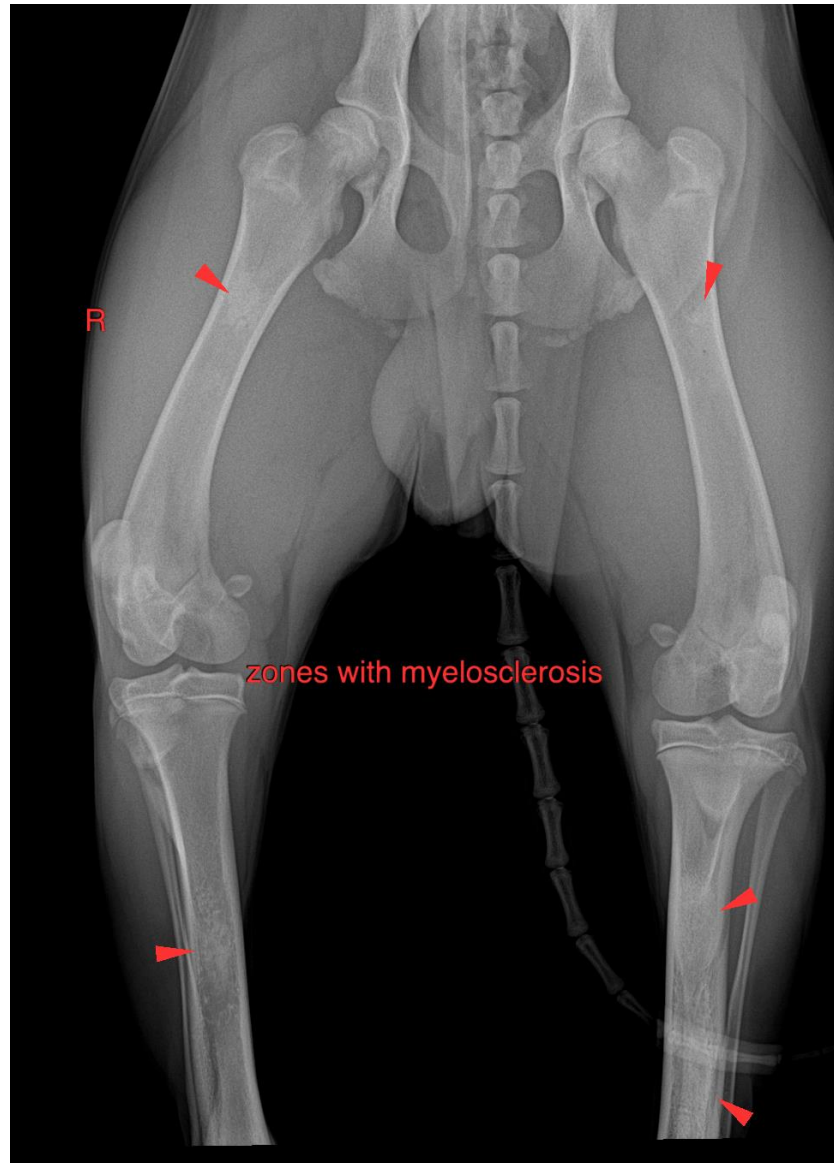
Medhat Meawad

INVOICE

50992

DATE

3-16-22



The information and recommendations provided are based on the images presented by the referring veterinarian/sonographer. No evaluation can be communicated regarding pathology that was not visible in the image/video clips provided.

Thank you for this referral. If the clinical or image interpretation does not parallel your findings or if I can be of any further assistance please contact me.

Sebastian Schaub, Sebastian Schaub, DVM, Dr. med. vet. DipECVDI
sebast.schaub@gmail.com