



PATIENT

Pepper Mohiti

PRESENTING CLINICAL SIGNS

Pepper, a 11 month old Female Miniature Schnauzer, was presented to the Toronto Animal Health Partners Surgery Service for evaluation of a left scapular fracture. Pepper fell off the couch on March 3rd, 022 and injured herself. Radiographs revealed left scapular fracture and Pepper was referred to AHP for CT. Pepper is painful and yelps when running. Pepper has had a previous history of otherwise being a healthy dog. She has been well rested at home (crate) except when outside to eliminate.
Abnormal PE/Chem/CBC/UA Results:

SPECIES

Canine

BREED

Miniature Schnauzer

COMPUTED TOMOGRAPHY OF THE FRONT LIMBS

A plain CT study of the front limbs in a bone and soft tissue reconstruction is provided for review.

SEX

F

COMPUTED TOMOGRAPHIC FINDINGS

The left scapula presents with a longitudinal fracture of the infraspinatus fossa with the fracture line running in a proximo-distal direction with a thin fissure line in the distal third of the infraspinatus fossa extending to the caudal scapular margin. A transverse fissure line is seen running from the cranial to caudal margin of the mid third of the left scapula with mild medial deviation of the distal segment of the scapula.

AGE

11 Months

The shoulder joints present smooth osseous margins and without abnormalities of the surrounding soft tissue structures.

INTERPRETED BY

Sebastian Schaub, DVM
Dr. med. vet. DipECVDI

Both elbow joints present smooth osseous margins; the medial coronoid process is well-defined and presents a homogeneous density.

COMPUTED TOMOGRAPHIC DIAGNOSIS

HOSPITAL NAME

Animal Health Partners

- Subacute traumatic extra-articular transverse fracture of the mid segment of the scapula with mild medial deviation and longitudinal fracture of the infraspinatus fossa

INTERPRETATION OF THE FINDINGS & FURTHER RECOMMENDATIONS

REFERRING VET

Lea Mehrkens

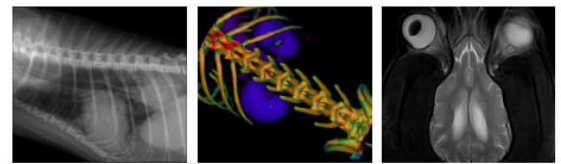
The findings are consistent with the history of left sided scapular fracture, there is only very mild displacement of the fracture and conservative management is considered as the therapy of choice.

INVOICE

50972

DATE

3-16-22



PATIENT

Pepper Mohiti

SPECIES

Canine

BREED

Miniature Schnauzer

SEX

F

AGE

11 Months

INTERPRETED BY

Sebastian Schaub, DVM
Dr. med. vet. DipECVDI

HOSPITAL NAME

Animal Health
Partners

REFERRING VET

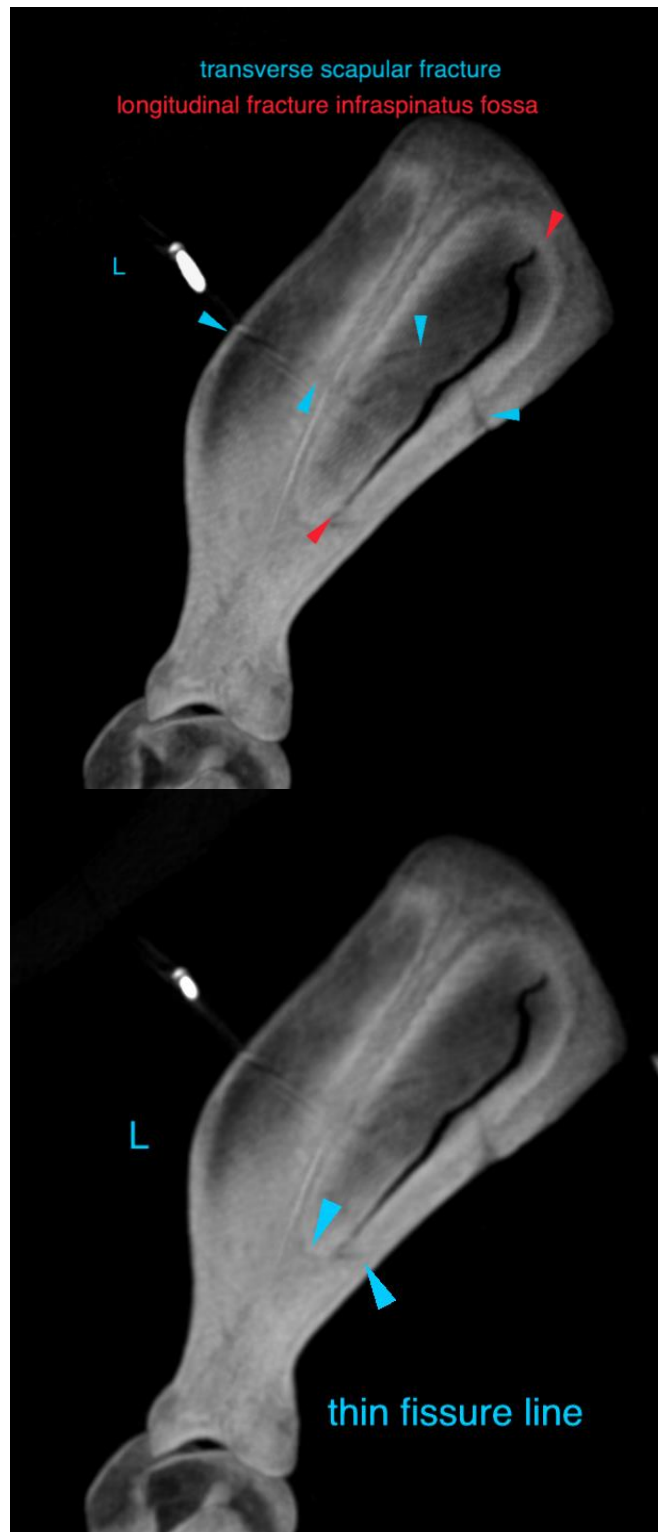
Lea Mehrkens

INVOICE

50972

DATE

3-16-22





PATIENT

Pepper Mohiti

SPECIES

Canine

BREED

Miniature Schnauzer

SEX

F

AGE

11 Months

INTERPRETED BY

Sebastian Schaub, DVM
Dr. med. vet. DipECVDI

HOSPITAL NAME

Animal Health
Partners

REFERRING VET

Lea Mehrkens

INVOICE

50972

DATE

3-16-22

The information and recommendations provided are based on the images presented by the referring veterinarian/sonographer. No evaluation can be communicated regarding pathology that was not visible in the image/video clips provided.

Thank you for this referral. If the clinical or image interpretation does not parallel your findings or if I can be of any further assistance please contact me.

Sebastian Schaub, Sebastian Schaub, DVM, Dr. med. vet. DipECVDI
sebast.schaub@gmail.com