



PATIENT

Mick Schoenfeld

PRESENTING CLINICAL SIGNS

Mick presented with a lifelong history of an angular limb deformity in the forelimbs and progressive lameness, left worse than right. The owner has had him for about 1 year. Mick is unable to exercise after a certain amount of time. Corrective osteotomies are recommended and concurrent arthrodesis should be considered per the orthopedic specialist. Previous diagnosis: None Purpose of CT scan: Planning for surgical correction. Location of CT scan: Front limbs, shoulders Limping: Yes Therapies tried and response: None Current medication: None Current signs: Forelimb lameness Appetite and activity level: Great appetite, decreased activity level due to discomfort.

SPECIES

Canine

BREED

Brittany Spaniel Mix

Abnormal PE/Chem/CBC/UA Results: PE: ****Musculoskeletal:**** Abnormal: Carpus varus; elbows bow out and front feet point inward Lab: Blood work is dated 3/14/22. CBC - PCV = 52%, WBC = 10300, neutrophils = 6901, lymphocytes = 2472, monocytes = 412. Platelets = 241,000. Mini Chemistry - normal. Urinalysis - not provided.

SEX

CM

COMPUTED TOMOGRAPHY OF THE FRONT LIMBS

A high resolution plain CT study of the front limbs is provided for review.

AGE

4 Years

COMPUTED TOMOGRAPHIC FINDINGS

The osseous and surrounding soft tissue structures of both shoulder & elbow joints are within normal limits. The osseous margins of the periarticular bones of the shoulder and elbow joints are smooth.

INTERPRETED BY

Sebastian Schaub, DVM
Dr. med. vet. DipECVDI

Both carpal joints present a moderate periarticular circumferential soft tissue swelling. The periarticular bones of the antebrachio-carpal joint bilaterally presents moderate osteophyte new bone formation. Both carpal joints present with a varus conformation due to medial and mild caudal axial deviation in the distal fourth of the radius bilaterally is noted. There appears also to be rotational deviation of the axis of the radius with mild supination in the distal aspect.

HOSPITAL NAME

VetMed Consultants

COMPUTED TOMOGRAPHIC DIAGNOSIS

- Carpus varus malformation due to medial and caudal axial deviation in the distal radius bilaterally ± rotational axial deviation
- Moderate degenerative osteoarthritis antebrachio-carpal joint bilaterally
- Moderate intracapsular swelling carpal joints bilaterally

REFERRING VET

Drew Allen

INTERPRETATION OF THE FINDINGS & FURTHER RECOMMENDATIONS

INVOICE

50990

The CT study is consistent with the history of angular limb deformity of the distal antebrachium bilaterally with secondary carpus varus malformation and chronic degenerative changes of the antebrachio-carpal joints, due to abnormal biomechanical load. I would recommend determining CORA point on well positioned orthogonal radiographs of the antebrachium bilaterally. A 3D printout from the CT scan may also help in surgical planning. Due to degenerative remodeling of the antebrachio-carpal joints, any corrective surgery will likely warrant arthrodesis of the carpal joints to reduce the source for the progressive lameness.

DATE

3-16-22



PATIENT

Mick Schoenfeld

SPECIES

Canine

BREED

Brittany Spaniel Mix

SEX

CM

AGE

4 Years

INTERPRETED BY

Sebastian Schaub, DVM
Dr. med. vet. DipECVDI

HOSPITAL NAME

VetMed Consultants

REFERRING VET

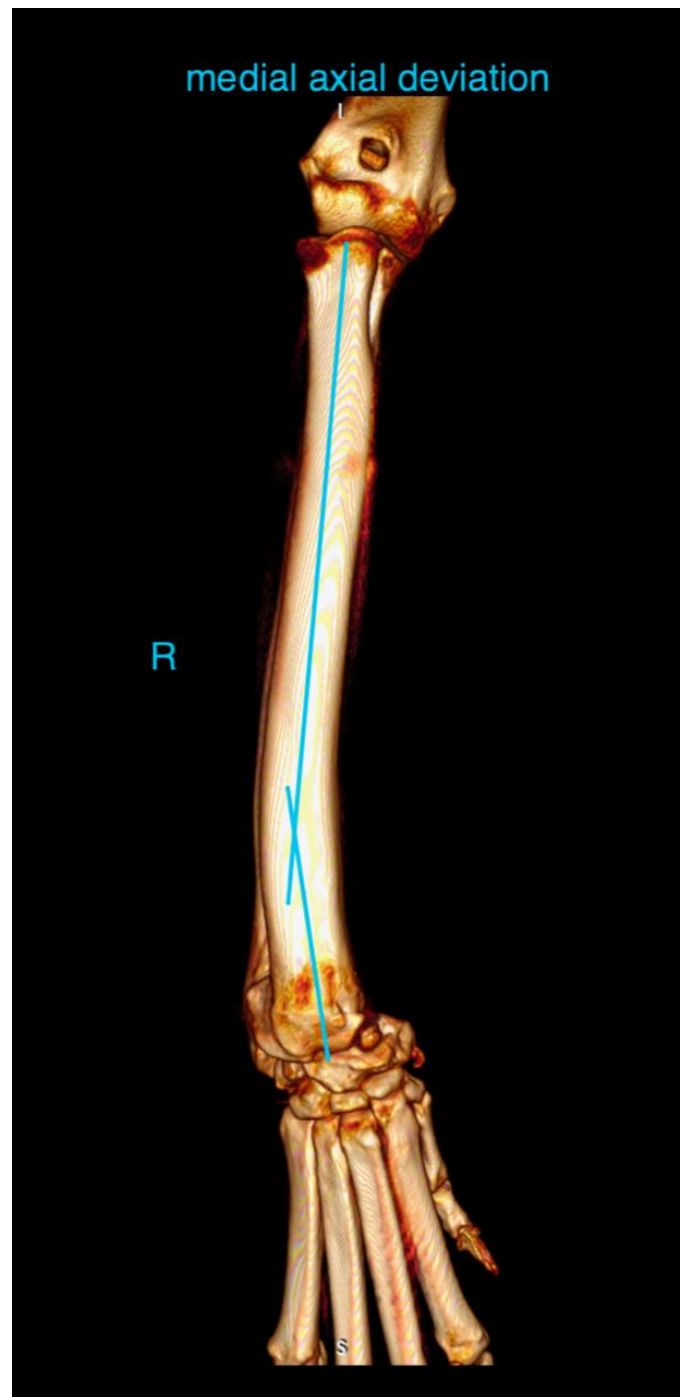
Drew Allen

INVOICE

50990

DATE

3-16-22





PATIENT

Mick Schoenfeld

SPECIES

Canine

BREED

Brittany Spaniel Mix

SEX

CM

AGE

4 Years

INTERPRETED BY

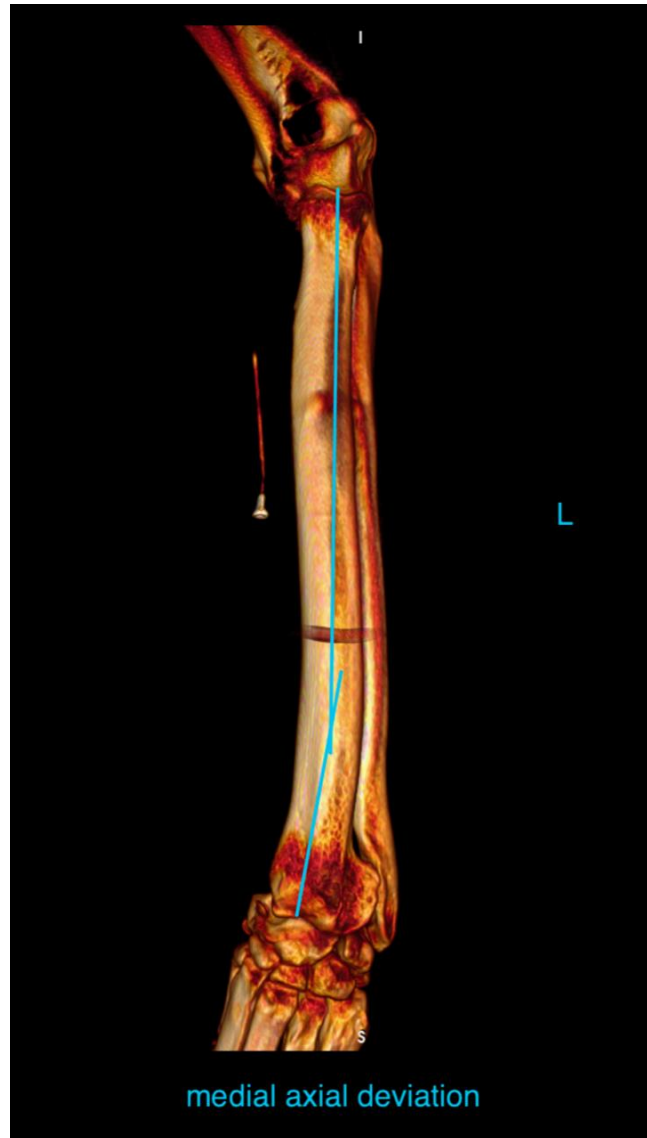Sebastian Schaub, DVM
Dr. med. vet. DipECVDI

HOSPITAL NAME

VetMed Consultants

REFERRING VET

Drew Allen



INVOICE

50990

DATE

3-16-22

The information and recommendations provided are based on the images presented by the referring veterinarian/sonographer. No evaluation can be communicated regarding pathology that was not visible in the image/video clips provided.

Thank you for this referral. If the clinical or image interpretation does not parallel your findings or if I can be of any further assistance please contact me.

Sebastian Schaub, Sebastian Schaub, DVM, Dr. med. vet. DipECVDI
sebast.schaub@gmail.com